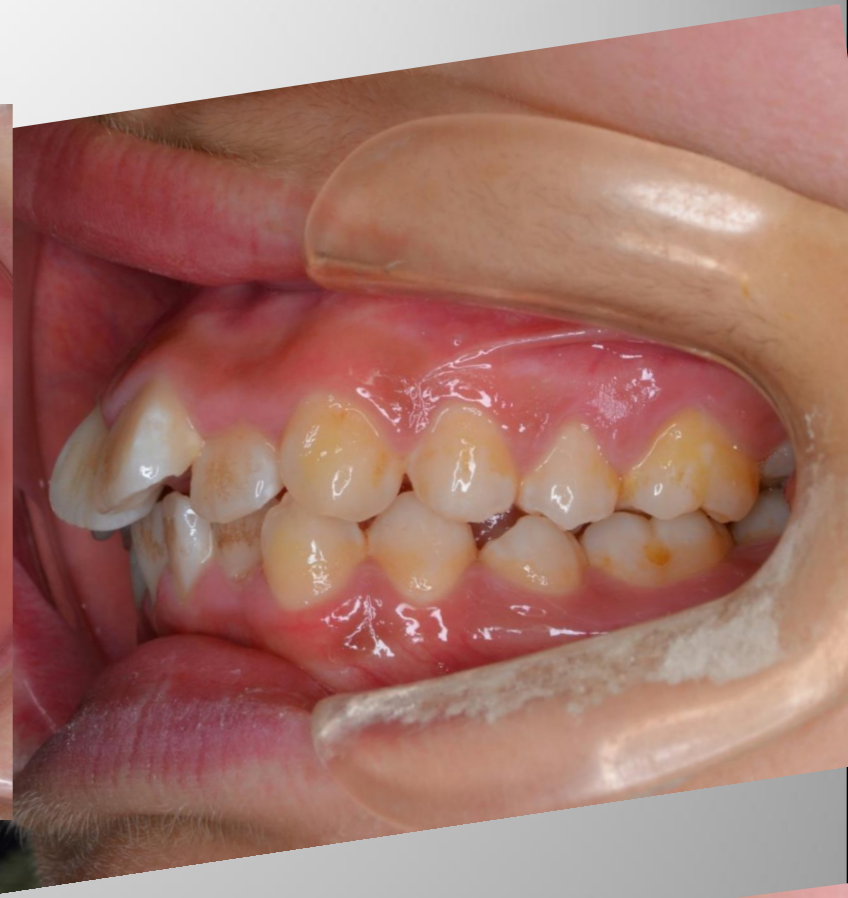
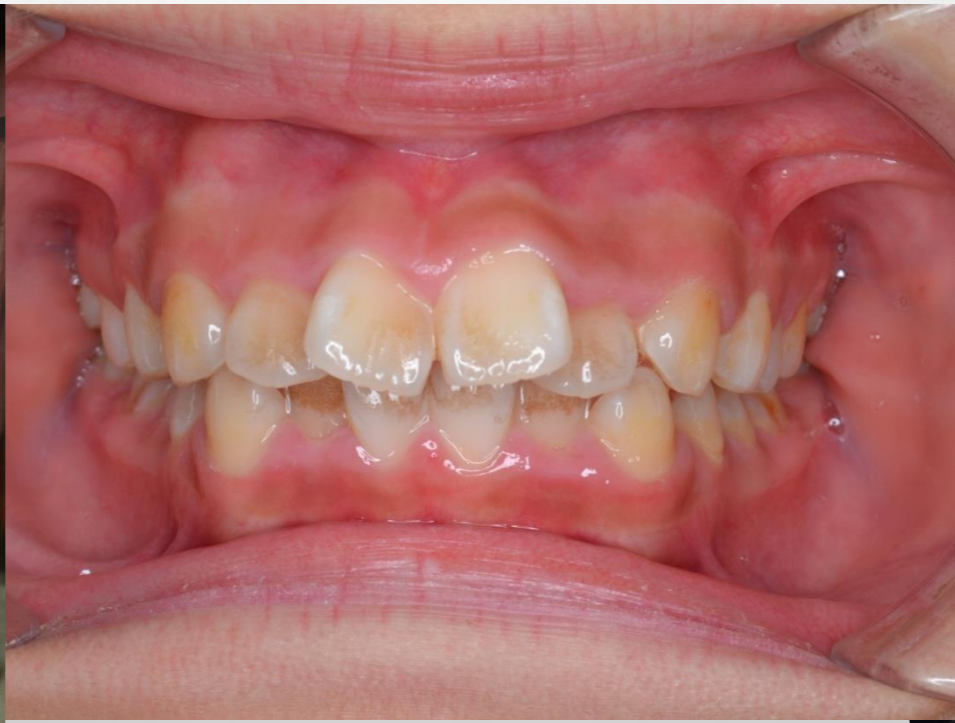
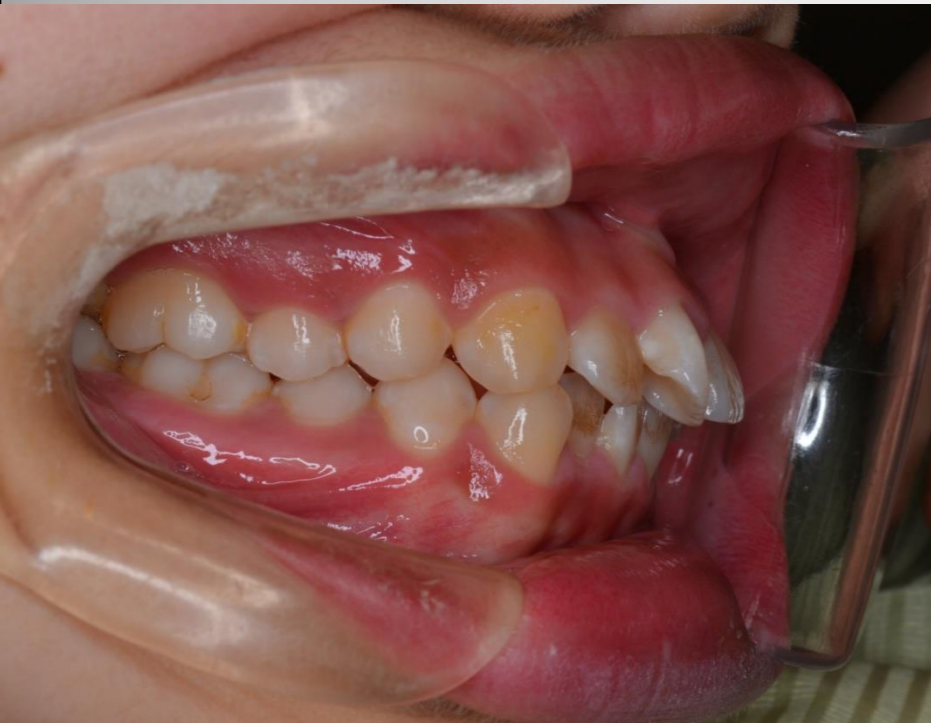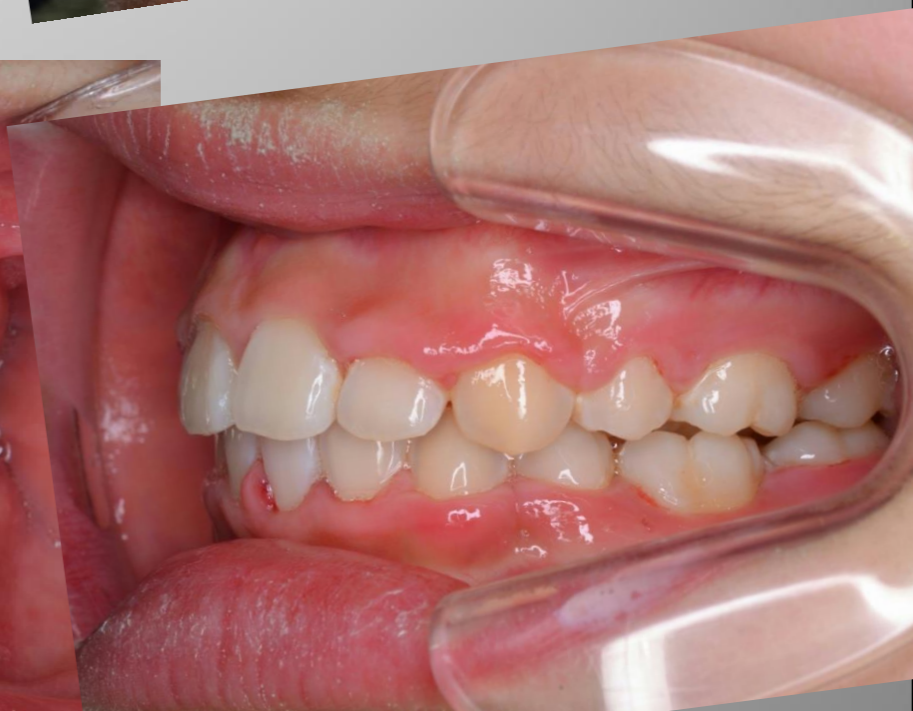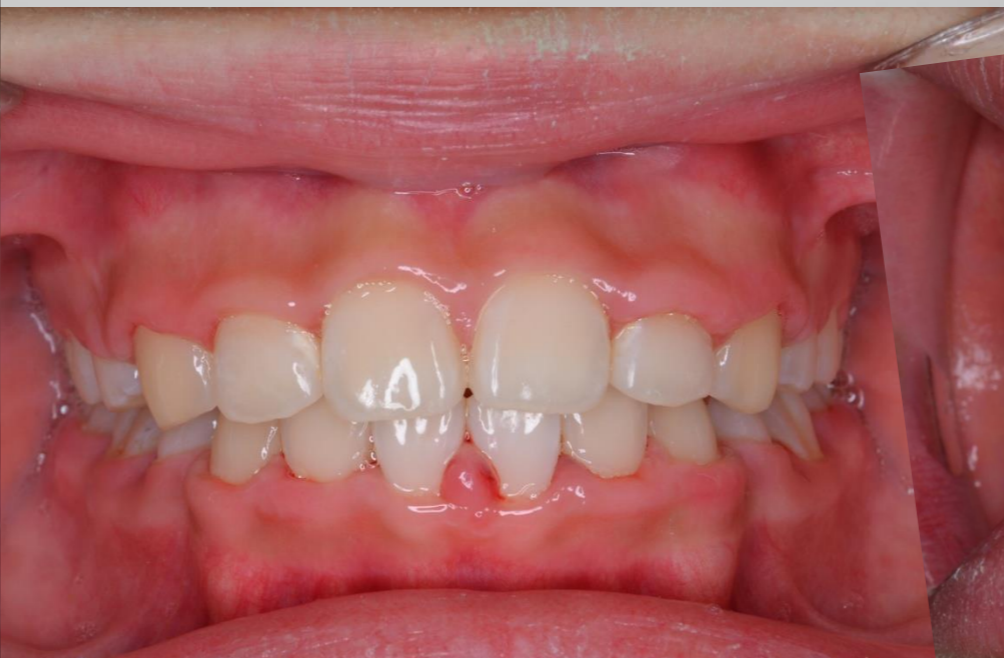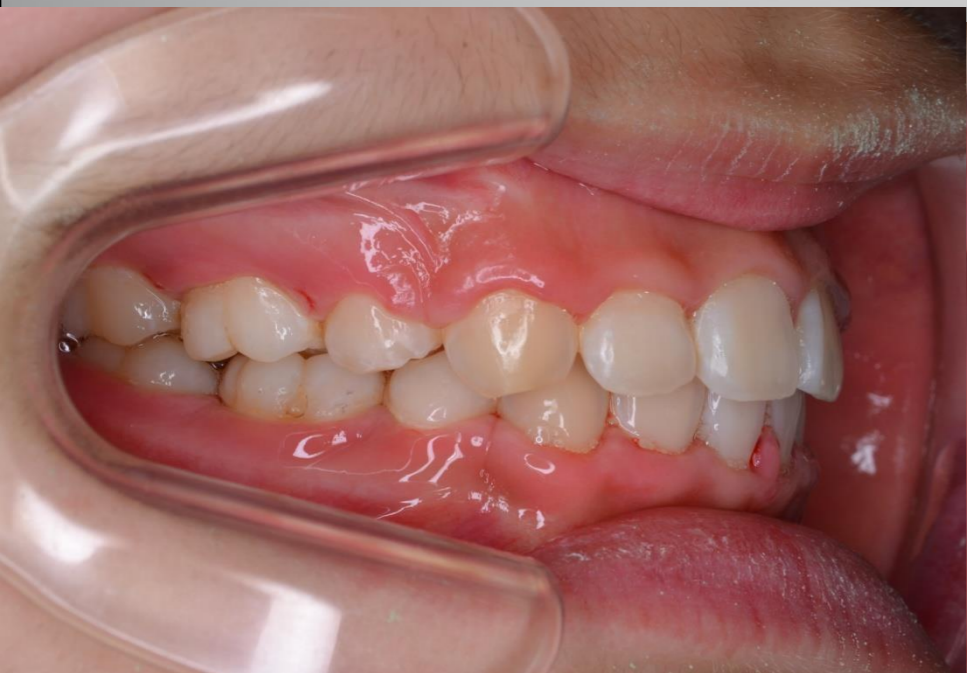ORTHODONTIST'S NAME										CODE :		F				
I = TWEED COURSE INSTRUCTOR, M = TWEED MEMBER, A = APPLICANT FOR MEMMBERSHIP																
DIFFERENTIAL DIAGNOSIS AND CLINICAL ANALYSIS																
PATIENT'S FIRST NAME :					INI		LAST NAME :									
BEGIN TX. AGE		12y2m		SEX		F		BIRTHDAY			February 2		TREATMENT		28 MONTHS	
DATE												READOUT START				
		NORMAL		PRE-TX		PROGRESS		FINAL		POST-TX				7 6 5 5 6 7		
FMIA		67		40.0				46.0				U				
FMA		25		35.0				37.0				L				
IMPA		88		105.0				97.0		180.0				FINISH		
SNA		82		88.1				81.6				U				
SNB		80		79.0				74.5				L				
ANB		2		9.1				7.1		0.0						
AO-BO		2mm		0.0 mm		mm		1.0 mm		mm		DIAGNOSIS:				
OCC PLANE		10		18.5				24.1				A. Skeletal :		II		
Z ANGLE		75		58.6				50.8								
UPPER LIP				15.0 mm		mm		17.0 mm		mm						
TOTAL CHIN				16.0 mm		mm		17.0 mm		mm		B. Dental :		I		
POST. FACIAL HT.		45mm		45.0 mm		mm		48.0 mm		mm						
ANT. FACIAL HT.		65mm		68.0 mm		mm		70.0 mm		mm						
FAC. HT. INDEX		0.69		-				-		▲		C. Perio :				
FAC. HT. CHANGE		2:1		-		/		-		/						
MAND. CUSPID WIDTH				28.0 mm		mm		27.5 mm		mm						
MAND. MOLAR WIDTH				29.0 mm		mm		30.0 mm		mm		D. Facial :				
CRANIAL FACIAL ANALYSIS																
		Ceph.		Difficulty								E. Habits :				
Normal Range		Value		Factor		Difficulty						1. Thumb Sucker				
FMA 22-28		35.0		5		35						2. Tongue Thrust				
ANB 1-5		9.1		15		62						3. Bruxism				
Z-ANGLE 70-80		58.6		2		23										
OCC. PLANE 8-12		18.5		3		20						F. Joint Health :				
SNB 78-82		79.0		5		0										
PFH/AFH 0.65-0.75		-		3		▲										
		C.F. Difficulty Total				▲										

Oral Photos

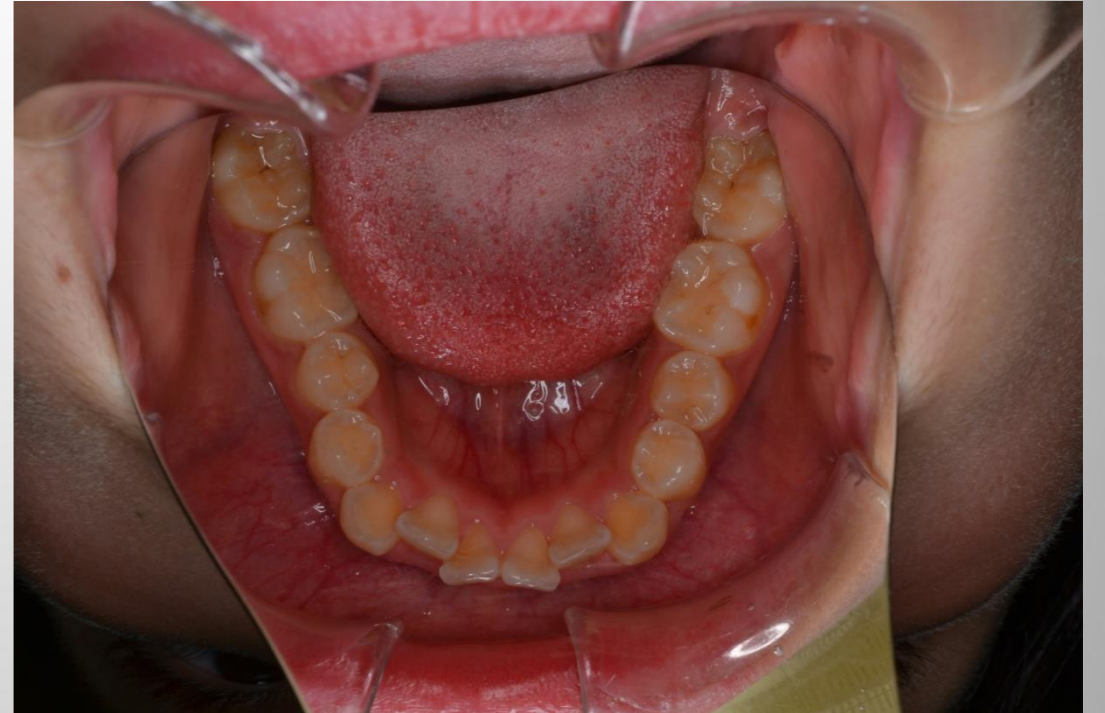
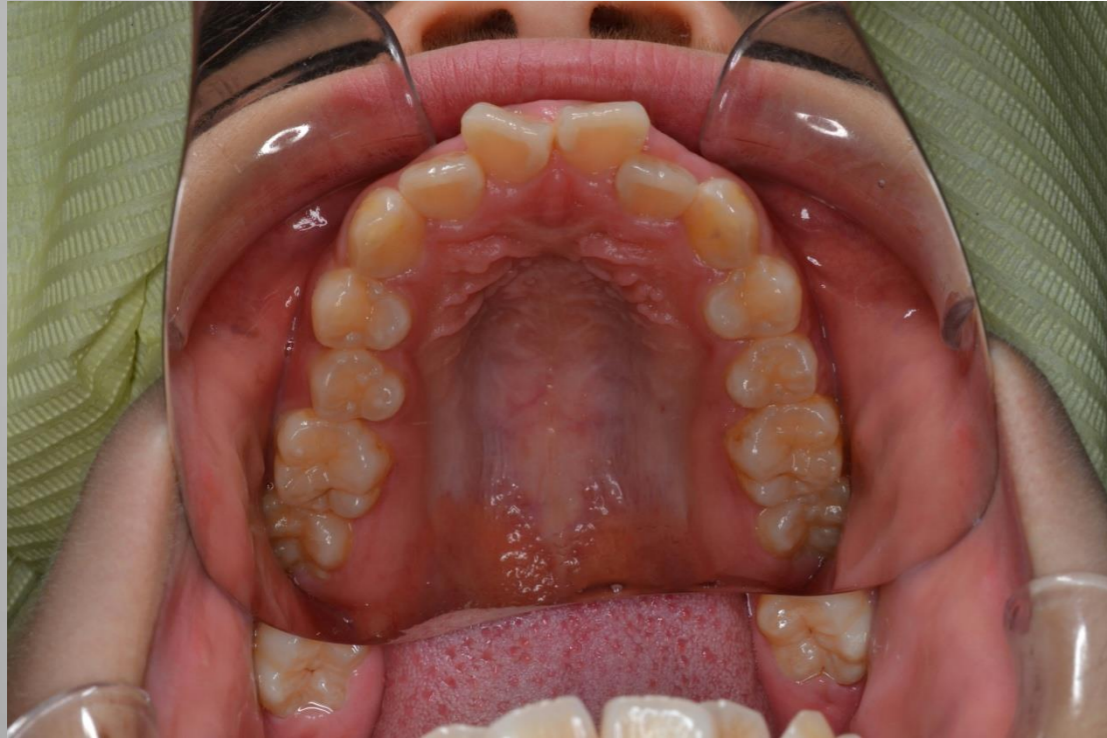
Pre Treatment

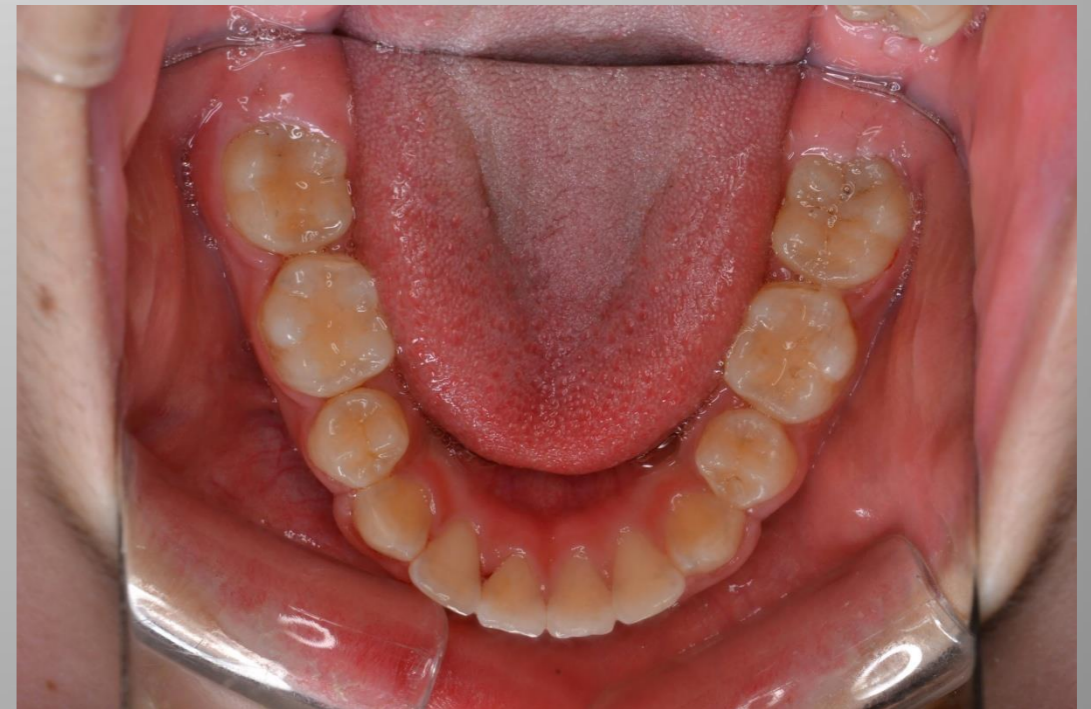
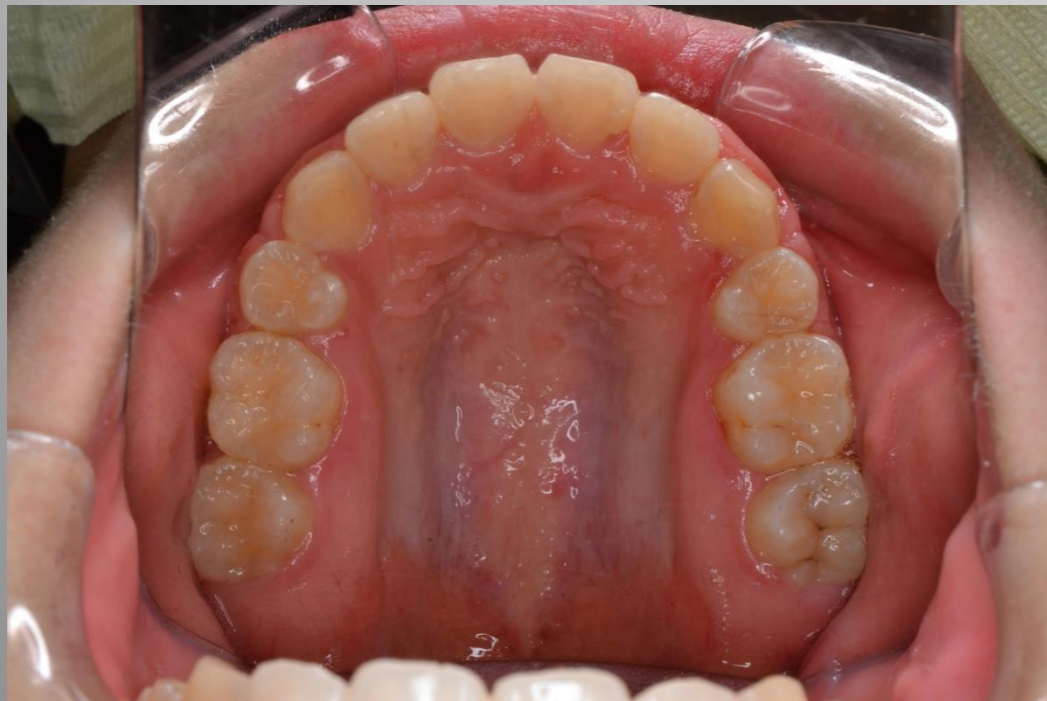
FINAL

Oral Photos

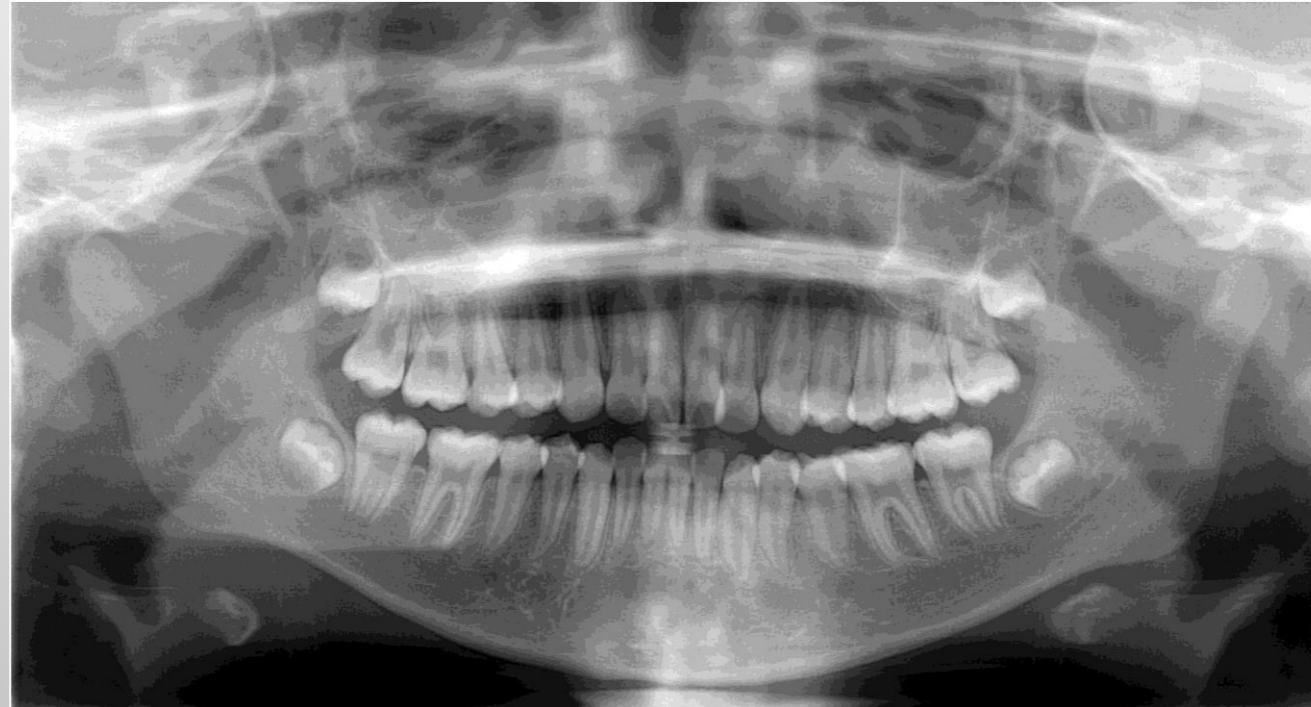

Pre Treatment

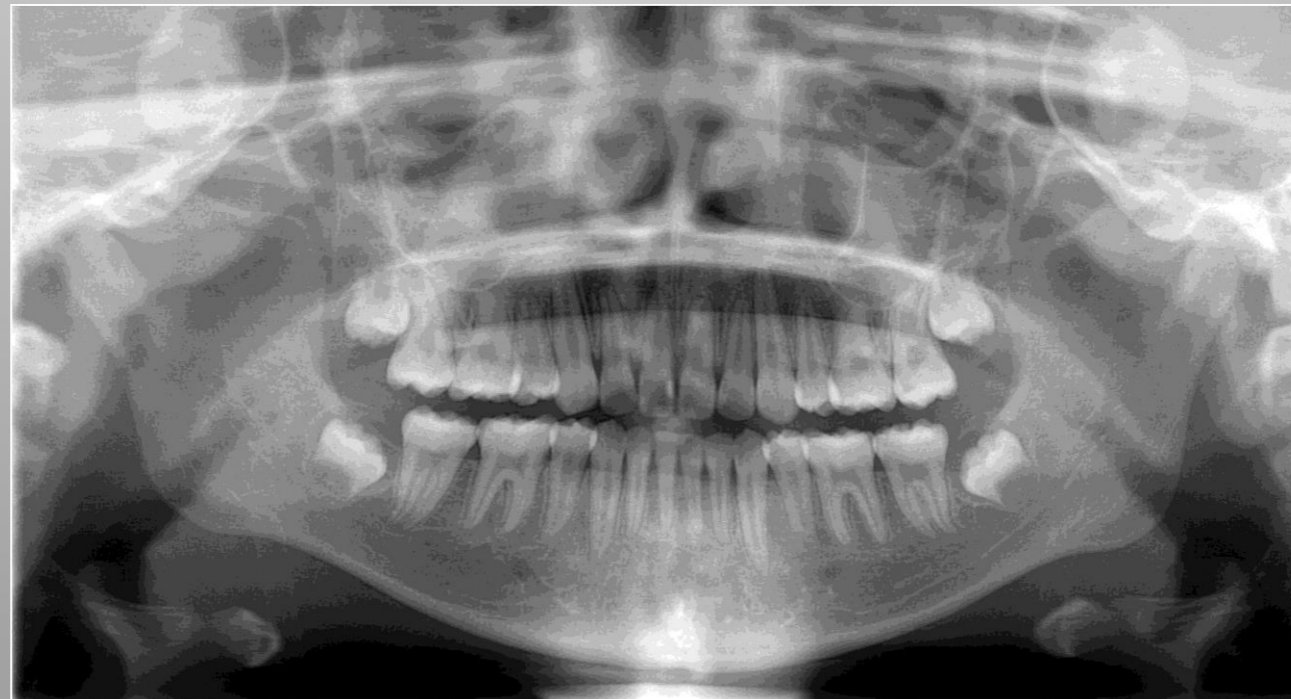


FINAL

Panorama X ray Photos

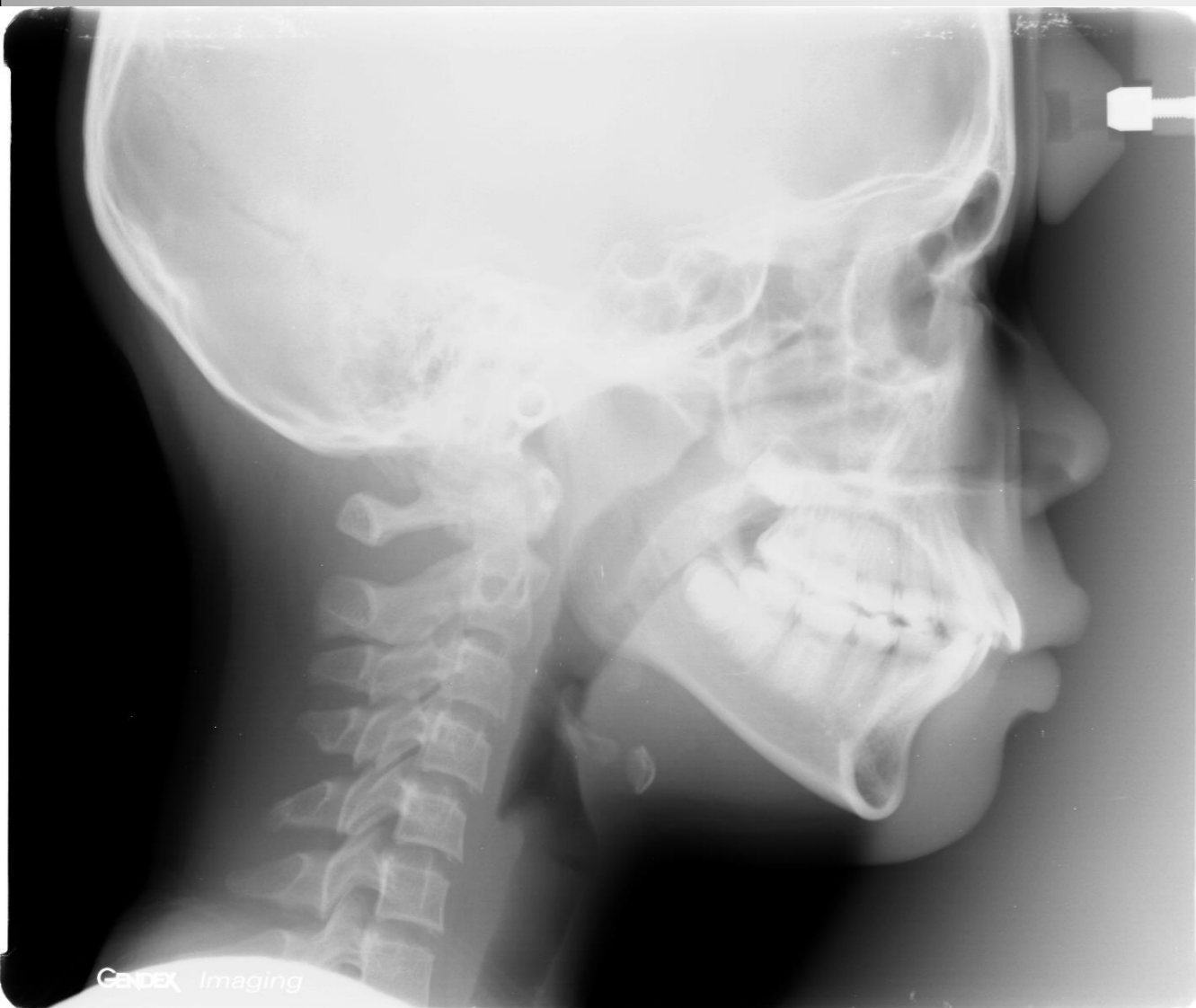

Pre Treatment

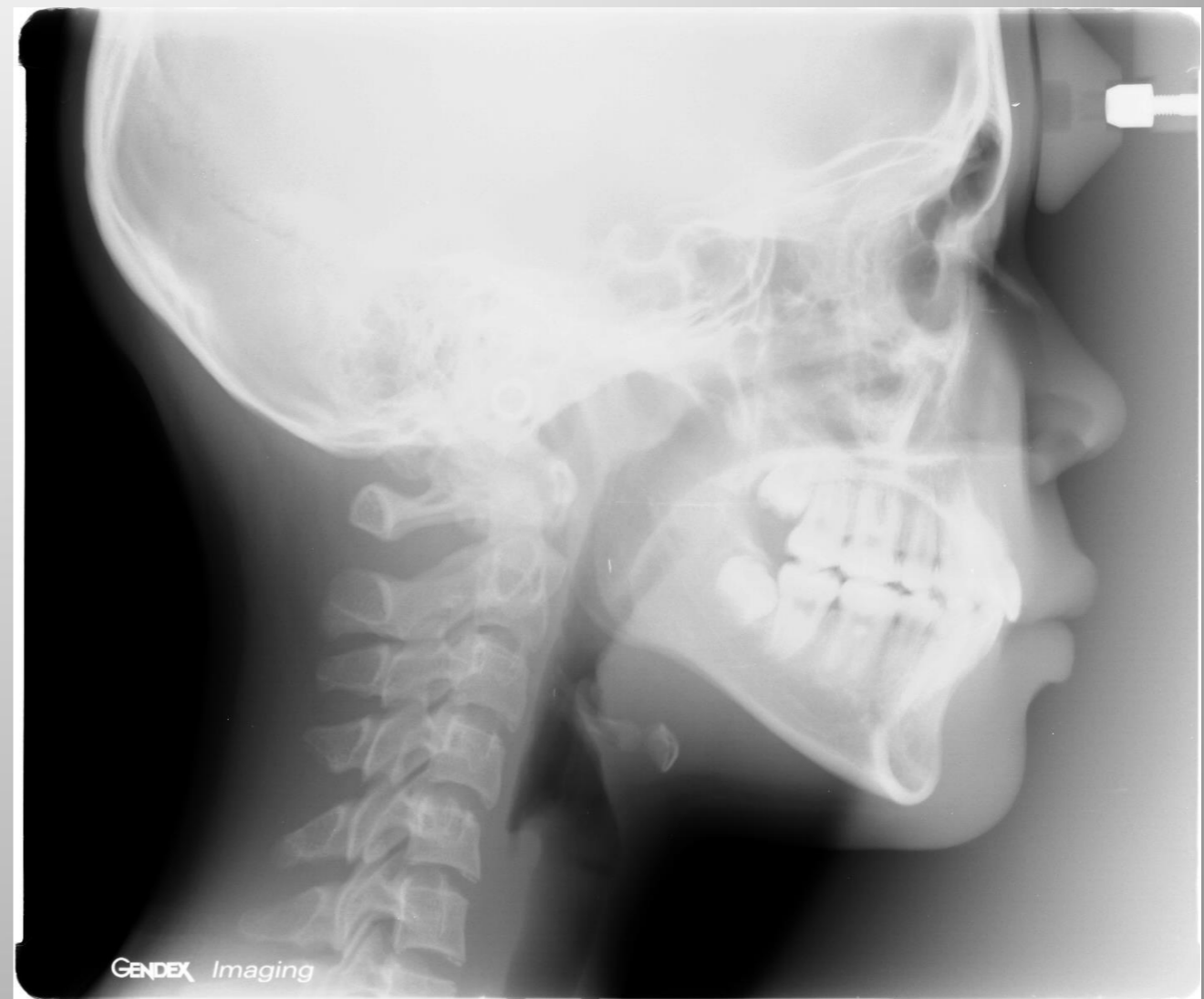


FINAL

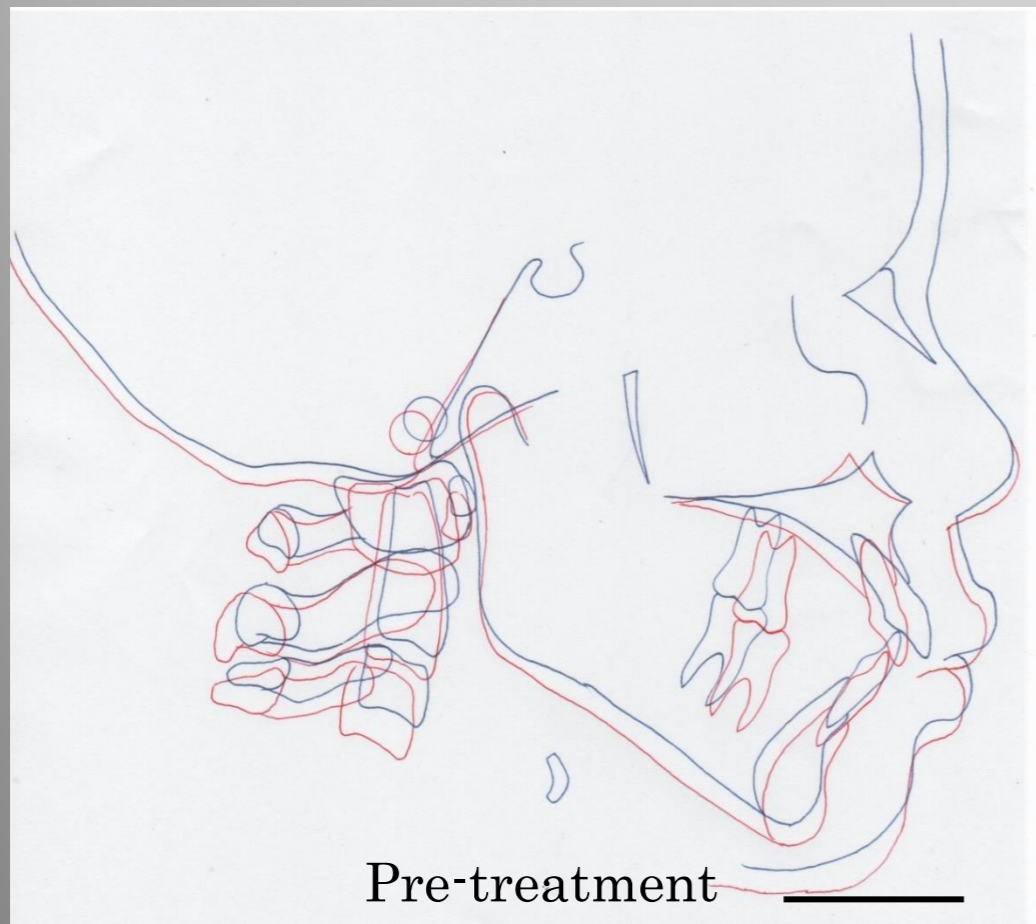
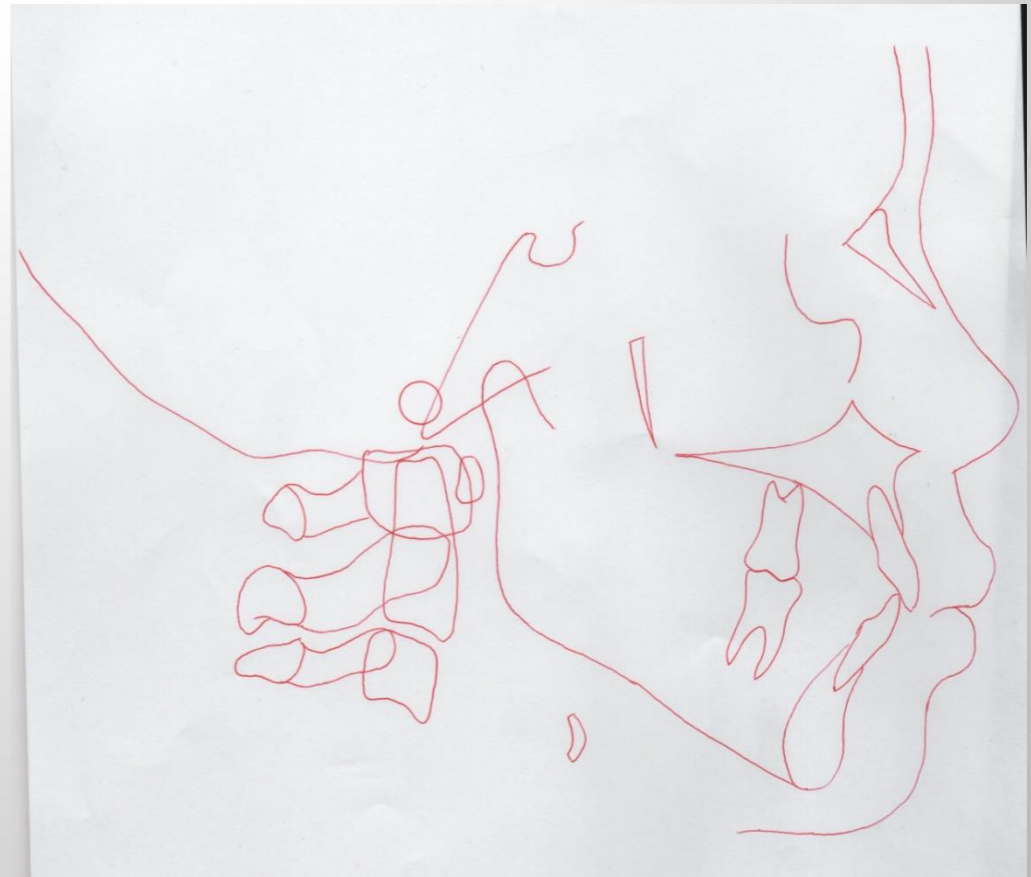
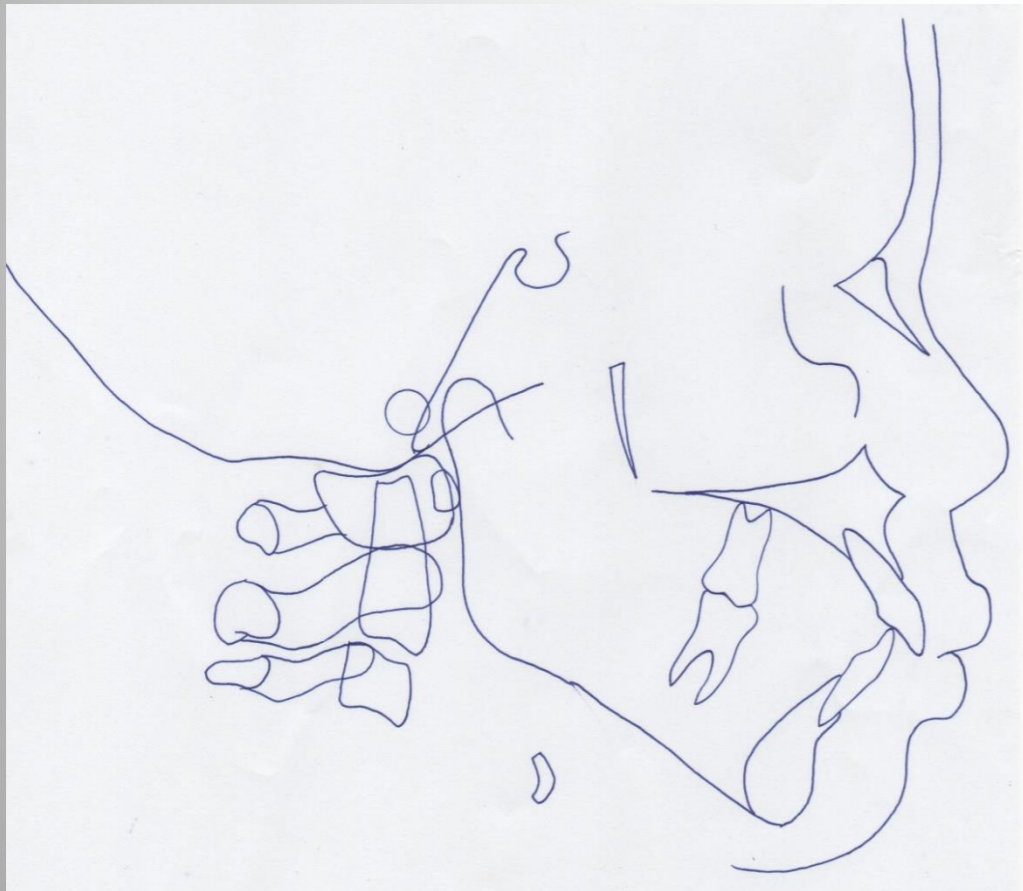
Cephalo X ray Photos



Pre Treatment



FINAL



Pre-treatment

Post-treatment

