

Differential Diagnosis & Clinical Analysis

Angle Class I, bimaxillary protrusion

ORTHODONTIST'S NAME _____ CODE: _____

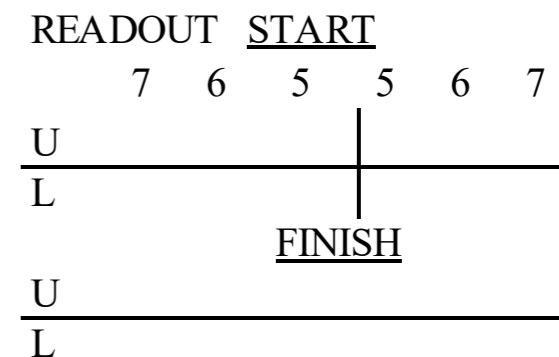
I = TWEED COURSE INSTRUCTOR, M = TWEED MEMBER, A = APPLICANT FOR MEMMBERSHIP

DIFFERENTIAL DIAGNOSIS AND CLINICAL ANALYSIS

PATIENT'S FIRST NAME: _____ INI _____ LAST NAME: _____

BEGIN TX. AGE 17Y 7M SEX F BIRTHDAY 1994 / 4 / 7 TREATMENT TIME: 26 MONTHS

DATE	NORMAL	PRE-TX	PROGRESS	FINAL	POST-TX
FMIA	67	46.0		55.5	
FMA	25	39.5		39.5	
IMPA	88	94.5	180.0	85.0	180.0
SNA	82	78.0		78.0	
SNB	80	72.5		72.0	
ANB	2	5.5	0.0	6.0	0.0
AO-BO	2mm	3.5 mm	mm	4.0 mm	mm
OCC PLANE	10	12.0		15.0	
Z ANGLE	75	59.0		69.0	
UPPER LIP		8.0 mm	mm	12.5 mm	mm
TOTAL CHIN		11.5 mm	mm	11.5 mm	mm
POST. FACIAL HT.	45mm	38.0 mm	mm	38.0 mm	mm
ANT. FACIAL HT.	65mm	65.0 mm	mm	65.5 mm	mm
FAC. HT. INDEX	0.69	0.59	####	0.58	####
FAC. HT. CHANGE	2:1	XXXX	/	/	/
MAND. CUSPID WIDTH		29.5 mm	mm	30.0 mm	mm
MAND. MOLAR WIDTH		53.0 mm	mm	50.0 mm	mm



DIAGNOSIS:

A. Skeletal : II

B. Dental : I

C. Perio : none

D. Facial : convex

CRANIAL FACIAL ANALYSIS

	Ceph. Value	Difficulty Factor	Difficulty
Normal Range			
FMA 22-28	<u>39.5</u>	5	<u>58</u>
ANB 1-5	<u>5.5</u>	15	<u>8</u>
Z-ANGLE 70-80	<u>59.0</u>	2	<u>22</u>
OCC. PLANE 8-12	<u>12.0</u>	3	<u>0</u>
SNB 78-82	<u>72.5</u>	5	<u>28</u>
PFH/AFH 0.65-0.75	<u>0.59</u>	3	<u>18</u>
C.F. Difficulty Total			<u>133</u>

E. Habits : none
 1. Thumb Sucker
 2. Tongue Thrust
 3. Bruxism

F. Joint Health : good

TOTAL SPACE ANALYSIS

		Difficulty Factor	Difficulty
Anterior			
Tooth Arch Disc.	<u>3.0</u>	1.5	<u>4.5</u>
Headfilm Disc.	<u>15.2</u>	1	<u>15.2</u>
Total	<u>18.2</u>		
Mid Arch			
Tooth Arch Disc.	<u>0.0</u>	1.0	<u>0.0</u>
Curve of Spee	<u>2.0</u>	1.0	<u>2.0</u>
Total	<u>2.0</u>		
Horizontal Occlusal Disharmony (Class II or Class III)		2.0	<u>0.0</u>
Posterior			
Tooth Arch Disc.	<u>14.0</u>		
(-)expected Inc.			
Total	<u>14.0</u>	0.5	<u>7.0</u>
Space Analysis Total	<u>34.2</u>	Space Analysis Difficulty Total	<u>28.7</u>

TRERATMENT PLANNING, TIMING
 EXTRACTIONS:

MAXILLARY

RIGHT 4 LEFT 4

MANDIBULAR

RIGHT 84 LEFT 48

(Please Indicate Missing Teeth)

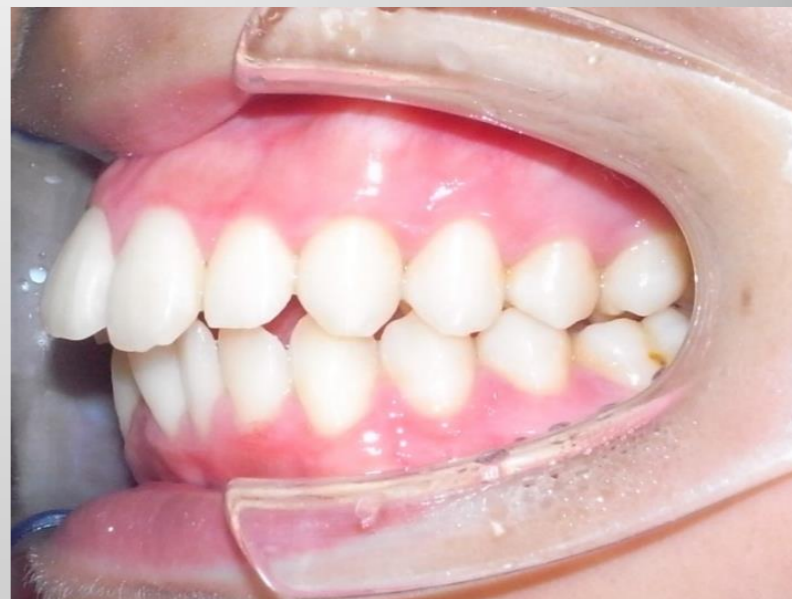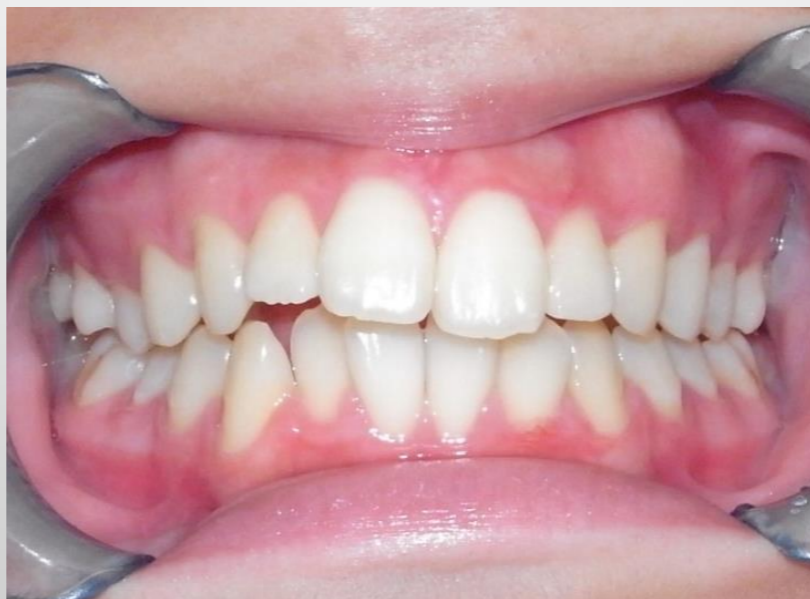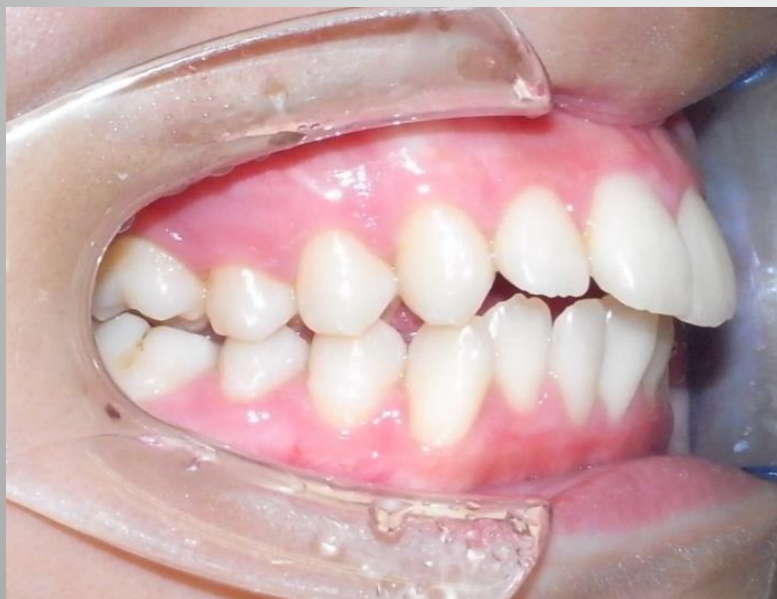MANDIBULAR

DIFFICULTY INDEX :

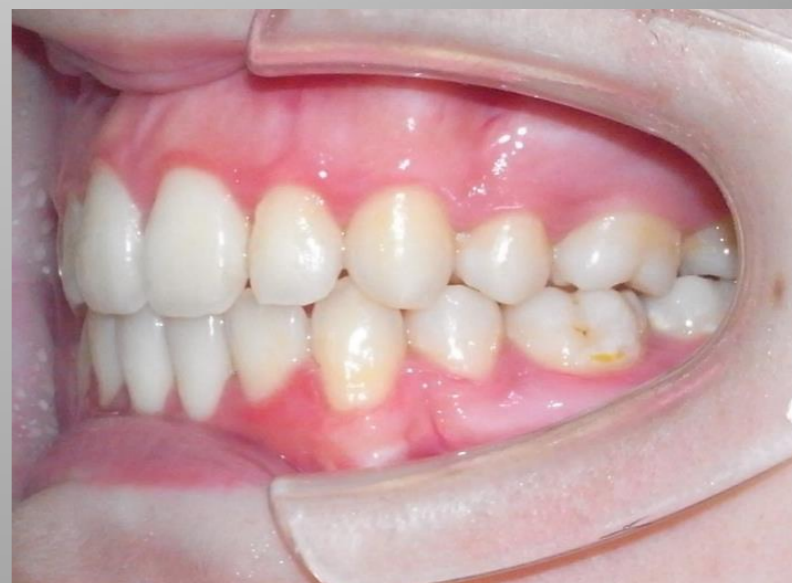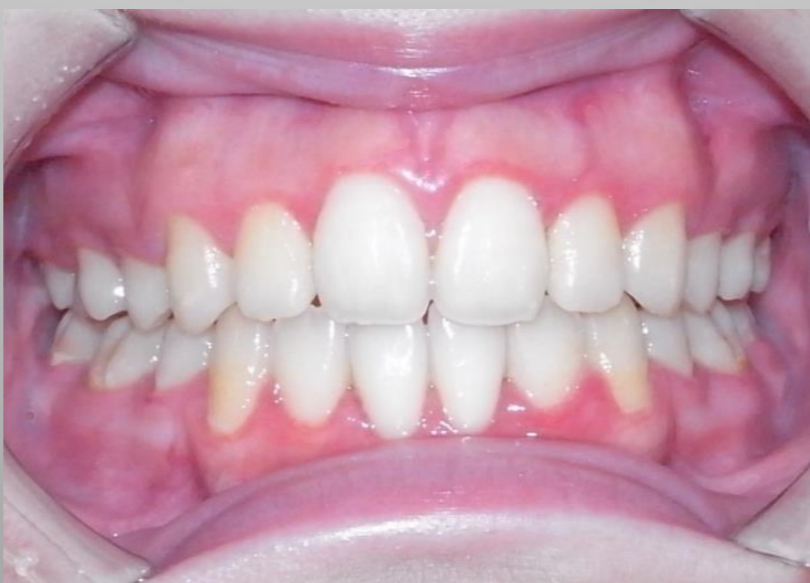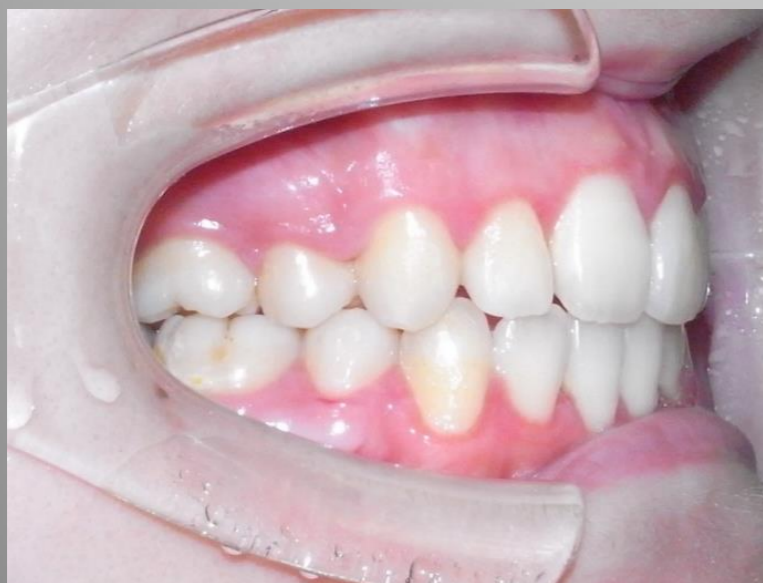Mild 0 - 60
 Moderate 60 - 120
Severe over 120

C.F. Difficulty Total 132.5
Space Analysisi Difficulty Total 28.7
Total Difficulty 161.2

Oral Photos

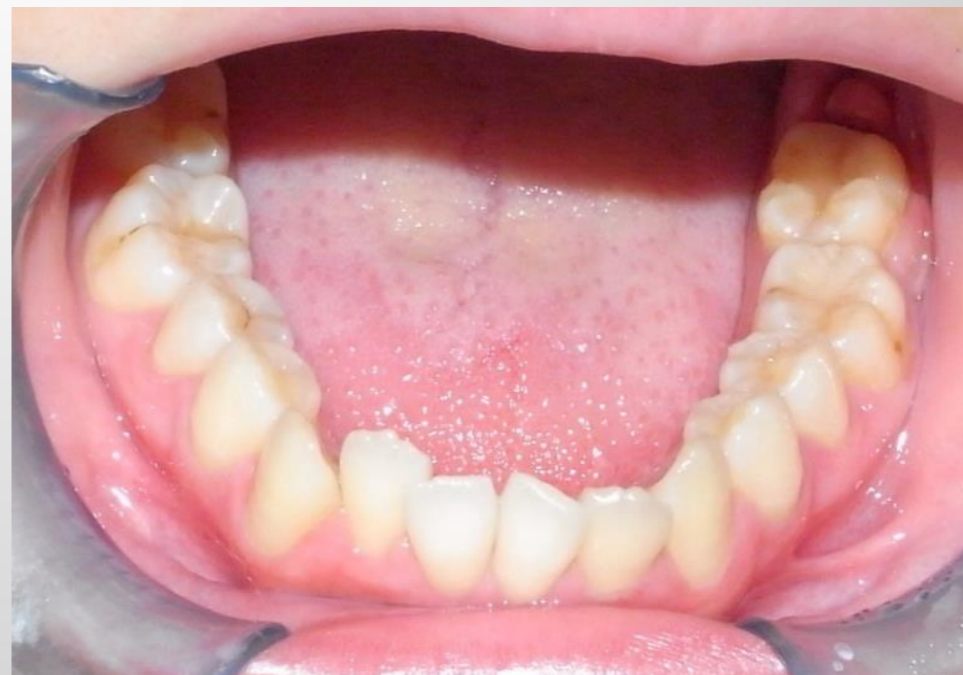
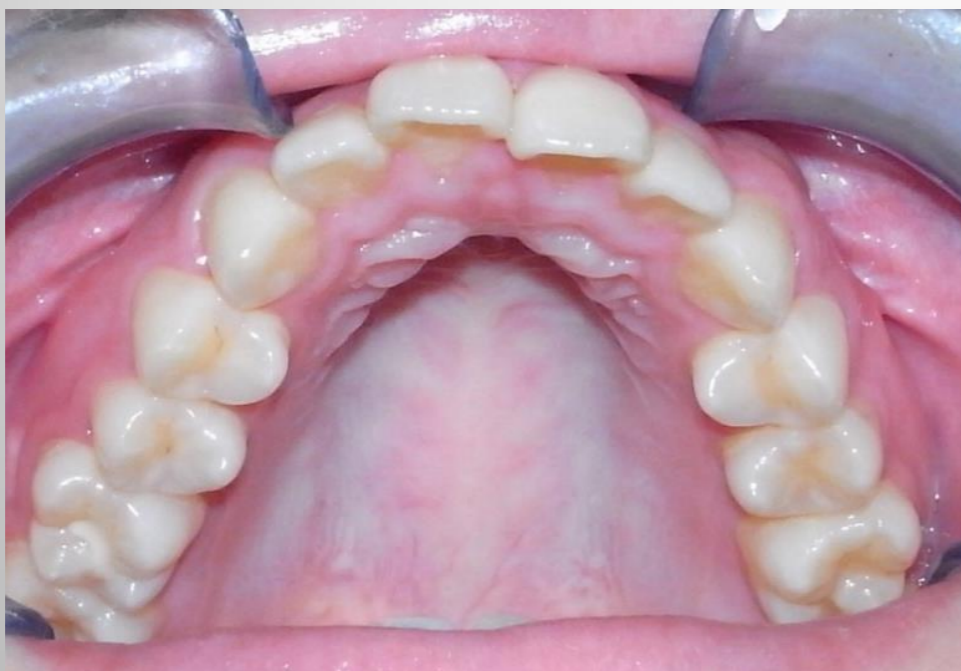
Pre Treatment

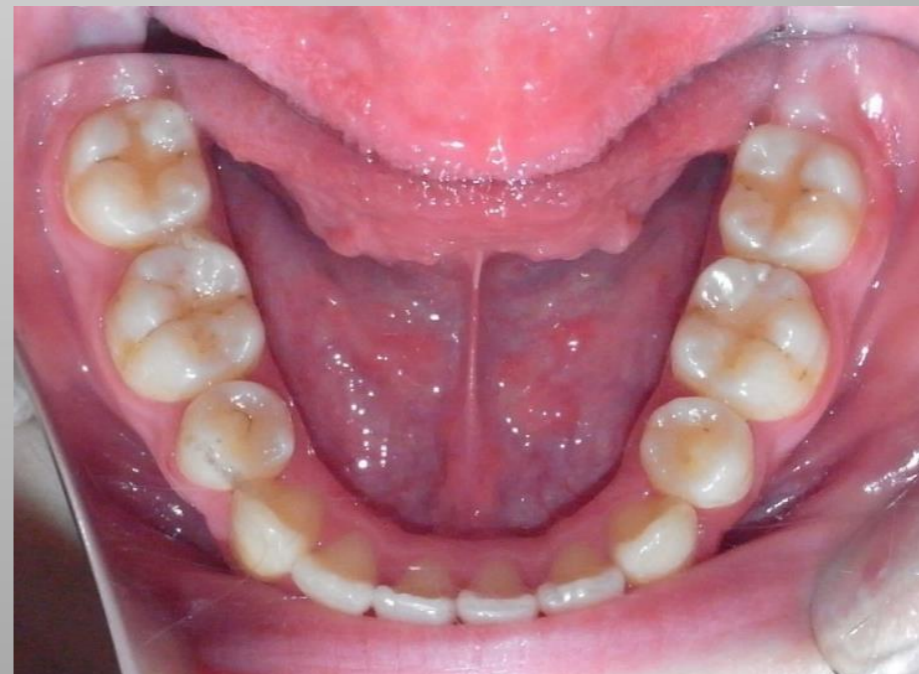
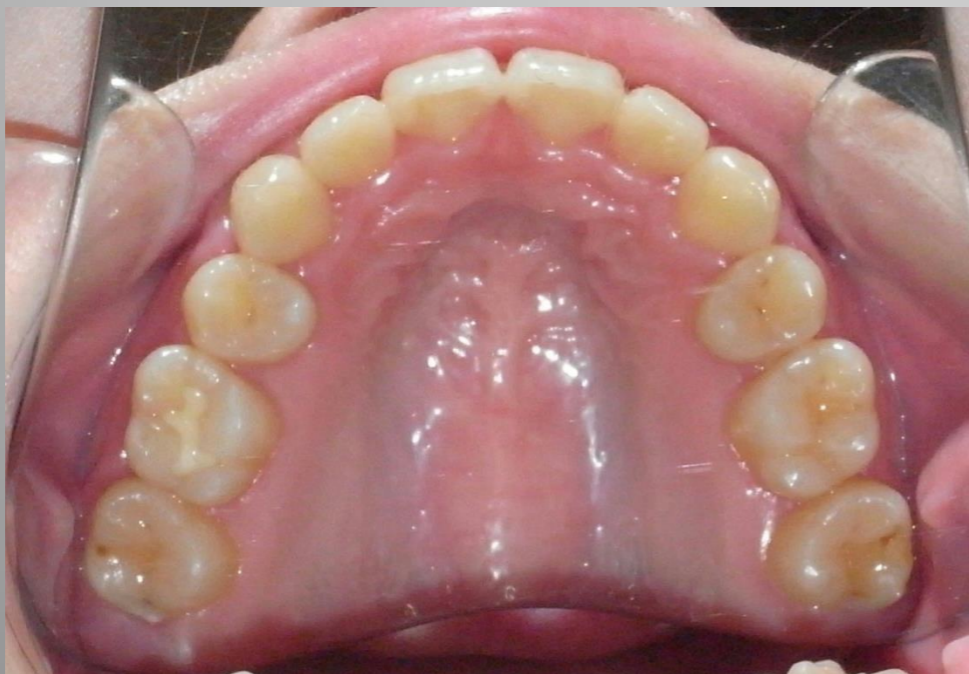
Post Treatment

Oral Photos

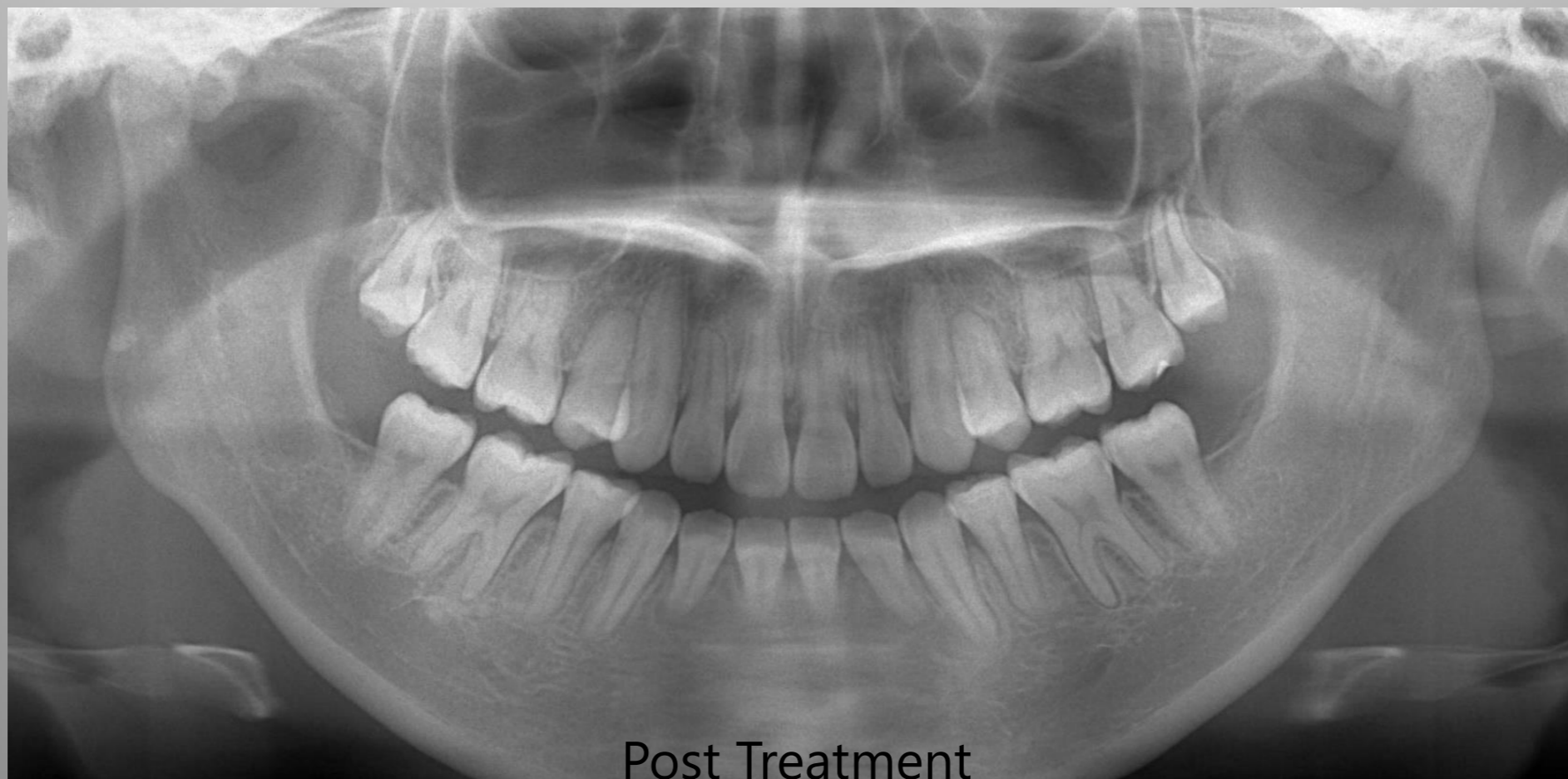
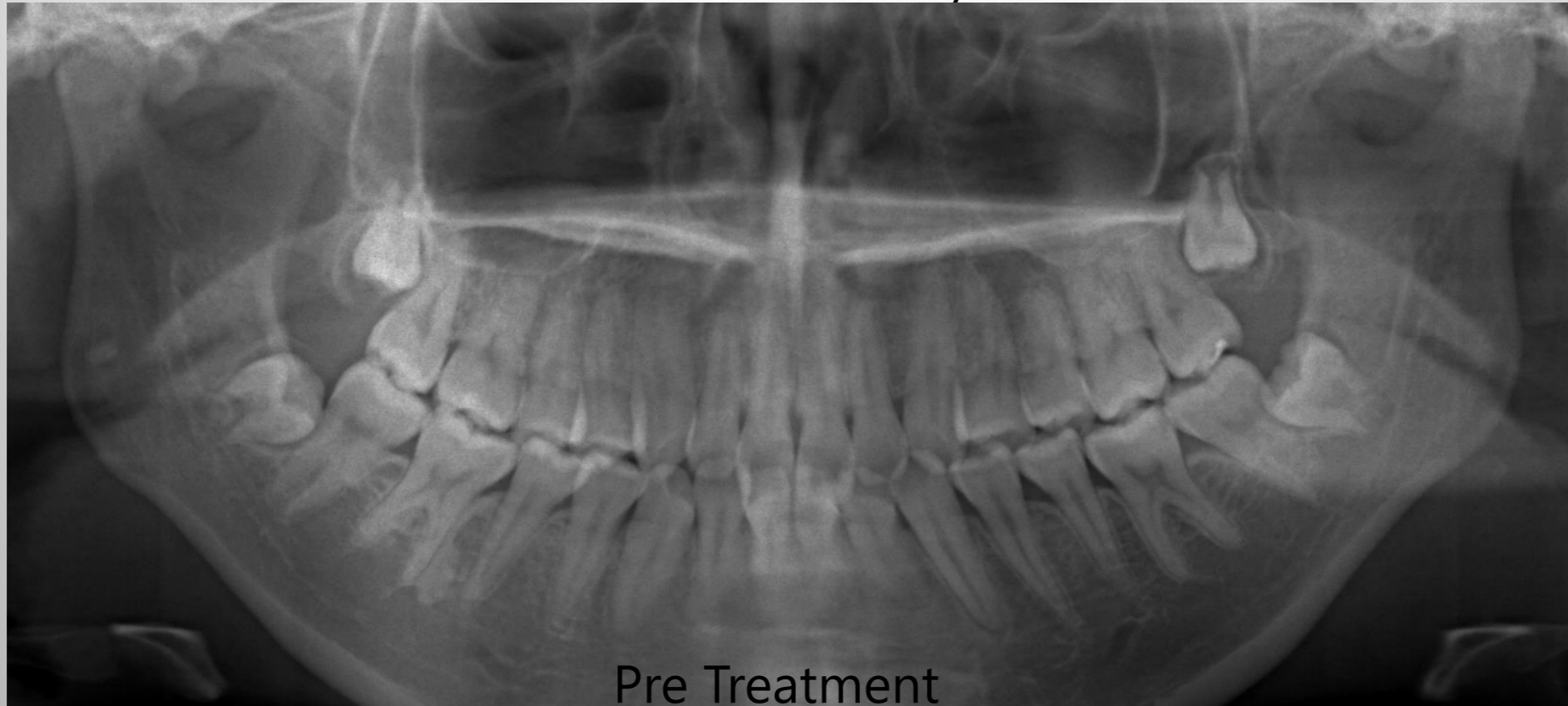

Pre Treatment

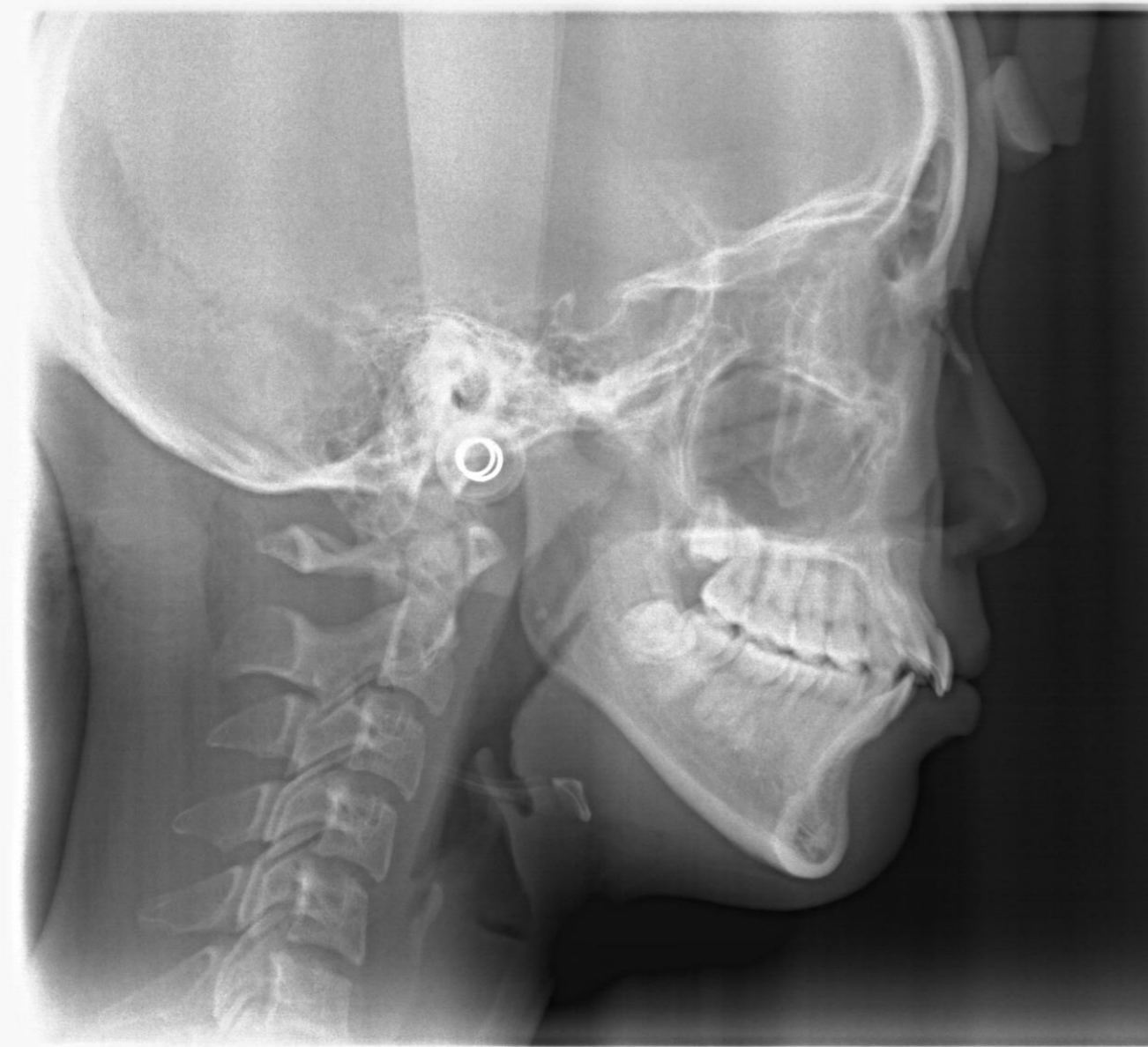

Post Treatment

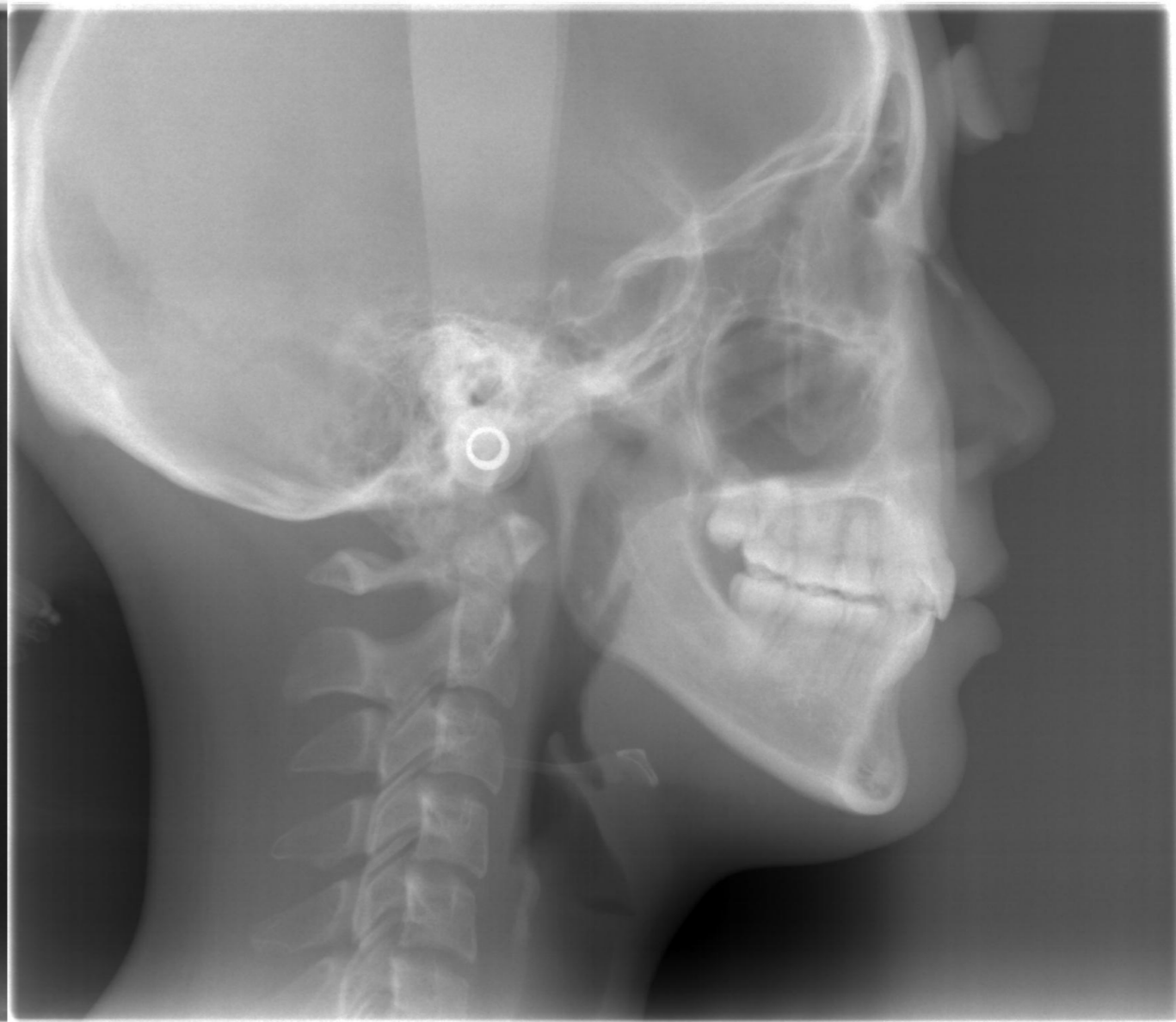Panorama X ray Photos



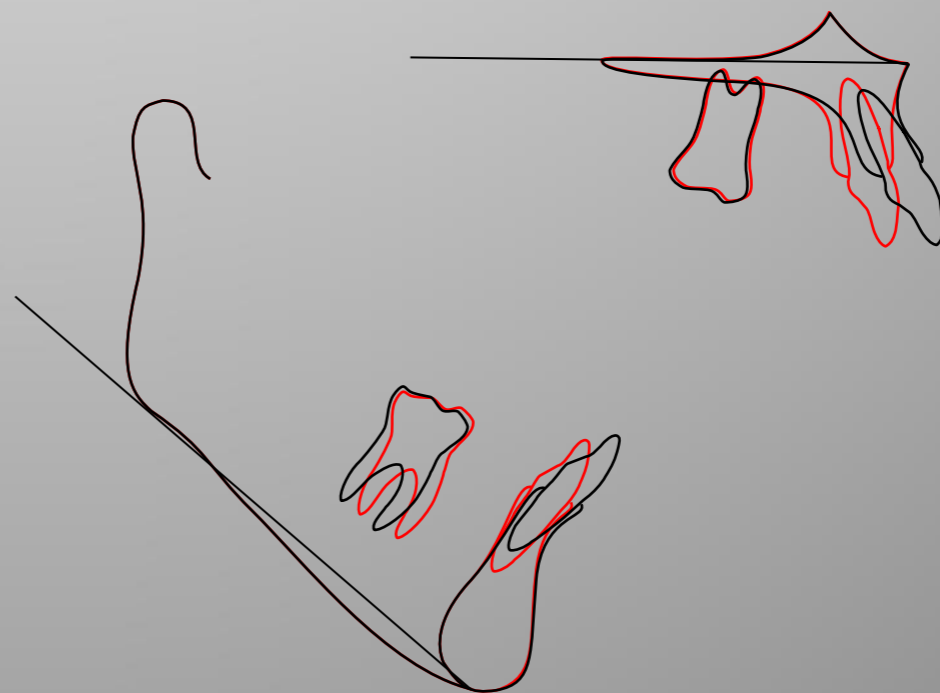
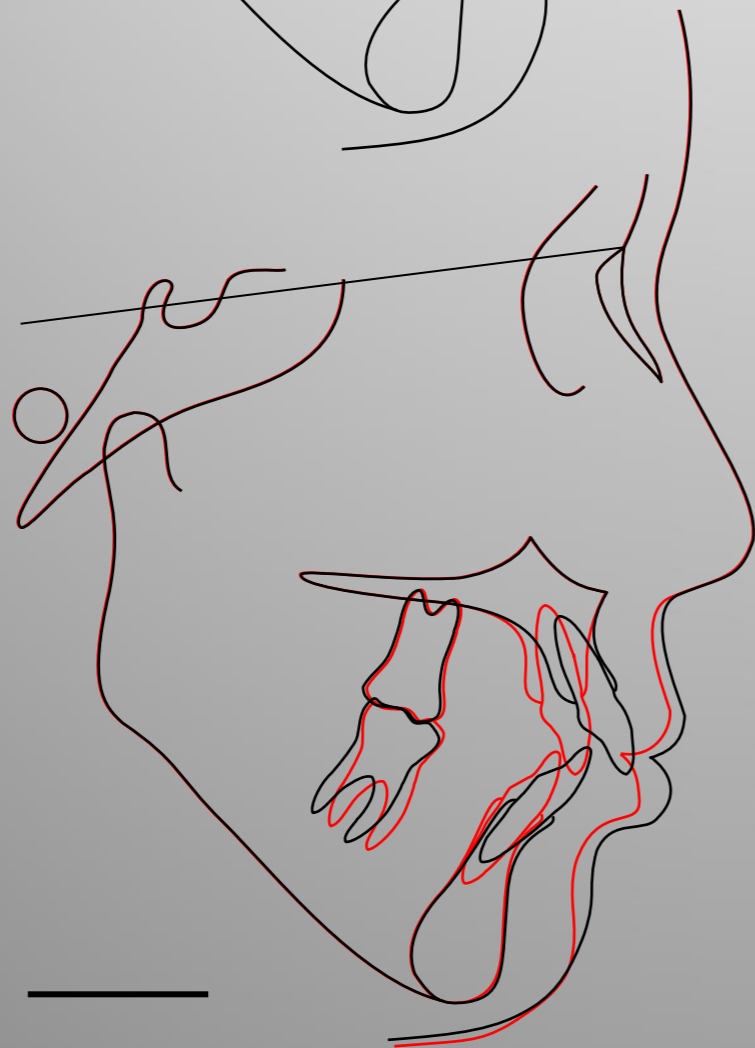
Cephalo X ray Photos



Pre Treatment



Post Treatment



Pre-treatment ———
Post-treatment ———