

Differential Diagnosis & Clinical Analysis

DIFFERENTIAL DIAGNOSIS AND CLINICAL ANALYSIS

ORTHODONTIST'S NAME _____

CODE M

PATIENT'S FIRST NAME _____ INI _____

LAST NAME _____

CASE NO. _____

BEGIN TX. AGE 55y3m SEX F BIRTHDAY 8/28/54 TREATMENT TIME 44 month

DATE	11/28/11		8/21/15	
NORMAI	PRE-TX	PROGRESS	FINAL	POST-TX
FMIA	67	48.0	69.0	
FMA	25	24.5	24.5	
IMPA	96	107.5	86.5	
SNA	82	79.5	80.5	
SNB	80	76.5	77.5	
ANB	2	3.0	3.0	
AO-BO (mm)	2	1.0	1.5	
OCC PLANE	10	3.0	3.0	
Z ANGLE	75	64.0	79.0	
UPPER LIP (mm)		10.0	12.0	
TOTAL CHIN (mm)		15.0	15.0	
POST. FACIAL HT. (mm)	45	47.0	47.5	
ANT. FACIAL HT. (mm)	65	66.5	66.0	
FAC. HT. INDEX		0.71	0.72	
FAC. HT. CHANGE		XXXXXX	0.5 / -0.5	
MAND. CUSPID WIDTH (mm)		28.0	29.0	
MAND. MOLAR WIDTH (mm)		49.0	44.0	

READOUT	START			FINISH		
	7	6	5	5	6	7
U						
L						
U						
L						

- DIAGNOSIS
- A. Skeletal Class I
 - B. Dental Class I
 - C. Perio NP
 - D. Facial Convex
 - E. habits 1. Thumb Sucker

CRANIAL FACIAL ANALYSIS

	Normal Range	Ceph. Value
FMA	22-28	24.5
ANB	1-5	3.0
Z-ANGLE	70-80	64.0
OCC.PLANE	8-12	3.0
SNB	78-82	76.5
PFH/AFH	0.65-0.75	0.71

TOTAL SPACE ANALYSIS

Anterior

Tooth Arch Disc.	7.0
Headfilm Disc.	16.0
Total	23.0

Mid Arch

Tooth Arch Disc.	5.0
Curve of Spee	3.0
Total	8.0

Horizontal Occlusal Disharmony
(Class II or Class III) 1.0

Posterior

Tooth Arch Disc.	0.0
(-)expected Inc.	0.0
Total	0.0

Space Analysis Total 32.0

C.F. Difficulty Total	34.5
Space Analysis Difficulty Total	36.5
Total Difficulty	71.0

Difficulty

Factor	Difficulty
<u>5</u>	<u>0.0</u>
<u>15</u>	<u>0.0</u>
<u>2</u>	<u>12.0</u>
<u>3</u>	<u>15.0</u>
<u>5</u>	<u>7.5</u>
<u>3</u>	<u>0.0</u>
C.F. Difficulty Total	34.5

Difficulty

<u>10.5</u>	
<u>16.0</u>	
<u>26.5</u>	
<u>5.0</u>	
<u>3.0</u>	
<u>8.0</u>	
<u>2.0</u>	
<u>0.0</u>	
Space Analysis Difficulty Total	36.5

3. Braxism

F. Joint Health

Good

TREATMENT PLANNING, TIMING

EXTRACTIONS:

MAXILLARY

RIGHT LEFT 4

MANDIBULAR

RIGHT LEFT 4

UR1, LR4, and LR5 are missing

(Please Indicate Missing Teeth)

Space Analysis

Difficulty Total 36.5

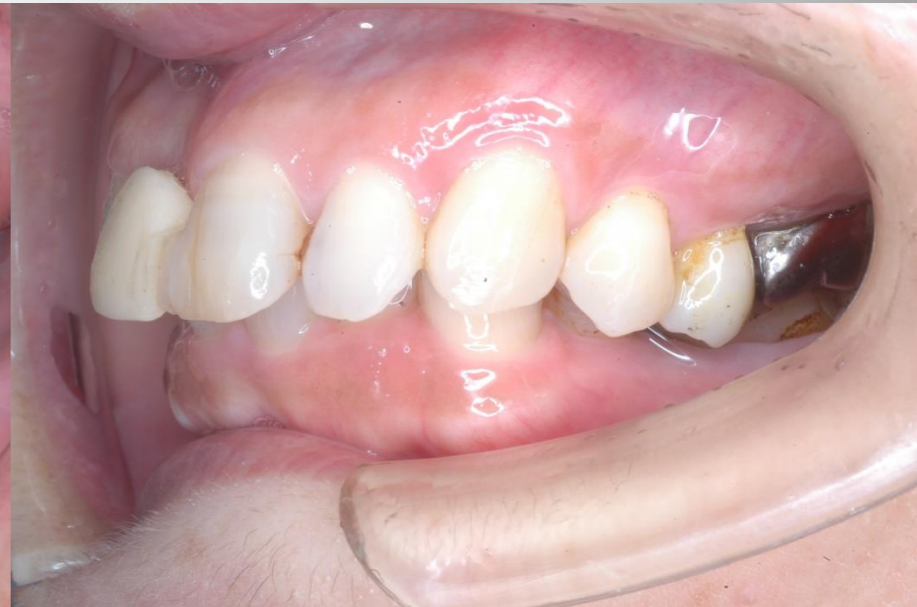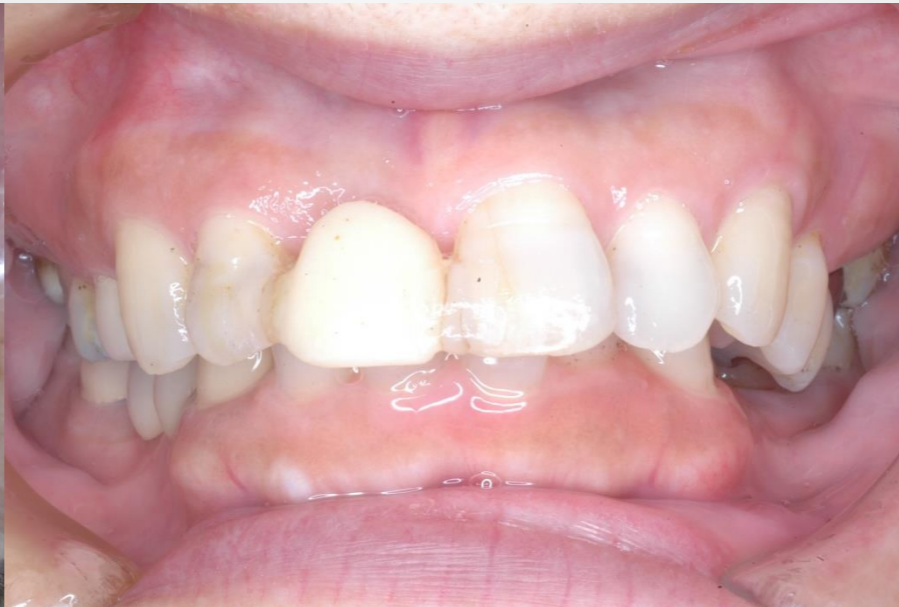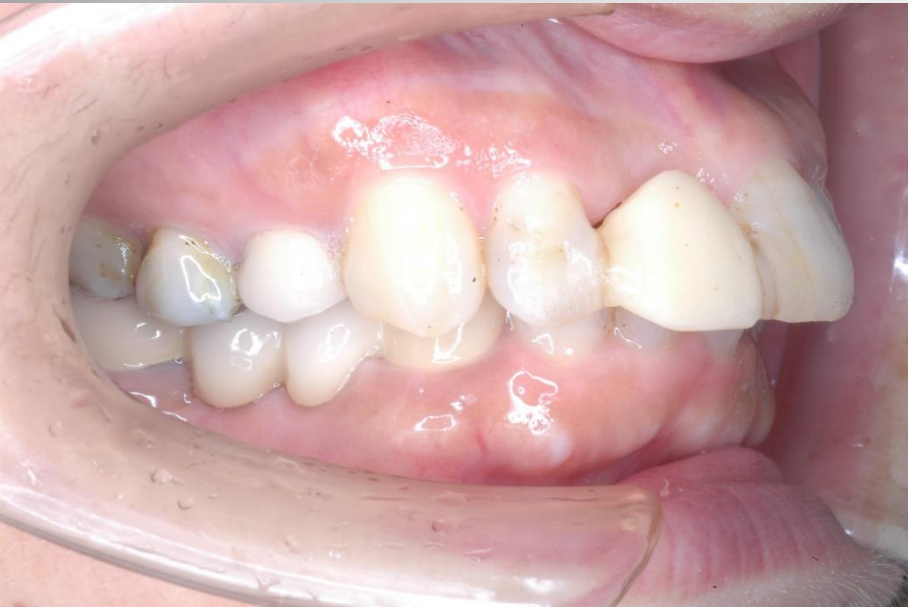DIFFICULTY INDEX :

Mild 0 - 60

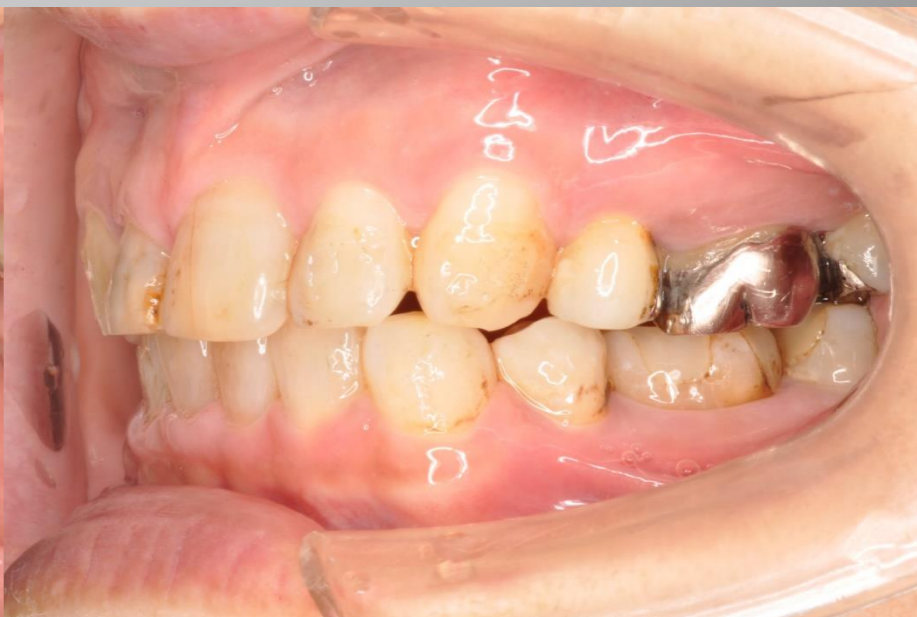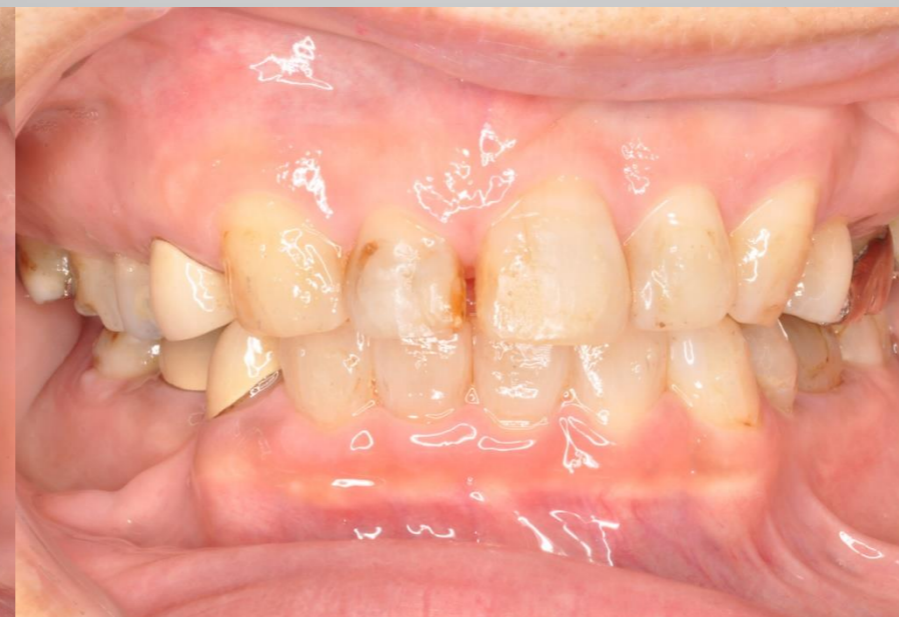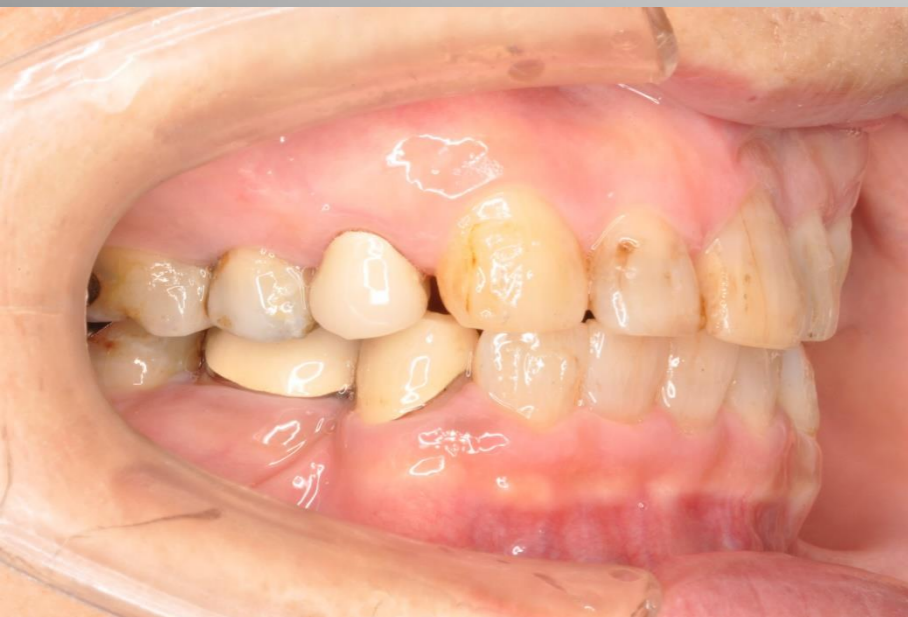Moderate 60 - 120

Severe over 120

Oral Photos

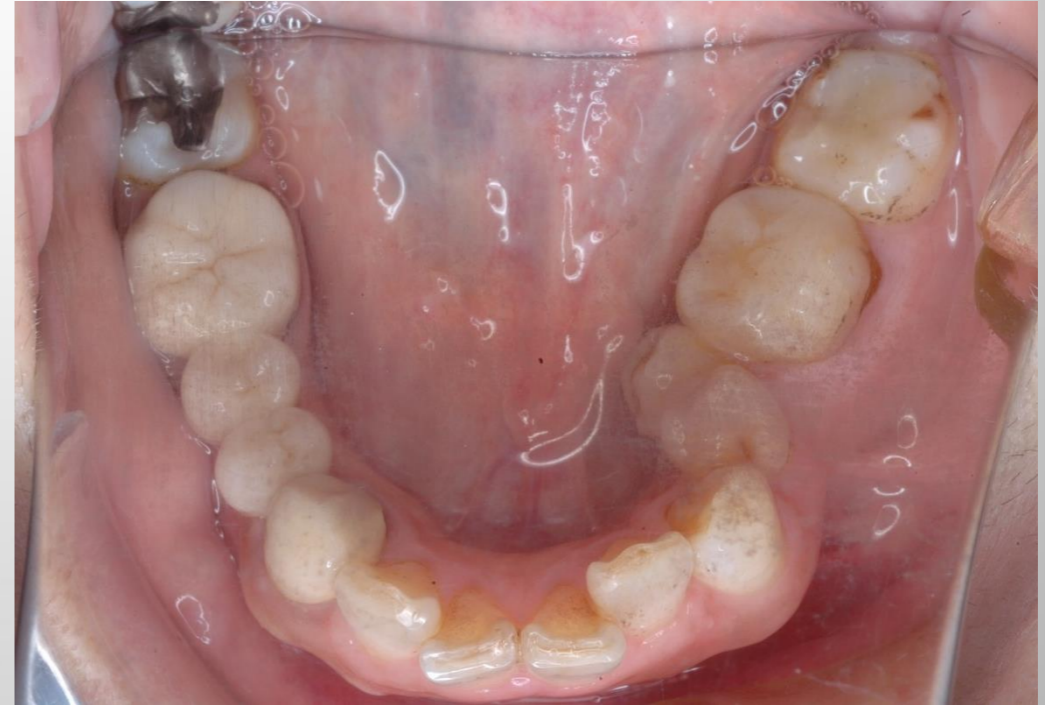
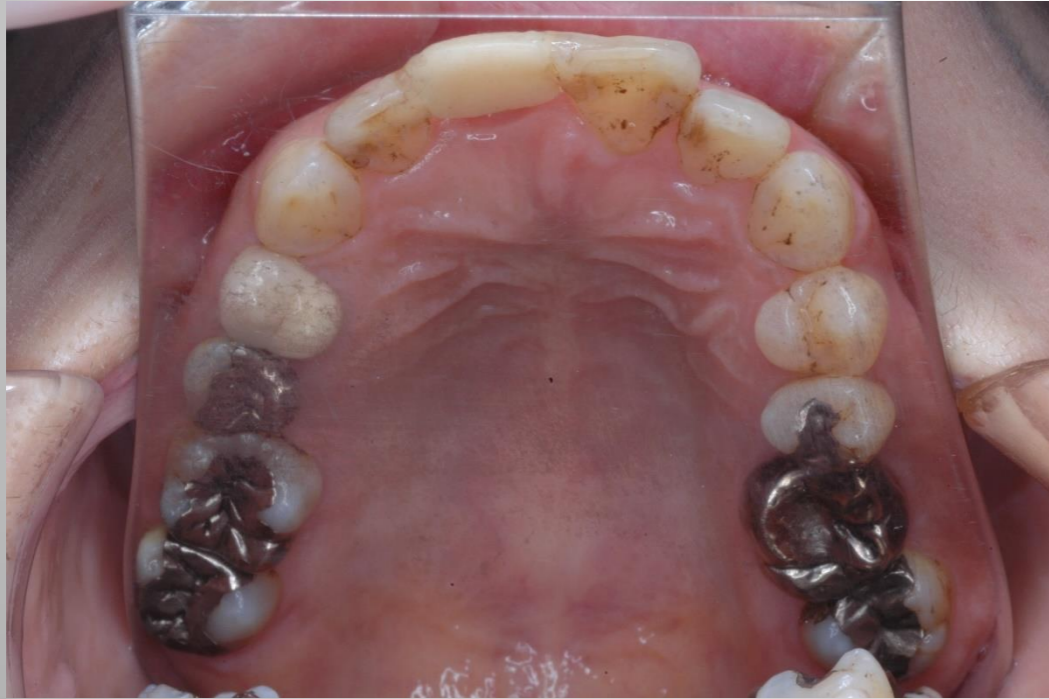

Pre Treatment

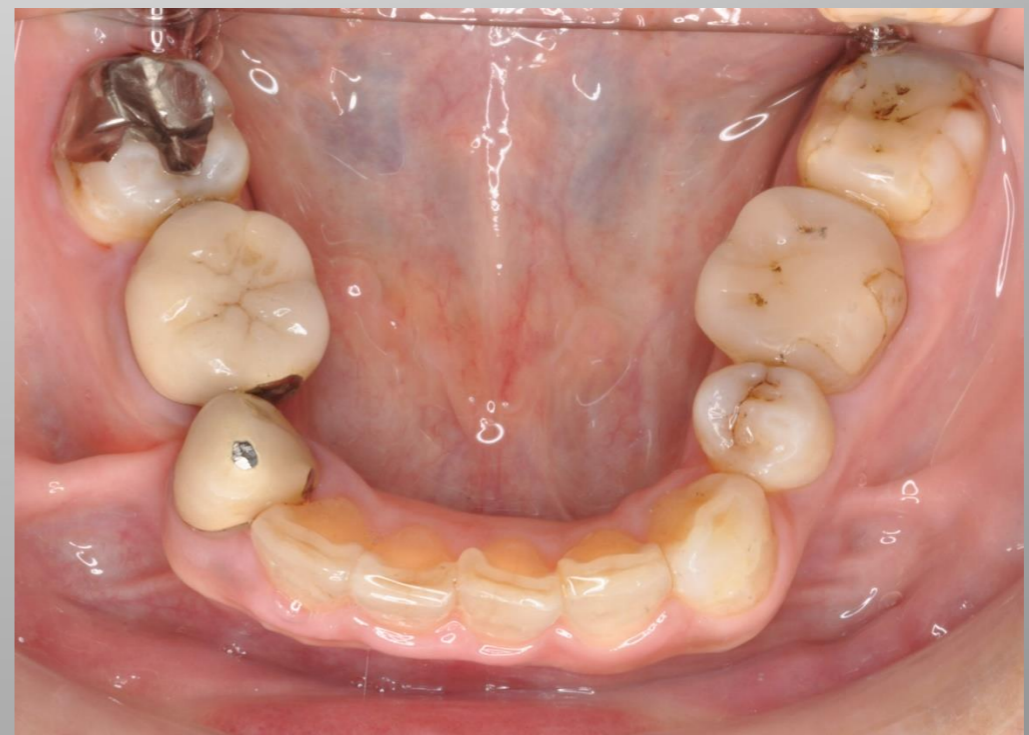
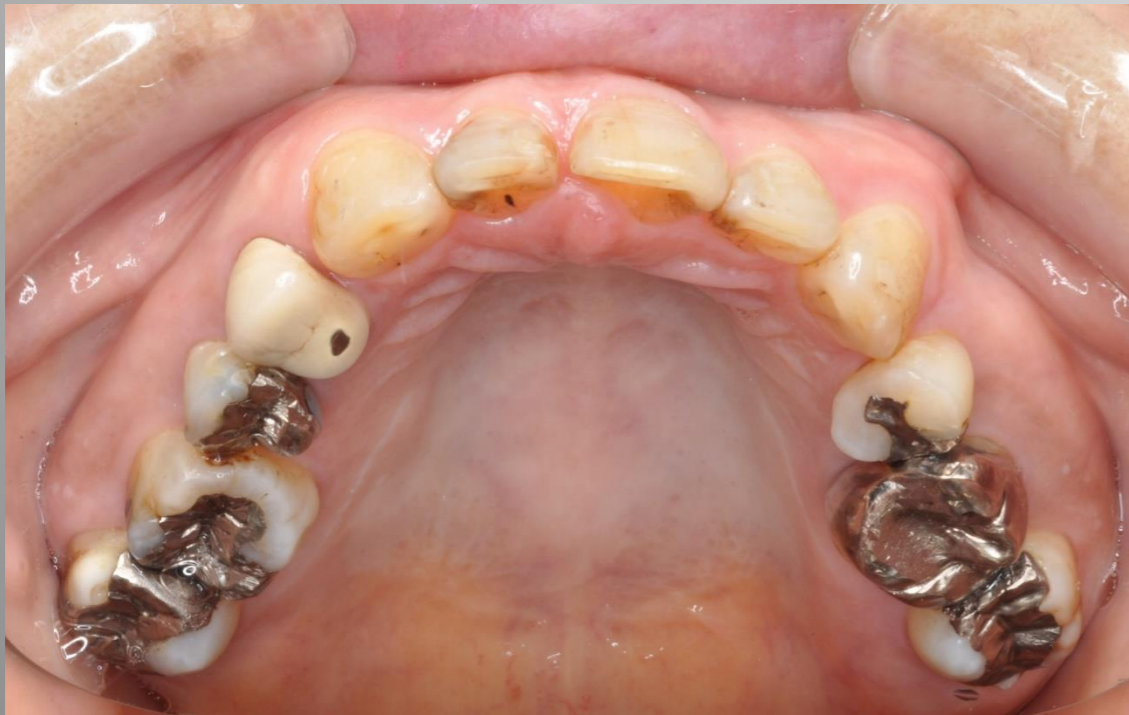

Post Treatment

Oral Photos

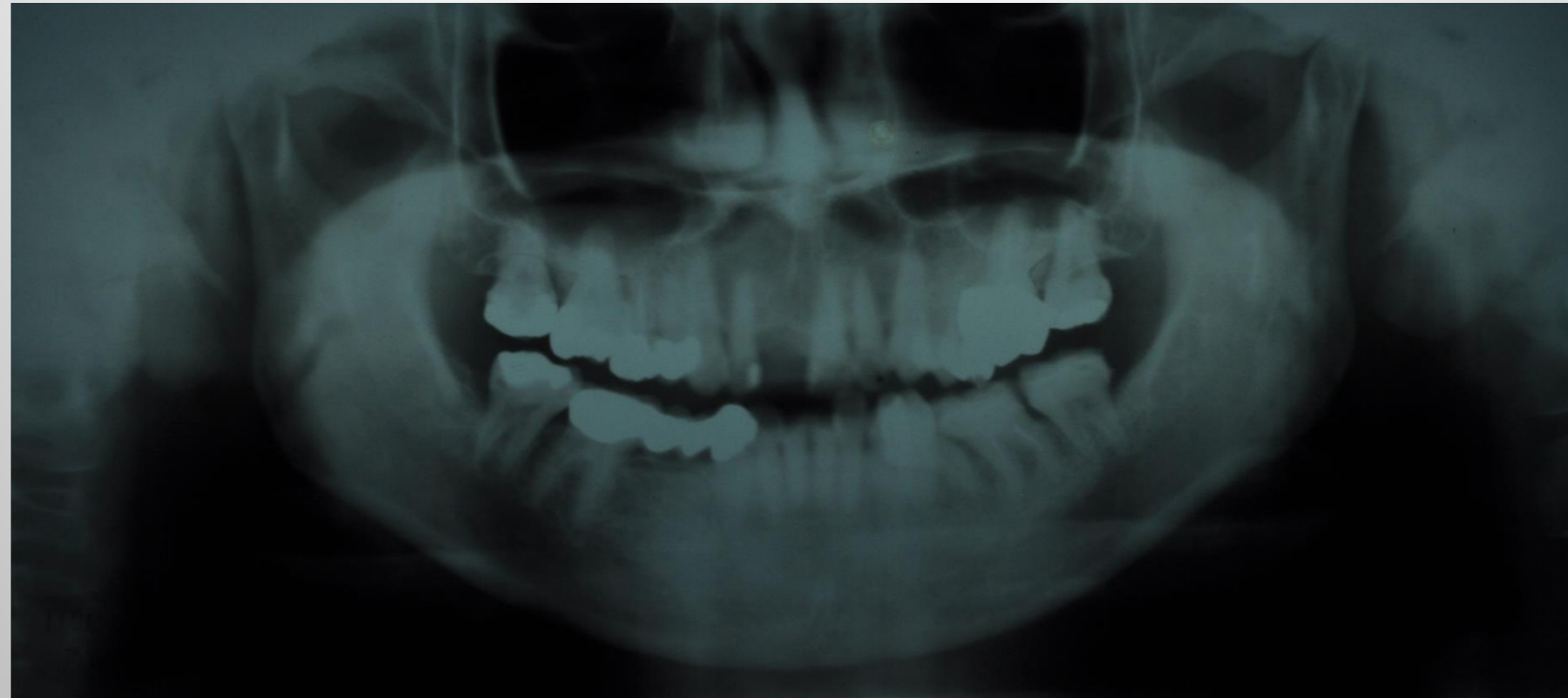


Pre Treatment

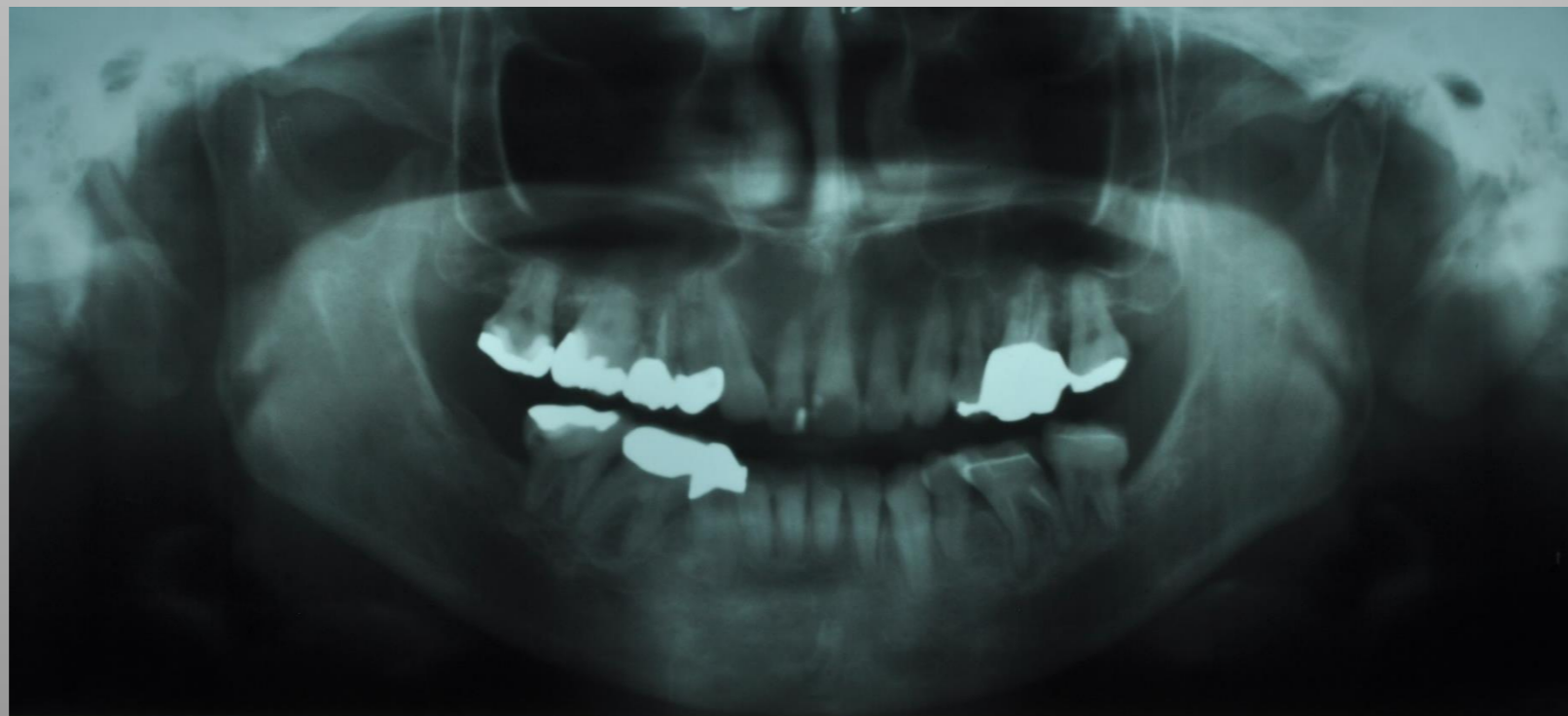


Post Treatment

Panorama X ray Photos

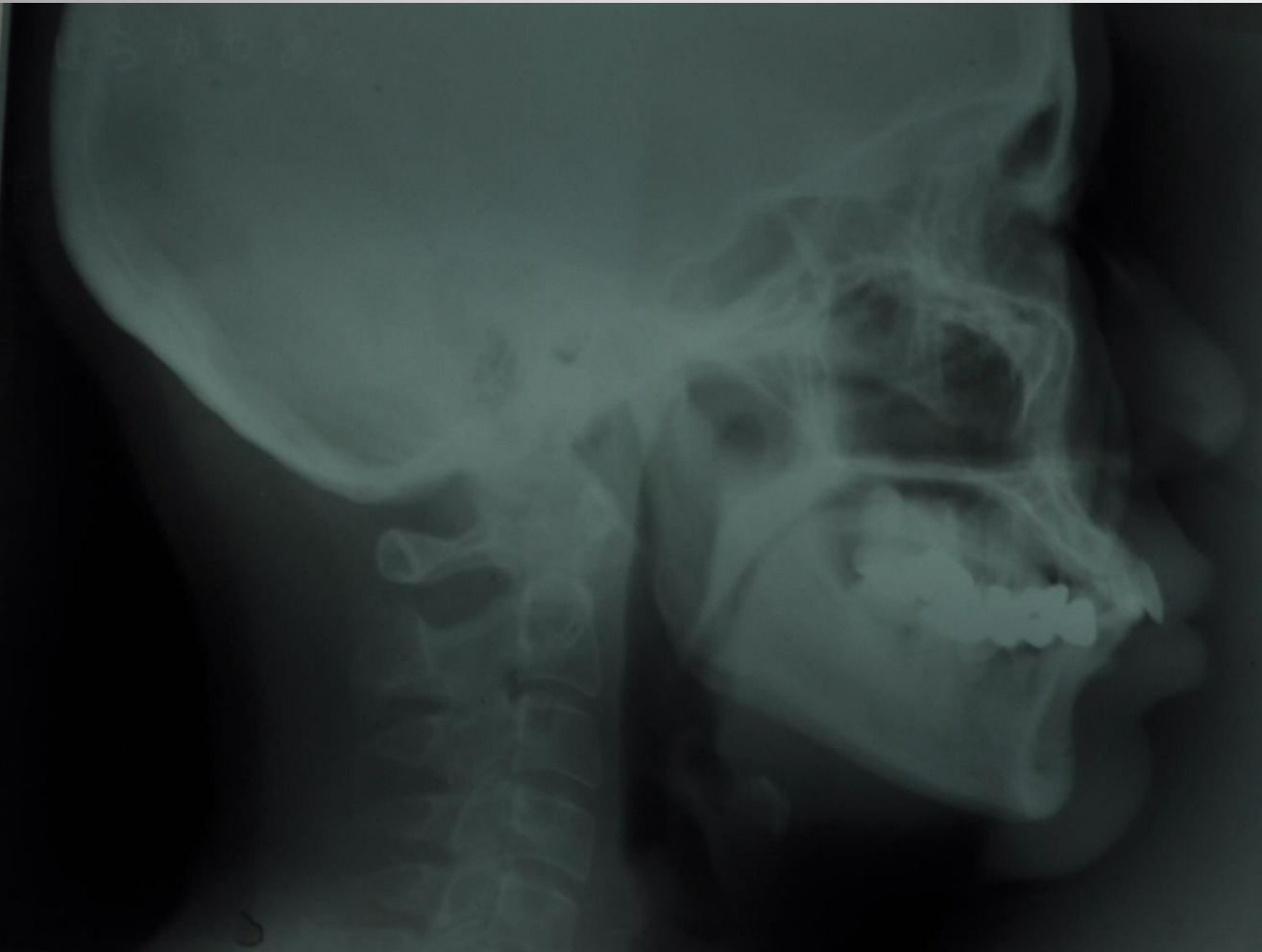

Pre Treatment

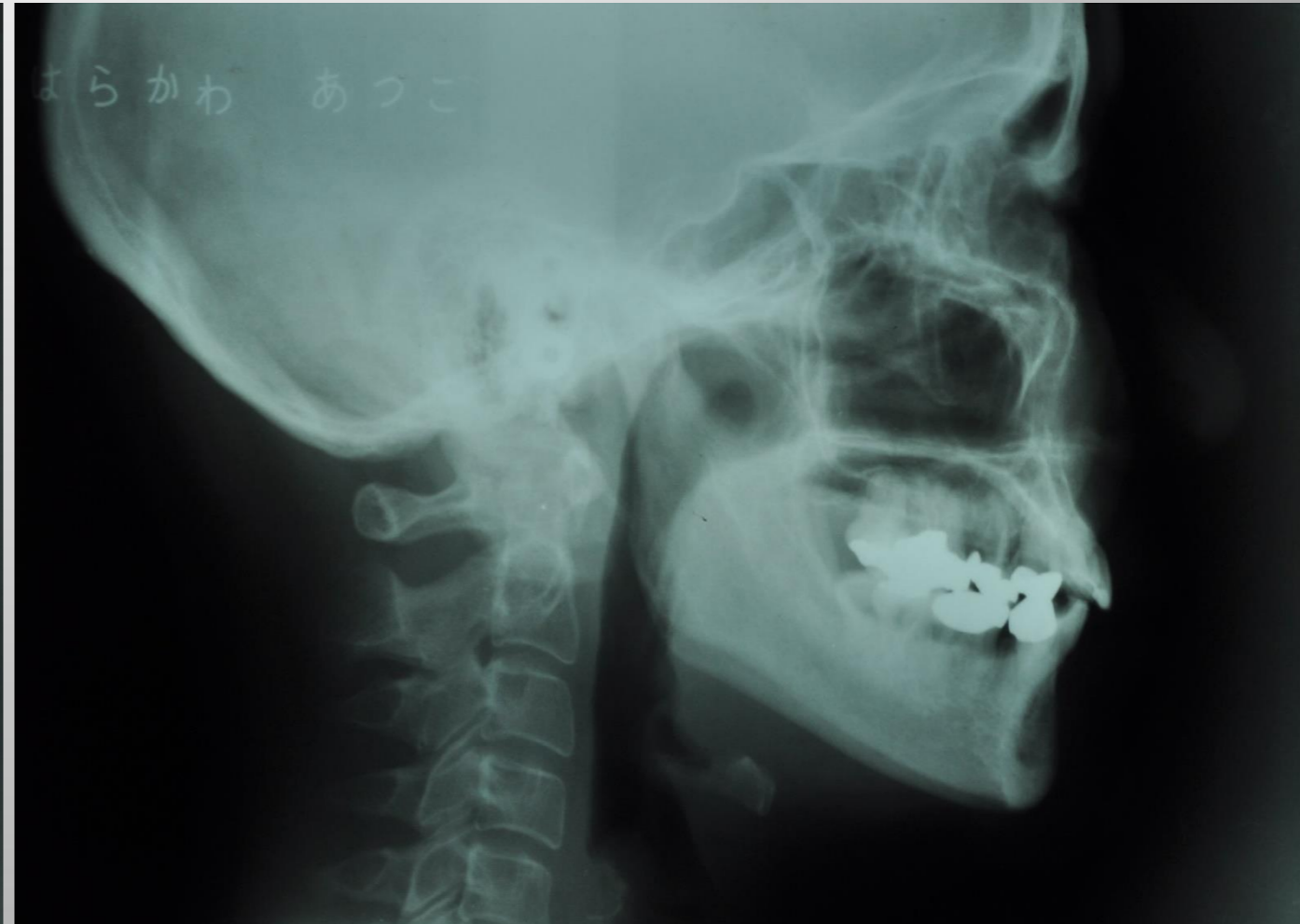

Post Treatment

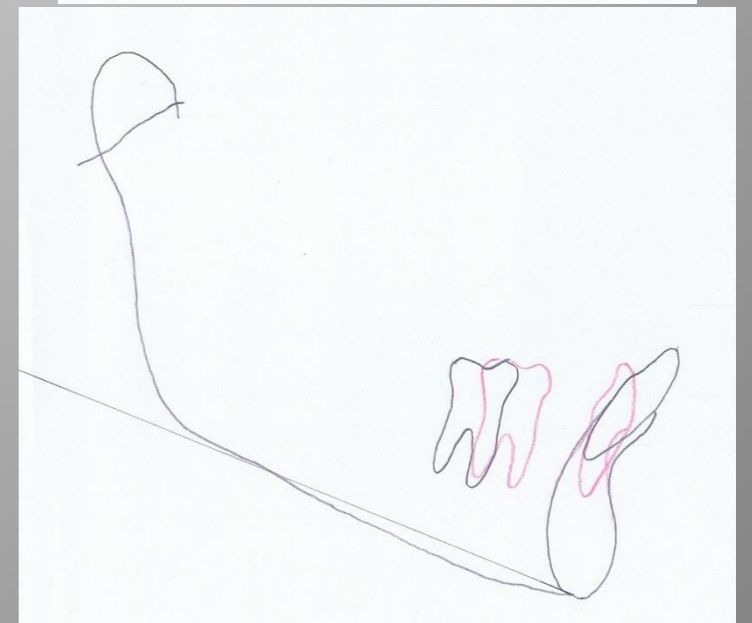
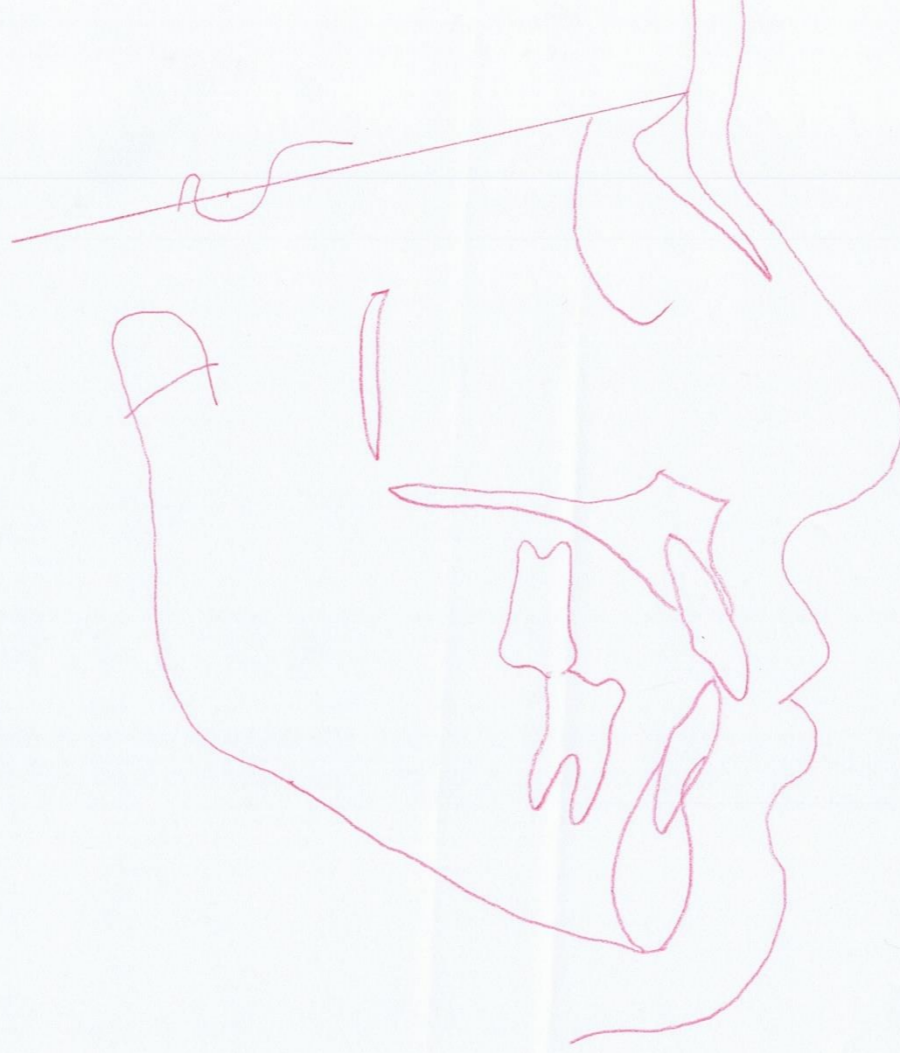
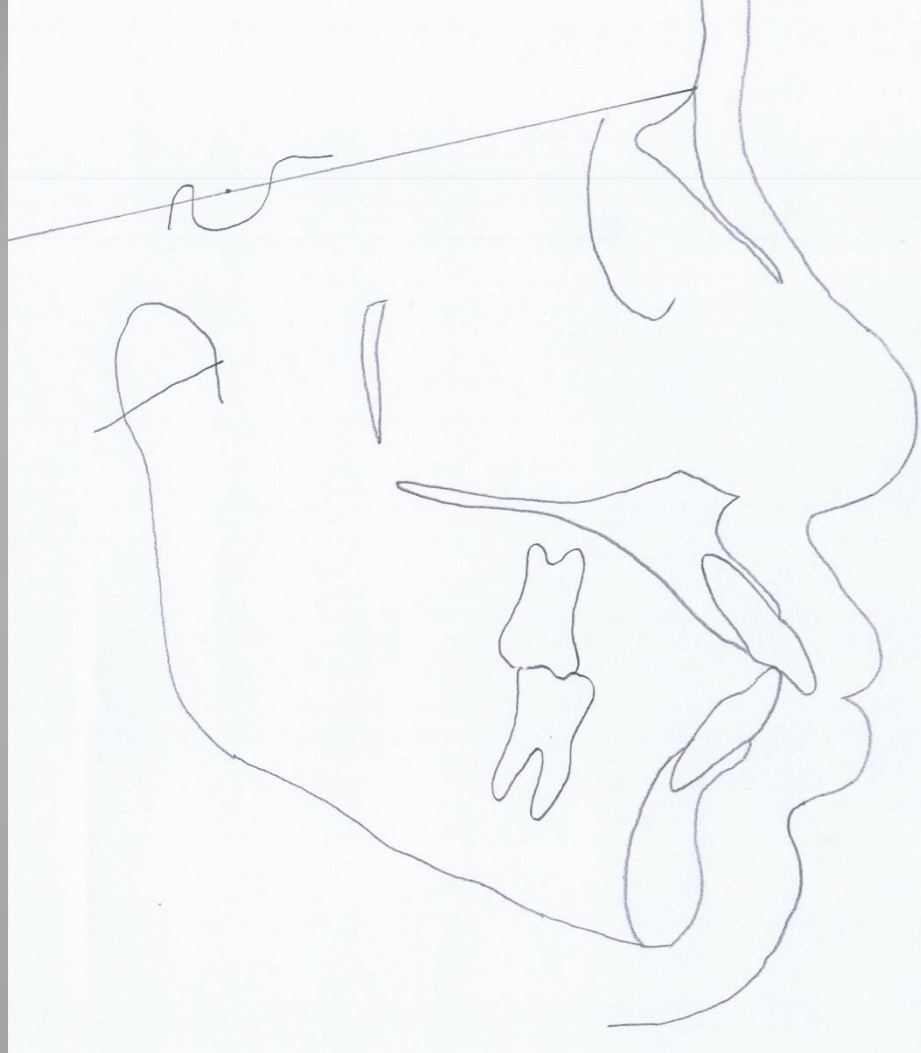
Cephalo X ray Photos



Pre Treatment



Post Treatment



Pre-treatment ———
Post-treatment ———