

Differential Diagnosis & Clinical Analysis

Angle Class I, bimaxillary protrusion

ORTHODONTIST'S NAME _____ CODE: I

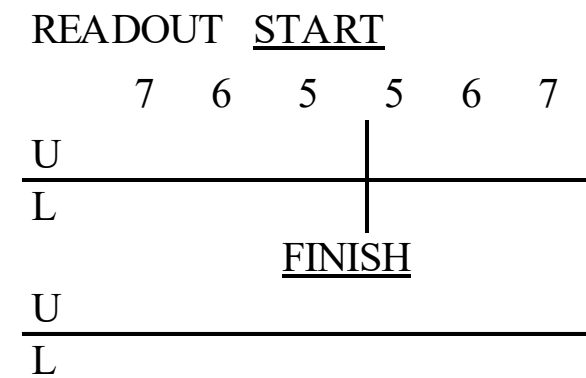
I = TWEED COURSE INSTRUCTOR, M = TWEED MEMBER, A = APPLICANT FOR MEMMBERSHIP

DIFFERENTIAL DIAGNOSIS AND CLINICAL ANALYSIS

PATIENT'S FIRST NAME: _____ INI _____ LAST NAME: _____

BEGIN TX. AGE 20 Y 7M SEX F BIRTHDAY 1989 / 3 / 7 TREATMENT TIME: 27 MONTHS

DATE					
	NORMAL	PRE-TX	PROGRESS	FINAL	POST-TX
FMIA	67	35.0		55.0	
FMA	25	25.0		26.0	
IMPA	88	120.0	180.0	99.0	
SNA	82	77.5		77.5	
SNB	80	71.0		71.0	
ANB	2	6.5	0.0	6.5	0.0
AO-BO	2mm	5.5 mm	mm	4.0 mm	mm
OCC PLANE	10	5.0		8.5	
Z ANGLE	75	51.0		70.0	
UPPER LIP		11.0 mm	mm	12.0 mm	mm
TOTAL CHIN		11.5 mm	mm	13.0 mm	mm
POST. FACIAL HT.	45mm	54.0 mm	mm	51.0 mm	mm
ANT. FACIAL HT.	65mm	76.0 mm	mm	75.5 mm	mm
FAC. HT. INDEX	0.69	0.71	#####	0.68	#####
FAC. HT. CHANGE	2:1	XXXX	/	/	/
MAND. CUSPID WIDTH		mm	mm	mm	mm
MAND. MOLAR WIDTH		mm	mm	mm	48.0 mm



DIAGNOSIS:

A. Skeletal : II

B. Dental : I

C. Perio : none

D. Facial : convex

CRANIAL FACIAL ANALYSIS

	Ceph. Value	Difficulty Factor	Difficulty
Normal Range			
FMA 22-28	25.0	5	0
ANB 1-5	6.5	15	23
Z-ANGLE 70-80	51.0	2	38
OCC. PLANE 8-12	5.0	3	9
SNB 78-82	71.0	5	35
PFH/AFH 0.65-0.75	0.71	3	0
	C.F. Difficulty Total		105

E. Habits : none
 1. Thumb Sucker
 2. Tongue Thrust
 3. Bruxism

F. Joint Health : TMD
 medical history : good

TOTAL SPACE ANALYSIS

		Difficulty Factor	Difficulty
Anterior			
Tooth Arch Disc.	3.0	1.5	4.5
Headfilm Disc.	20.0	1	20.0
Total	23.0		
Mid Arch			
Tooth Arch Disc.	2.0	1.0	2.0
Curve of Spee	1.0	1.0	1.0
Total	3.0		
Horizontal Occlusal Disharmony (Class II or Class III)	2.0	2.0	4.0
Posterior			
Tooth Arch Disc.	22.0		
(-)expected Inc.	0.0		
Total	22.0	0.5	11.0
Space Analysis Total	48.0	Space Analysis Difficulty Total	42.5

TRERATMENT PLANNING, TIMING
 EXTRACTIONS:

MAXILLARY

RIGHT 4 LEFT 4

MANDIBULAR

RIGHT 4 LEFT 4

(Please Indicate Missing Teeth)

DIFFICULTY INDEX :

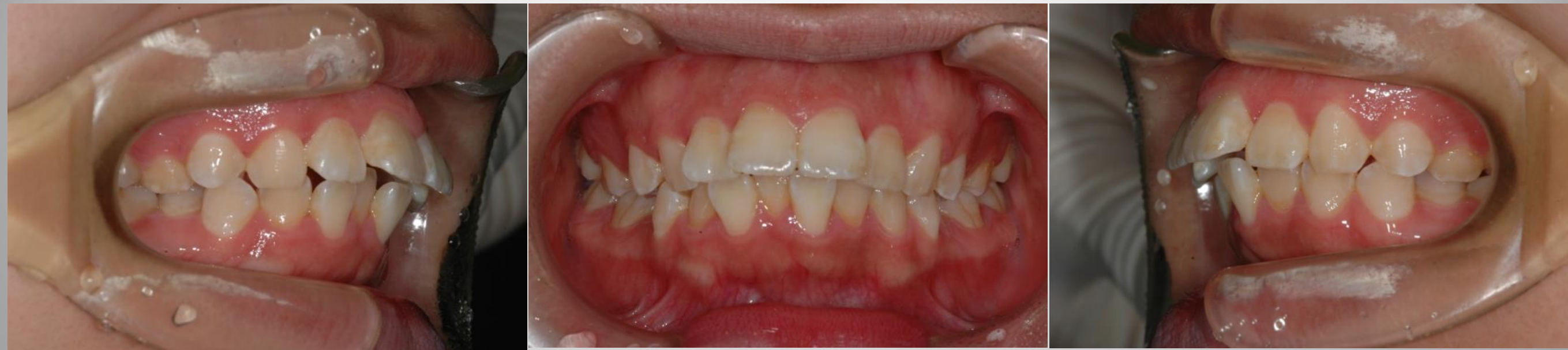Mild 0 - 60

Moderate 60 - 120

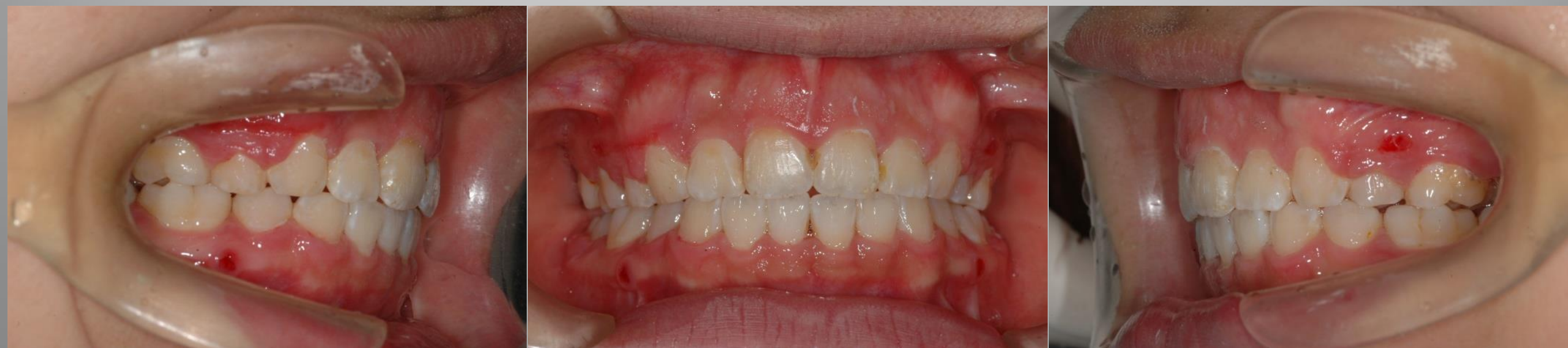Severe over 120

C.F. Difficulty Total	104.5
Space Analysisi Difficulty Total	42.5
Total Difficulty	147.0

Oral Photos

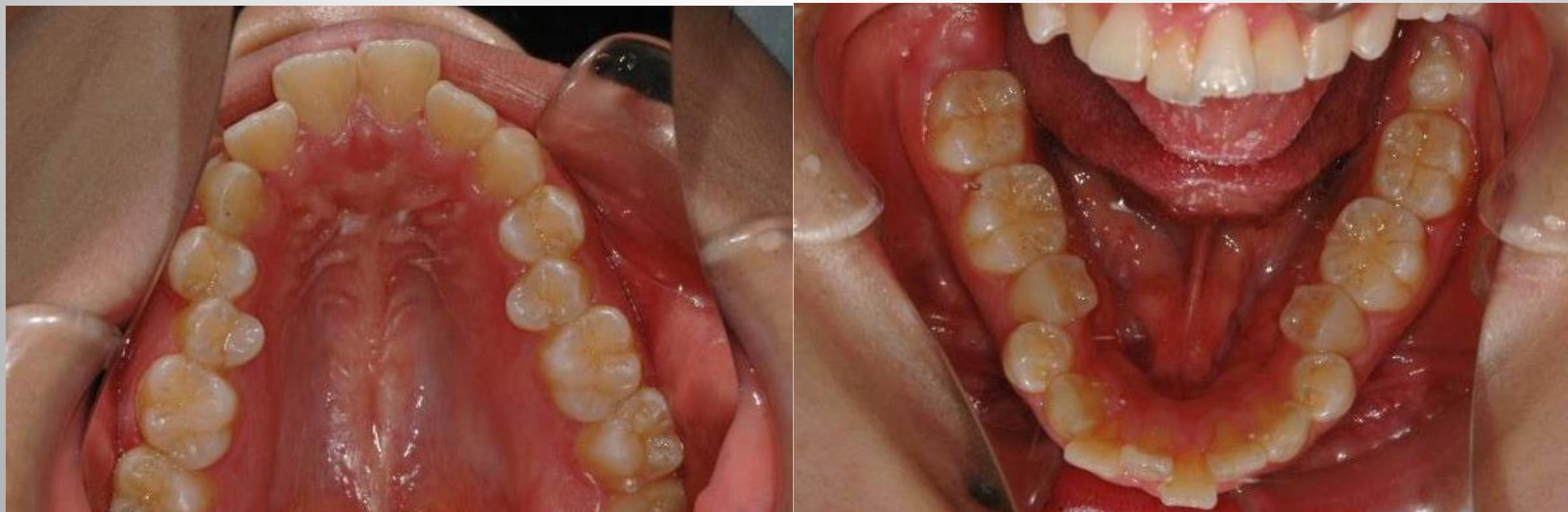

Pre Treatment

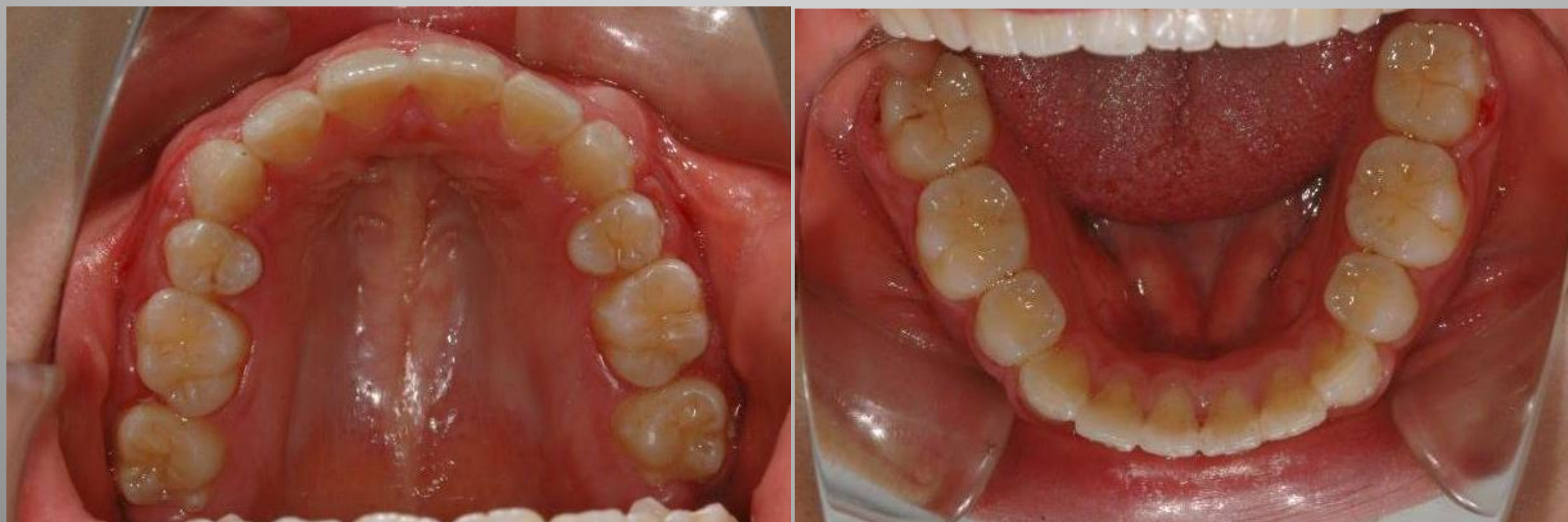

Post Treatment

Oral Photos

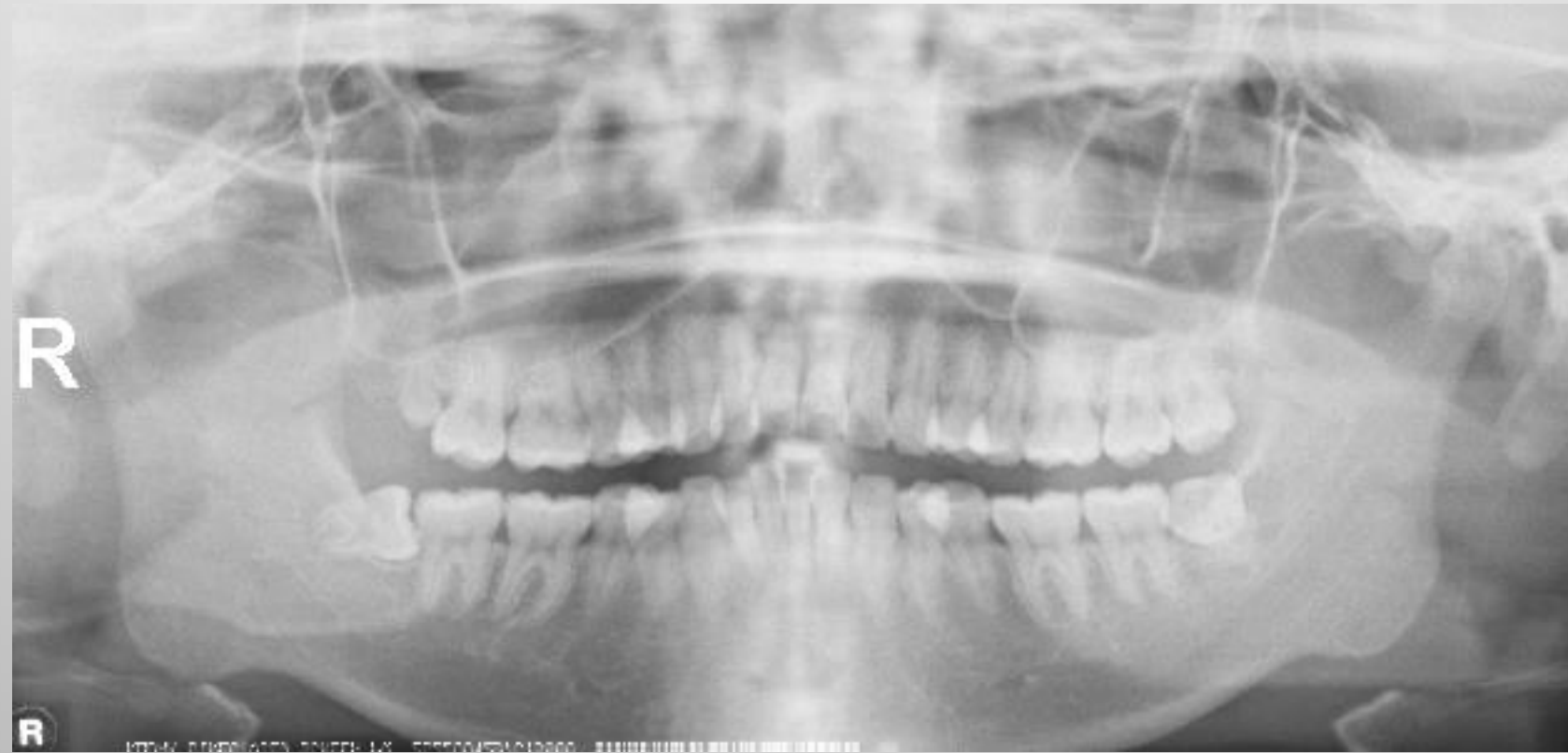

Pre Treatment

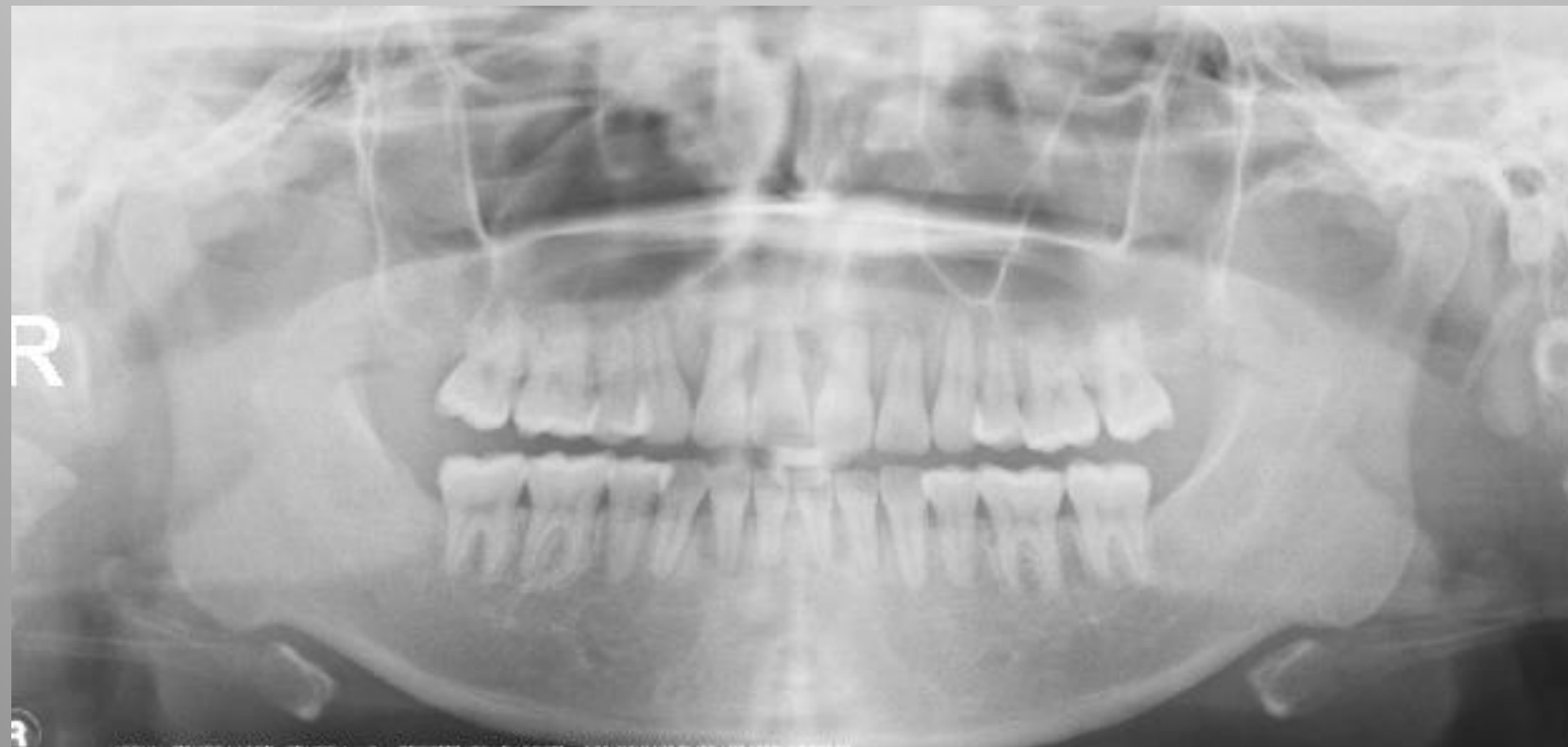

Post Treatment

Panorama X ray Photos

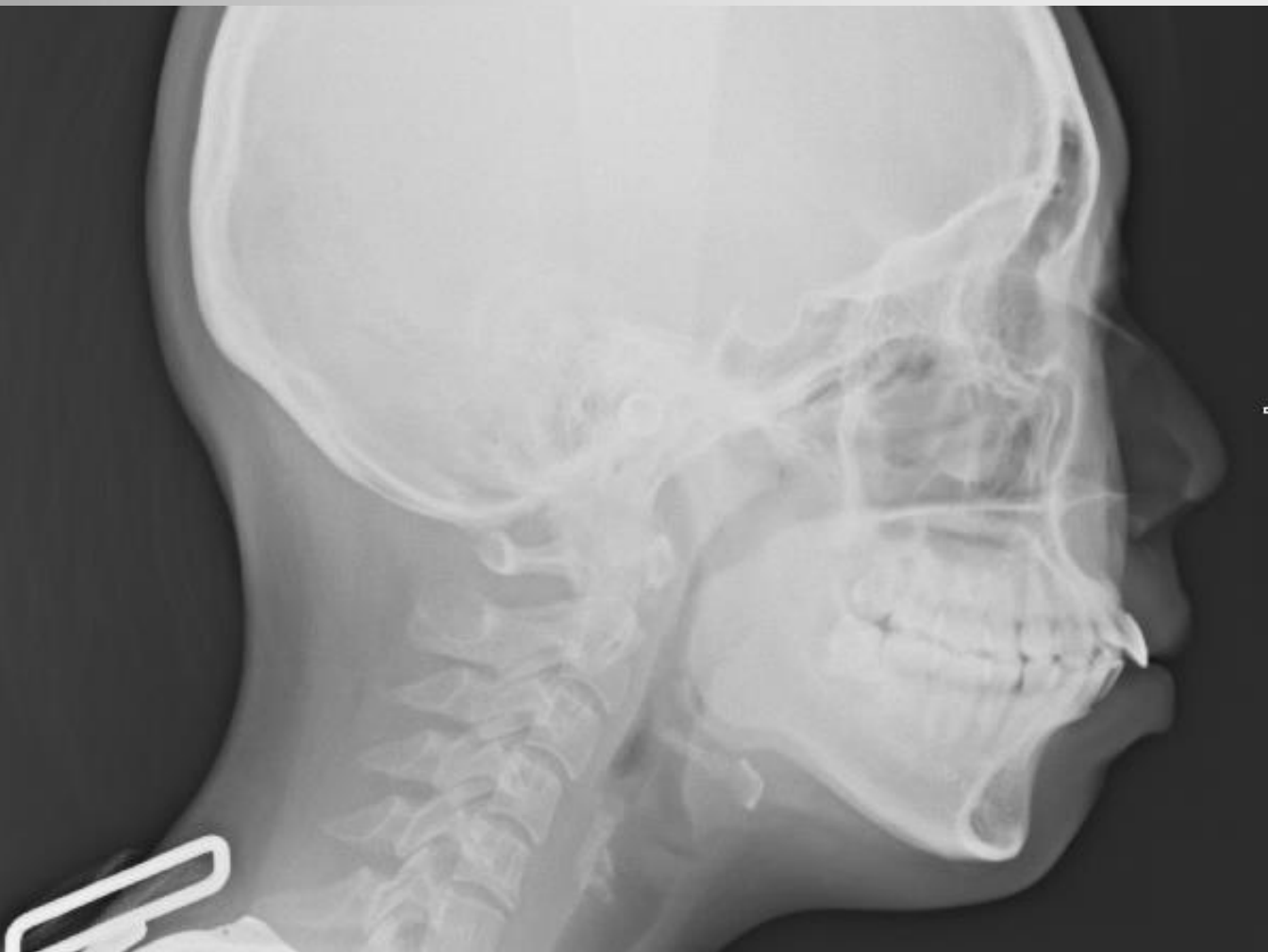

Pre Treatment

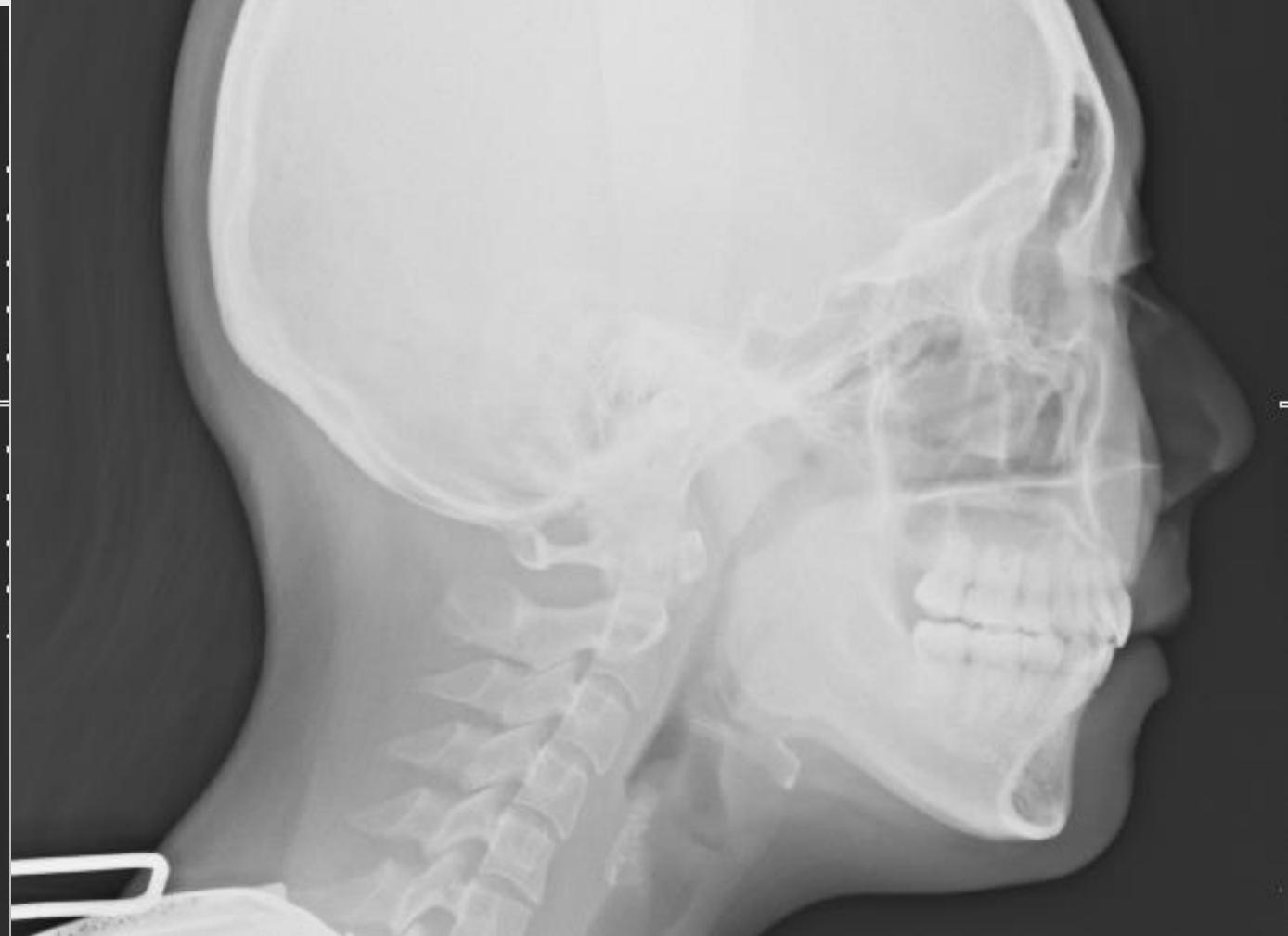

Post Treatment

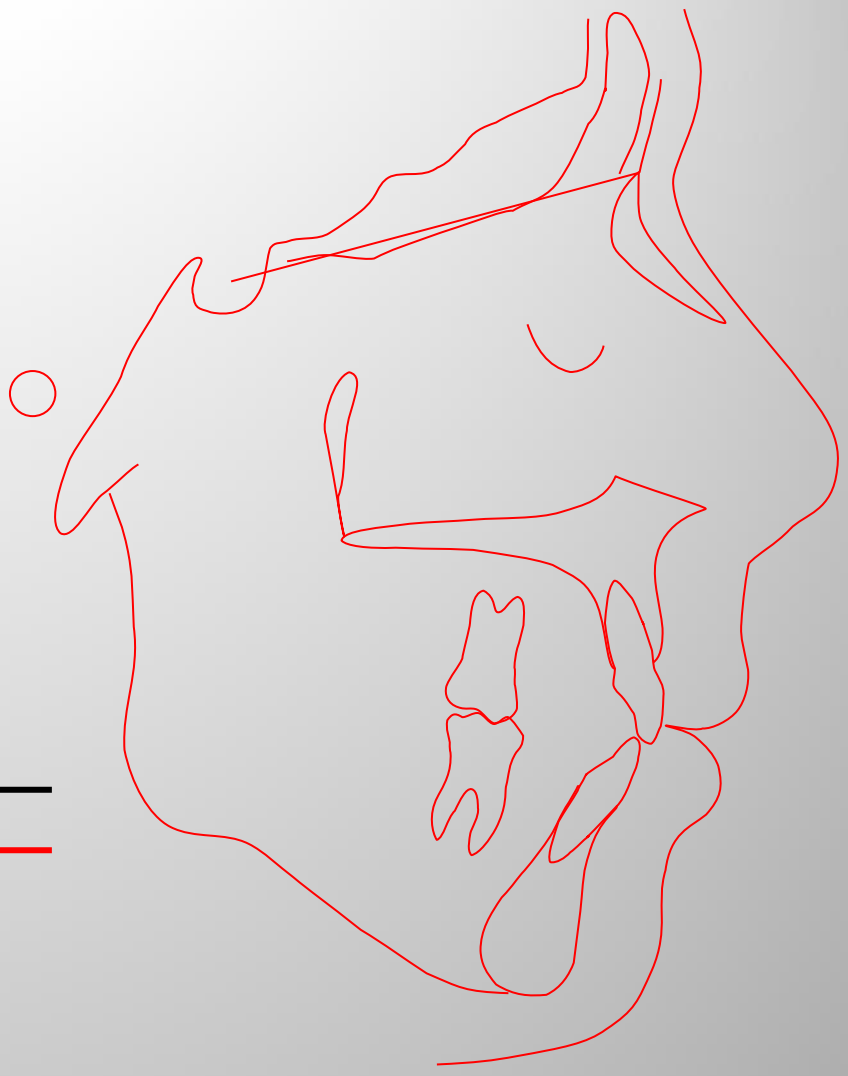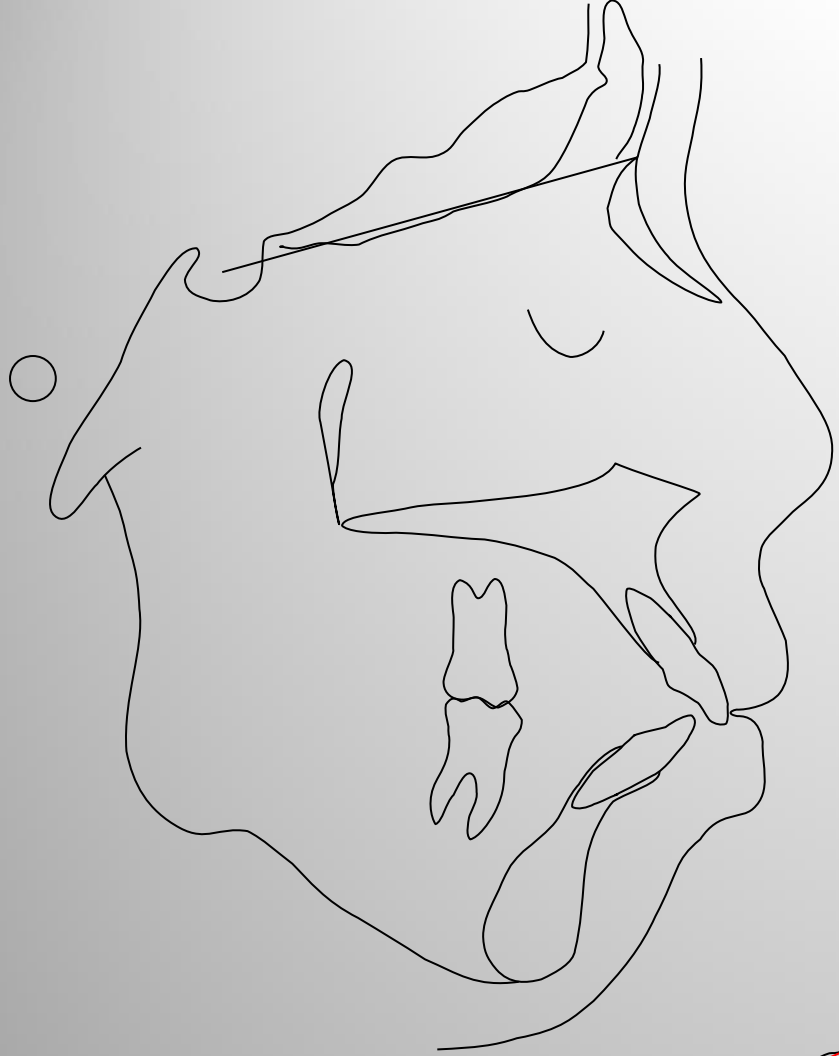
Cephalo X ray Photos



Pre Treatment



Post Treatment



Pre-treatment —
Post-treatment —

