

Angle class II div.2

ORTHODONTIST'S NAME _____

CODE : I

I = TWEED COURSE INSTRUCTOR, M = TWEED MEMBER, A = APPLICANT FOR MEMMBERSHIP

DIFFERENTIAL DIAGNOSIS AND CLINICAL ANALYSIS

PATIENT'S FIRST NAME : _____

INI

LAST NAME : _____

BEGIN TX. AGE

28 Y6M

SEX

F

BIRTHDAY

10/17/83

TREATMENT TIME :

29 MONTHS

DATE	2014/2/11		2017/2/4			READOUT	START
	NORMAL	PRE-TX	PROGRESS	FINAL	POST-TX		7 6 5 5 6 7
FMIA	67	54.0		55.0		U	10 0 0 5
FMA	25	21.0		21.0		L	-10 0 0 -5
IMPA	88	105.0		104.0			<u>FINISH</u>
SNA	82	79.5		78.0		U	10 0 0 0 10
SNB	80	72.0		72.0		L	10 0 0 0 10
ANB	2	7.5		6.0			
AO-BO	2mm	3.0 mm	mm	4.0 mm	mm		DIAGNOSIS:
OCC PLANE	10	13.0		10.0			A. Skeletal :
Z ANGLE	75	63.0		67.0			Class II
UPPER LIP		13.0 mm	mm	14.0 mm	mm		
TOTAL CHIN		11.0 mm	mm	14.0 mm	mm		B. Dental :
POST. FACIAL HT.	45mm	48.0 mm	mm	48.0 mm	mm		Class I
ANT. FACIAL HT.	65mm	61.0 mm	mm	61.0 mm	mm		
FAC. HT. INDEX	0.69	0.79		0.79			C. Perio : good
FAC. HT. CHANGE	2:1	XXXX	/	/	/		
MAND. CUSPID WIDTH		23.0 mm	mm	23.0 mm	mm		
MAND. MOLAR WIDTH		41.0 mm	mm	41.0 mm	mm		D. Facial : convex

CRANIAL FACIAL ANALYSIS

	Ceph.	Difficulty			E. Habits : no problem
Normal Range	Value	Factor	Difficulty		
FMA 22-28	21.0	5	5		
ANB 1-5	7.5	15	38		
Z-ANGLE 70-80	63.0	2	14		
OCC. PLANE 8-12	13.0	3	3		F. Joint Health : no problem
SNB 78-82	72.0	5	30		
PFH/AFH 0.65-0.75	0.79	3	12		
C.F. Difficulty Total			102		

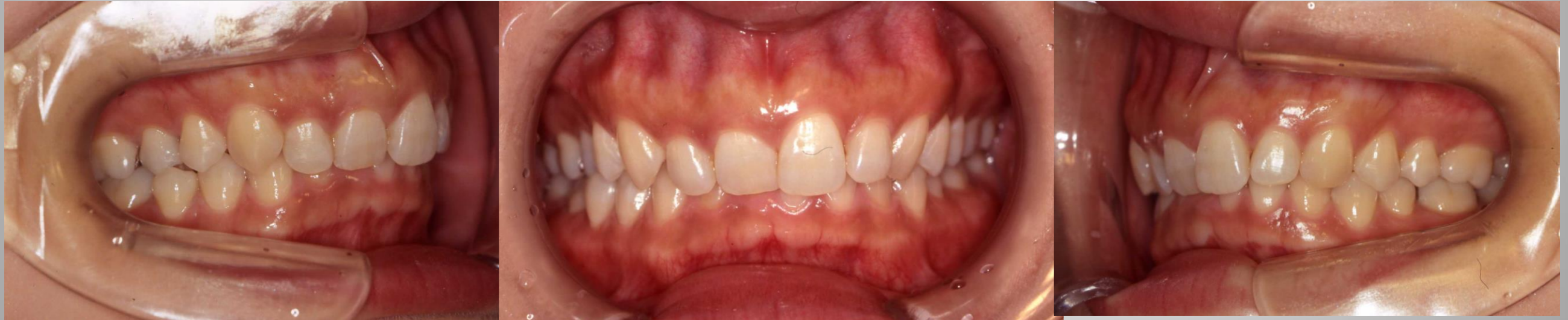TOTAL SPACE ANALYSIS

		Difficulty			
Anterior		Factor	Difficulty		TRERATMENT PLANNING, TIMING
Tooth Arch Disc.	2.0	1.5	3.0		EXTRACTIONS:
Headfilm Disc.	8.0	1	8.0		MAXILLARY
Total	10.0				RIGHT <u>84</u> LEFT <u>4</u>
					MANDIBULAR
					RIGHT <u> </u> LEFT <u>8</u>
Mid Arch					(Please Indicate Missing Teeth)
Tooth Arch Disc.	2.0	1.0	2.0		
Curve of Spee	2.5	1.0	2.5		
Total	4.5				
Horizontal Occlusal Disharmony					
(Class II or Class III)	5.0	2.0	10.0		
Posterior					
Tooth Arch Disc.	8.0				
(-)expected Inc.	0.0				
Total	8.0	0.5	4.0		
Space Analysis Total	22.5	Space Analysis	Difficulty Total	29.5	

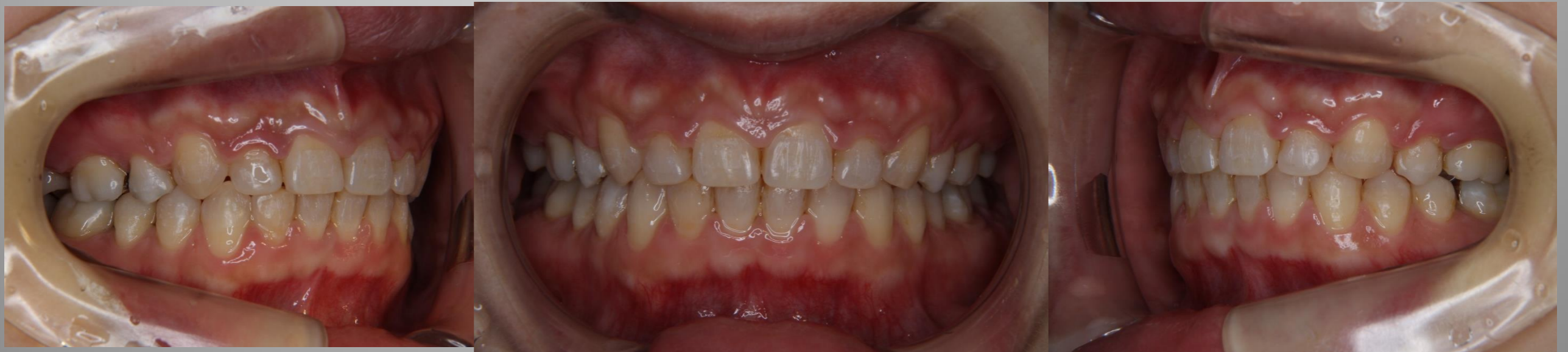DIFFICULTY INDEX :

C.F. Difficulty Total	101.5	Mild	0 - 60
Space Analysisi Difficulty Total	29.5	Moderate	60 - 120
Total Difficulty	131.0	Severe	over 120

Oral Photos

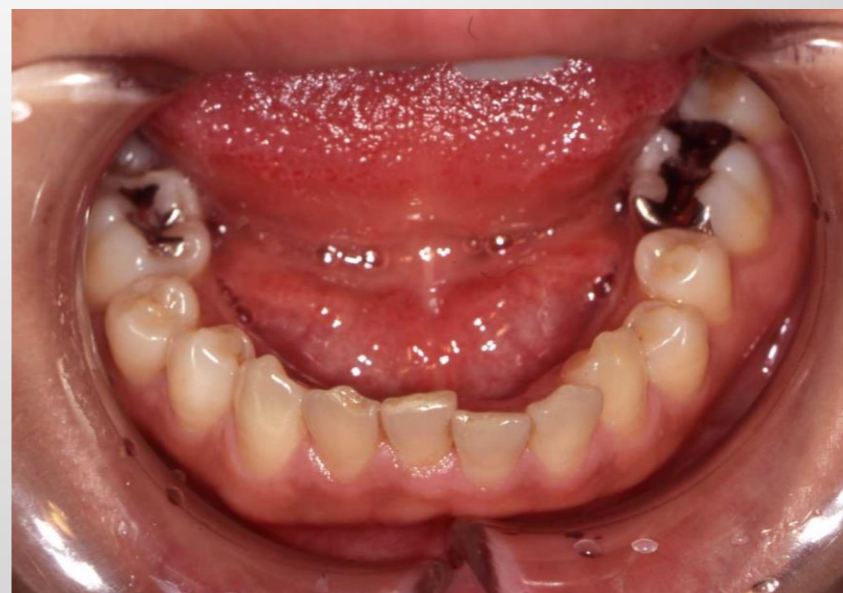
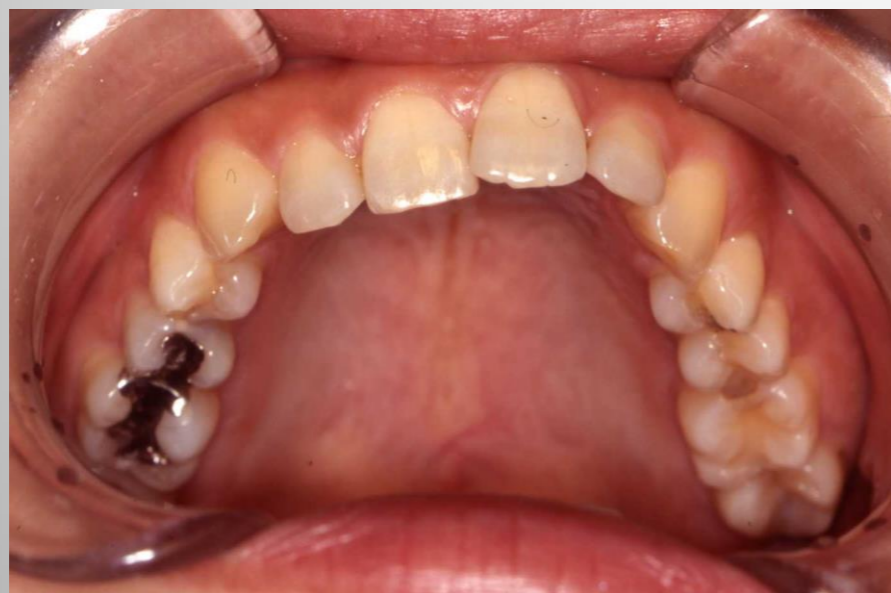
Pre Treatment

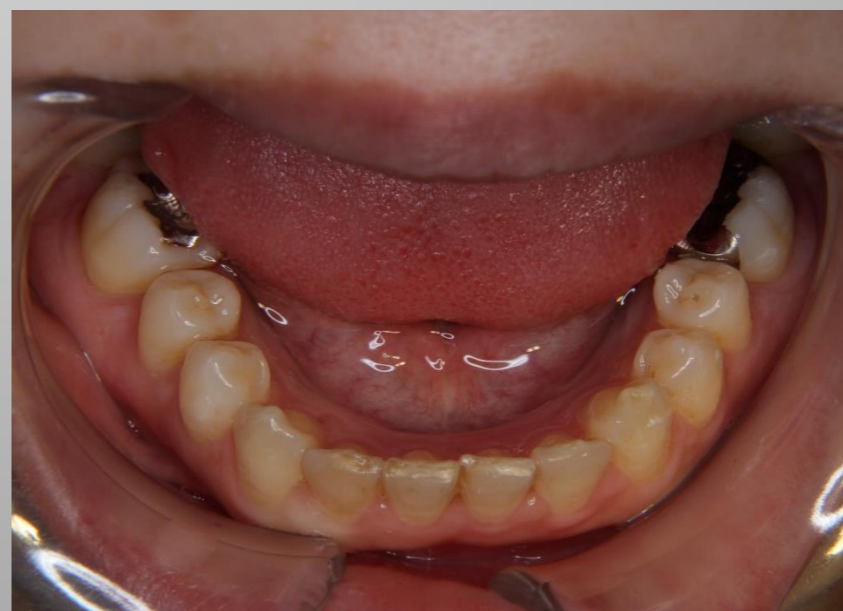
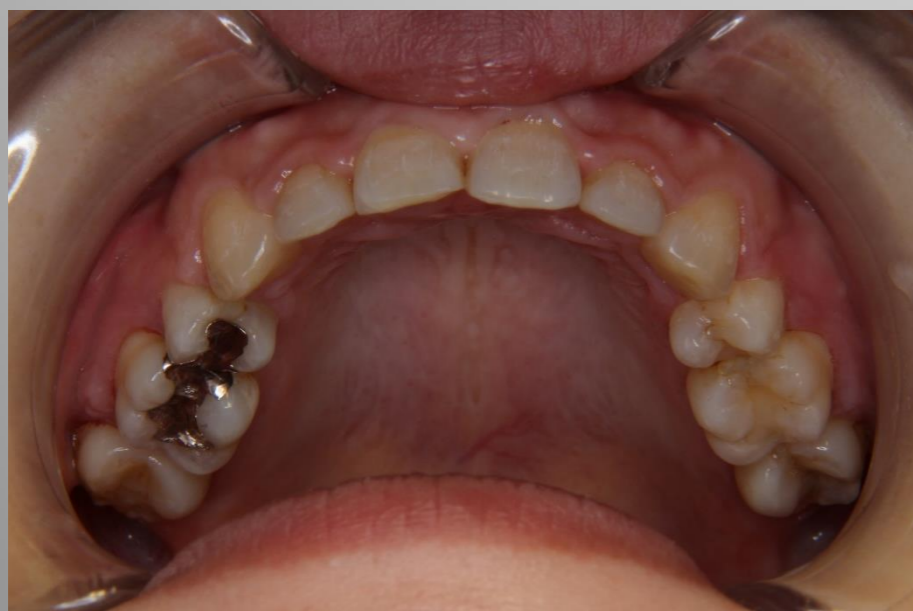
Post Treatment

Oral Photos

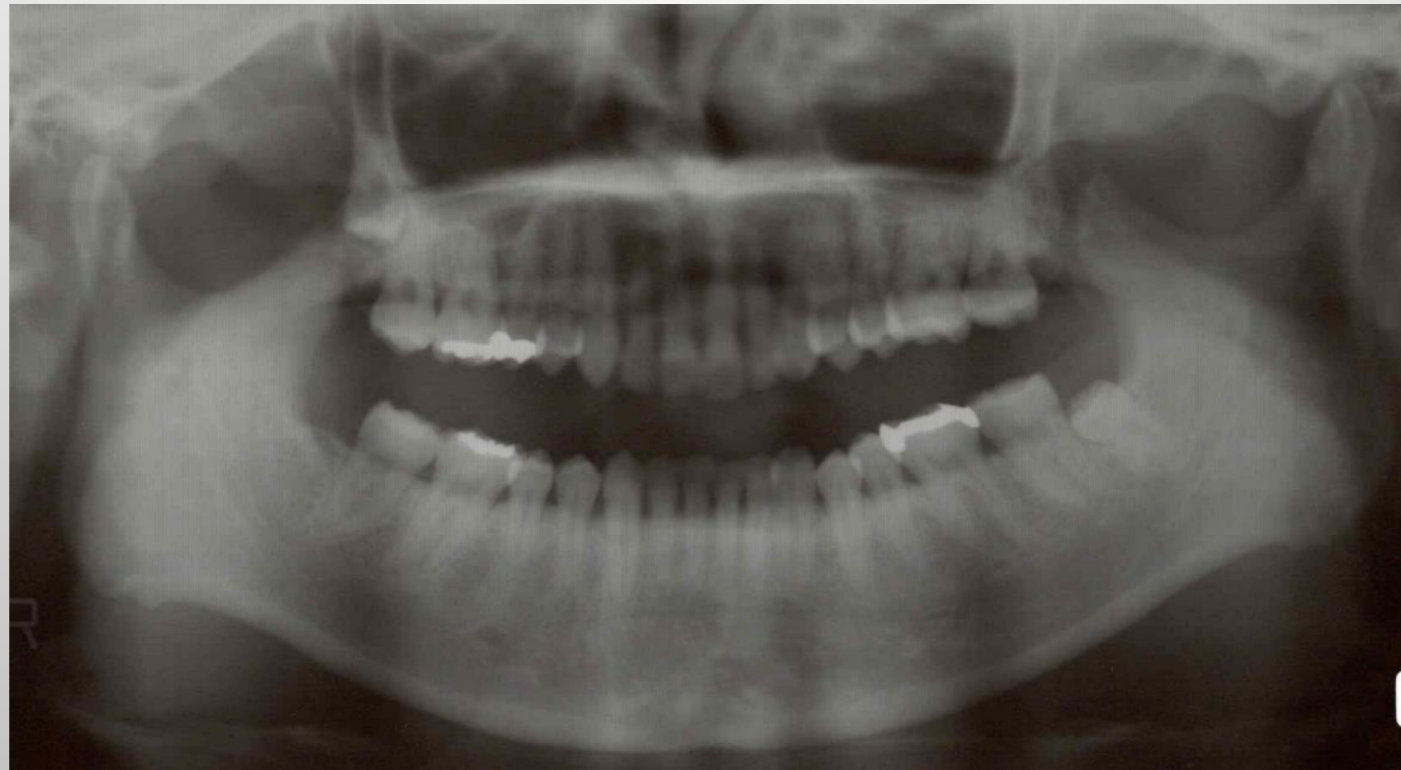

Pre Treatment

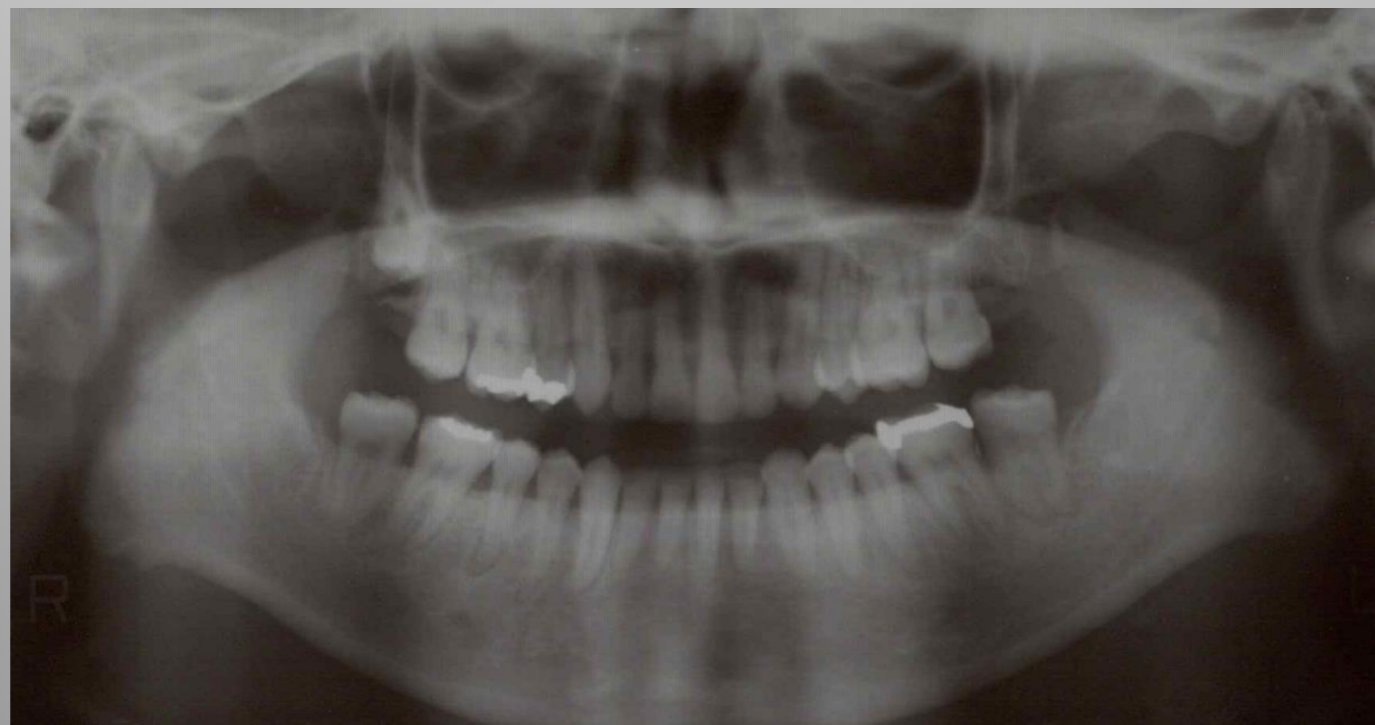


Post Treatment

Panorama X ray Photos

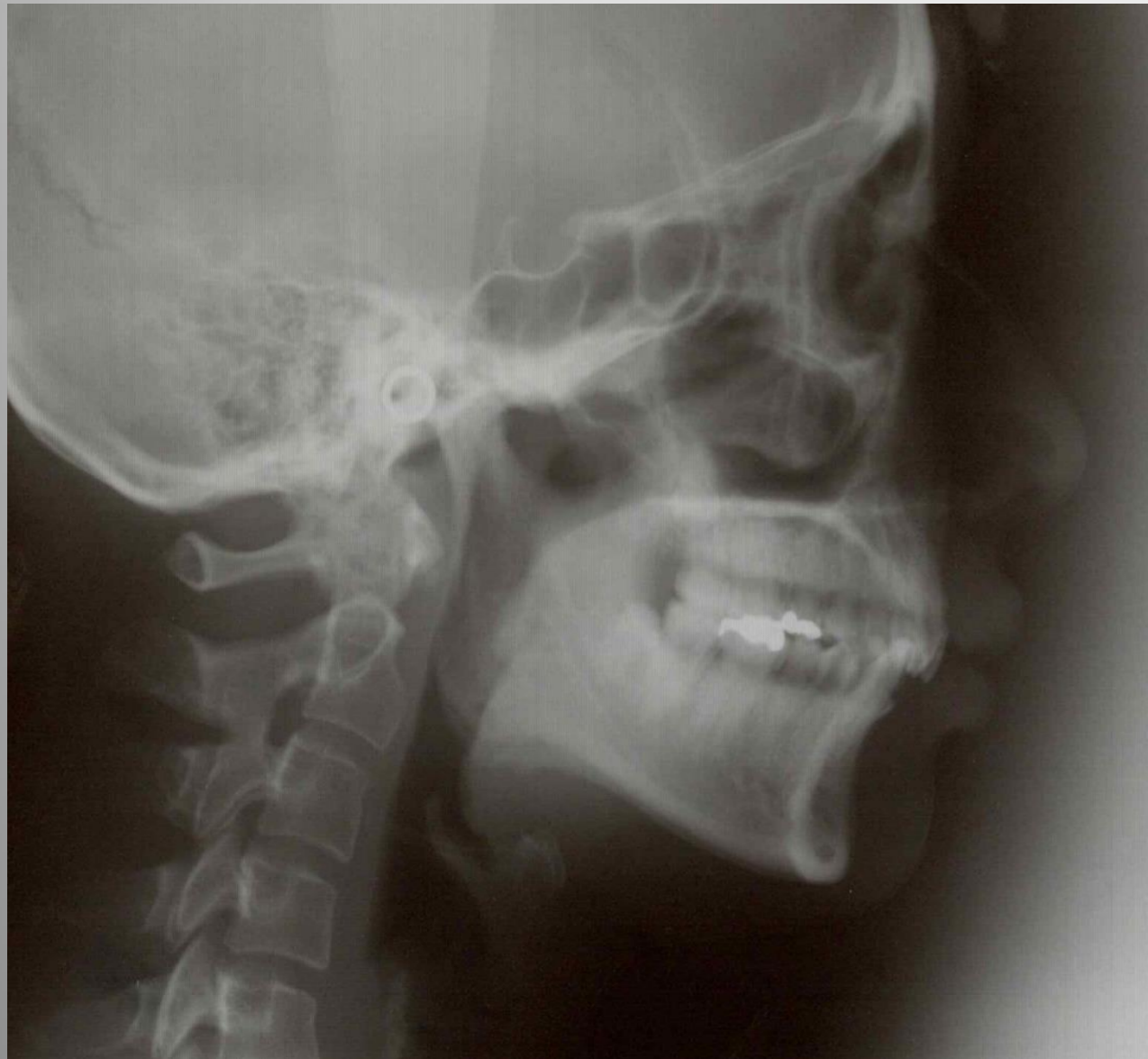

Pre Treatment

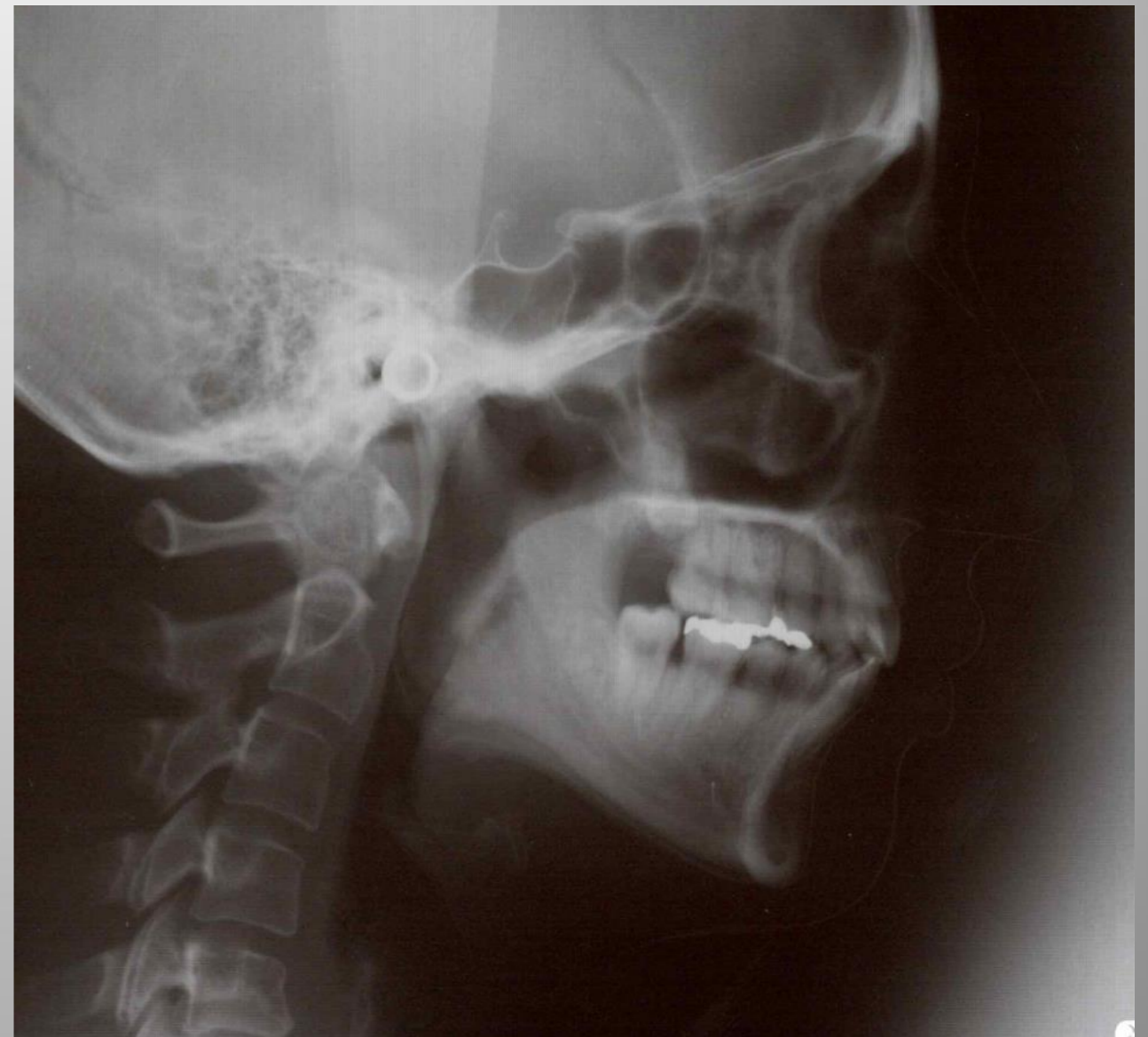

Post Treatment

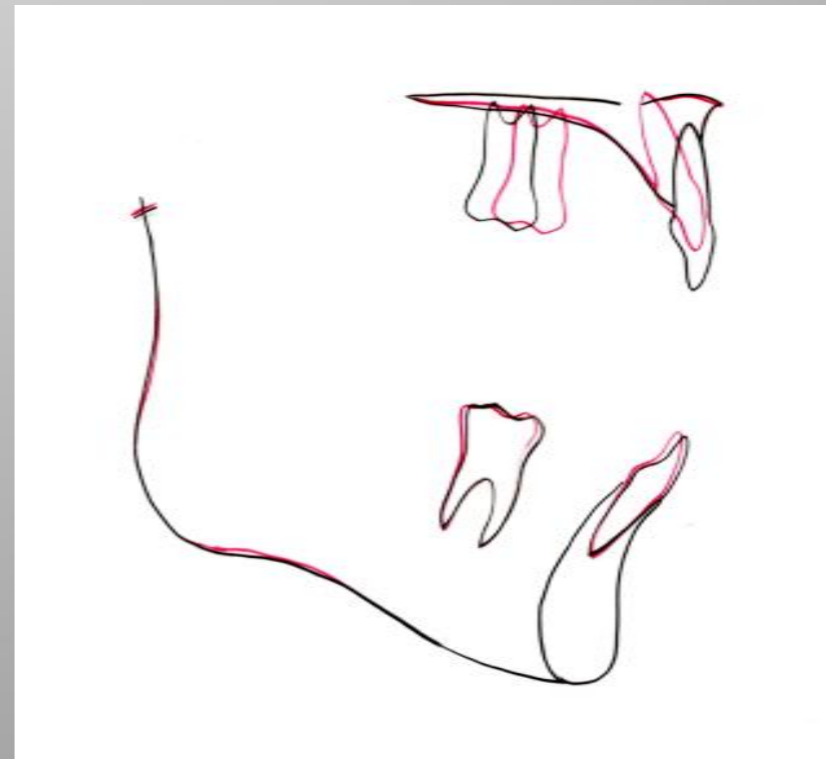
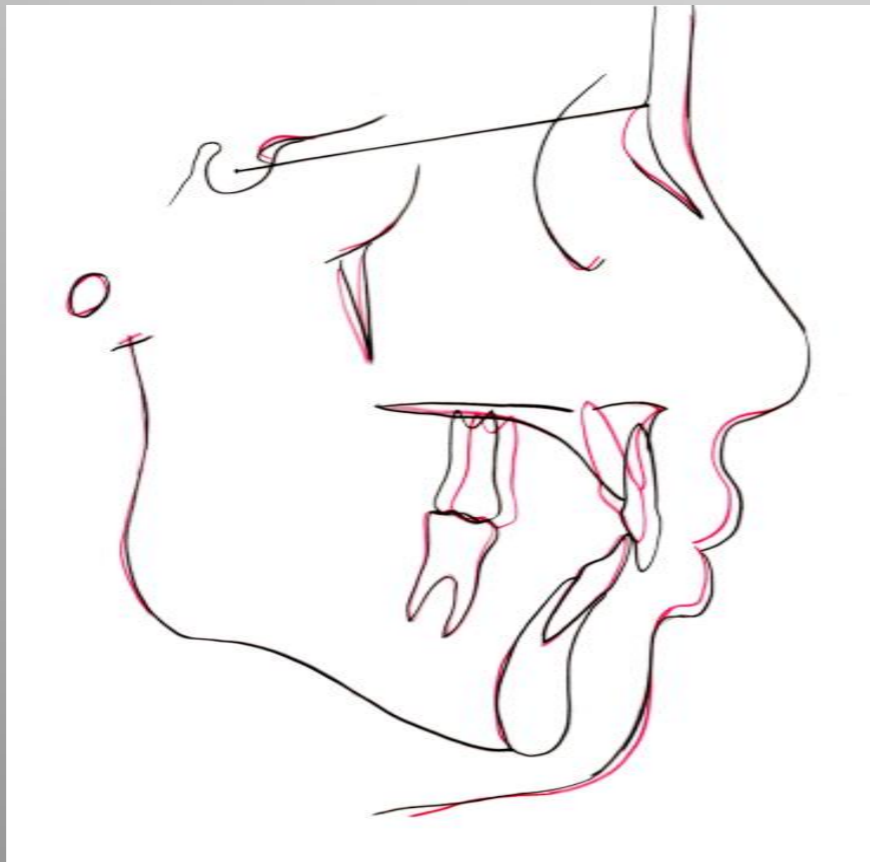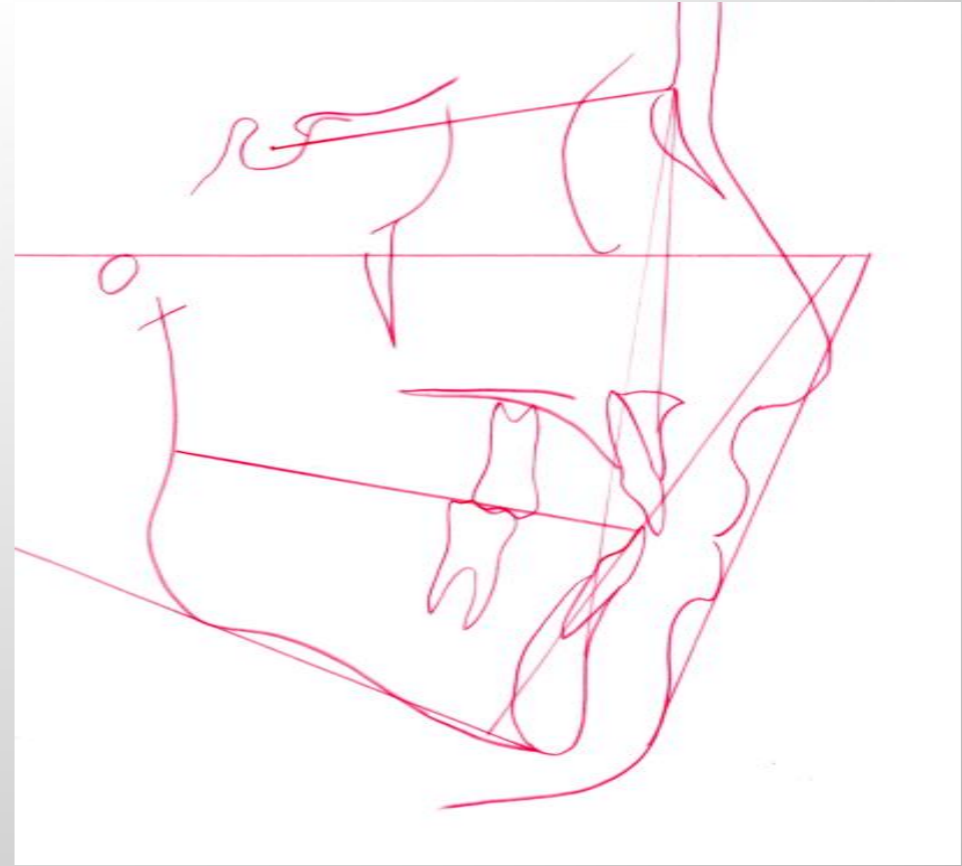
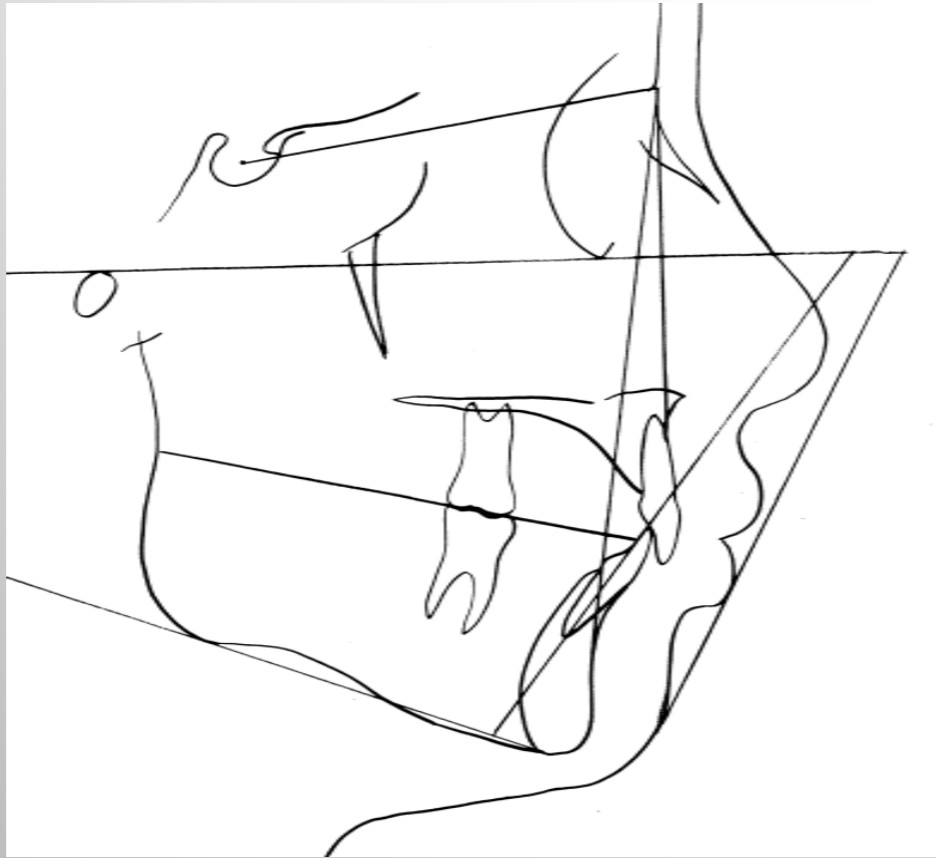Cephalo X ray Photos



Pre Treatment



Post Treatment



Pre-treatment ———
Post-treatment ———