Differential Diagnosis & Clinical Analysis

Case Title : Angle Class I High angle case

ORTHODONTIST'S NAME _____ CODE : I

I = Tweed Course Instructor, F = Fellow who is not an instructor, FA = Fellowship applicant

DIFFERENTIAL DIAGNOSIS AND CLINICAL ANALYSIS

PATIENT'S FIRST NAME : _____ INI M.O LAST NAME : _____

BEGIN TX. AGE 26 Y 09 M SEX F BIRTHDAY June / 18 /1989 TREATMENT TIME : 29 MONTHS

DATE		2016/3/26				2018/11/19				
	NORMAL	PRE-TX		PROGRESS		FINAL		POST-TX		
FMIA	67	54.0				60.0				
FMA	25	30.0				29.0				
IMPA	88	96.0		180.0		91.0		###		
SNA	82	74.0				73.0				
SNB	80	71.0				69.5				
ANB	2	3.0		0.0		3.5		0.0		
AO-BO	2mm	2.0	mm		mm	3.0	mm		mm	
OCC PLANE	10	13.0				14.3				
Z ANGLE	75	61.0				72.0				
UPPER LIP		10.5	mm		mm	12.0	mm		mm	
TOTAL CHIN		10.0	mm		mm	12.0	mm		mm	
POST. FACIAL HT.	45mm	42.5	mm		mm	43.5	mm		mm	
ANT. FACIAL HT.	65mm	63.5	mm		mm	64.0	mm		mm	
FAC. HT. INDEX	0.69	0.67		###		0.68		###		
FAC. HT. CHANGE	2:1	XXXX		/				/		
MAND. CUSPID WIDTH		27.5	mm		mm	26.3	mm		mm	
MAND. MOLAR WIDTH		46.7	mm		mm	39.6	mm		mm	

Japanese Tweed Orthodontic Association

CRANIAL FACIAL ANALYSIS

Normal Range	Ceph. Value	Difficulty Factor	Difficulty
FMA 22-28	30.0	5	10
ANB 1-5	3.0	15	0
Z-ANGLE 70-80	61.0	2	18
OCC. PLANE 8-12	13.0	3	3
SNB 78-82	71.0	5	35
PFH/AFH **0.65-0.75**	0.67	3	0
	C.F. Difficulty Total		66

READOUT START

7 6 5 5 6 7

U

L

FINISH

U

L

TOTAL SPACE ANALYSIS

		Difficulty Factor	Difficulty
Anterior			
Tooth Arch Disc.	3.0	1.5	4.5
Headfilm Disc.	8.8	1	8.8
Total	11.8		
Mid Arch			
Tooth Arch Disc.	2.0	1.0	2.0
Curve of Spee	1.0	1.0	1.0
Total	3.0		
Horizontal Occlusal Disharmony			
(Class Ⅱ or Class Ⅲ	0.0	2.0	0.0
Posterior			
Tooth Arch Disc.	8.0		
(-)expected Inc.	0.0		
Total	8.0	0.5	4.0
Space Analysis Total		**Space Analysis**	
	22.8	**Difficulty Total**	20.3
C.F. Difficulty Total		66.0	
Space Analysisi Difficulty Total		20.3	
Total Difficulty		86.3	

DIAGNOSIS:

A. Skeletal :
Class I

B. Dental :
Class I

C. Perio :
Nothing Particular

D. Facial :
Convex

E. Habits :
Nothing Particular

F. Joint Health :
Nothing Particular

RIGHT 4 LEFT 4

RIGHT 8 4 LEFT 4

(Please Indicate Missing Teeth)

DIFFICULTY INDEX :

Mild	0 - 60
Moderate	60 - 120
Severe	over 120

Japanese Tweed Orthodontic Association

Oral Photos

Pre Treatment

Post Treatment

Oral Photos

Pre Treatment

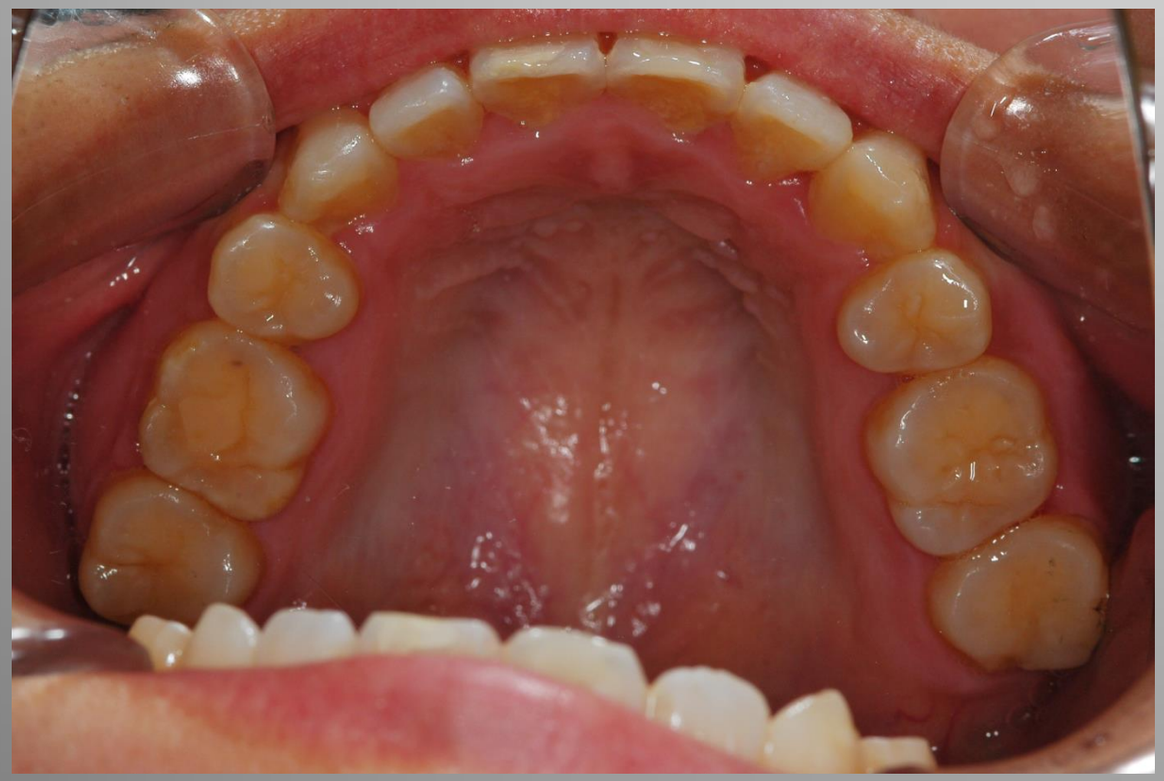

Post Treatment

Japanese Tweed Orthodontic Association

Panorama X ray Photos

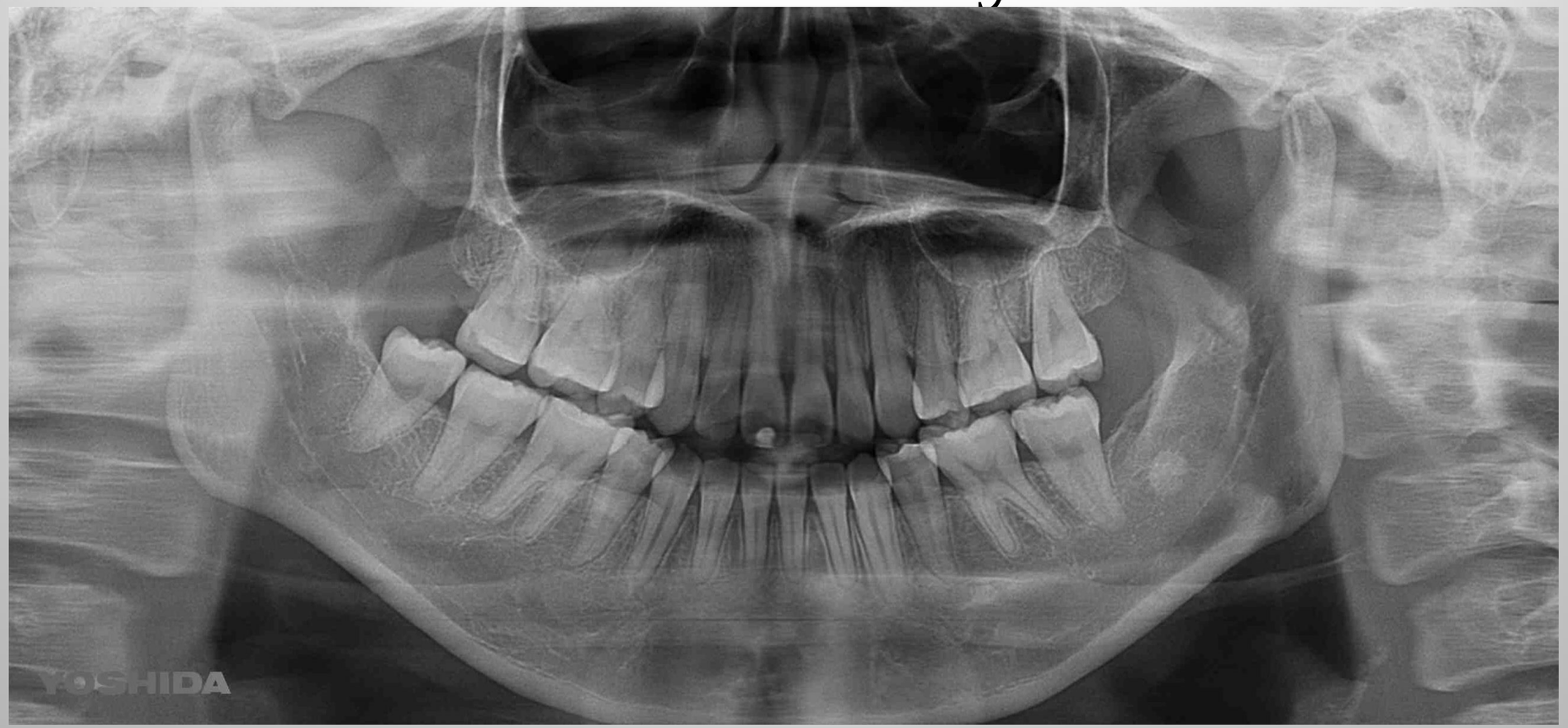

Pre Treatment

Post Treatment

Japanese Tweed Orthodontic Association

Cephalo X ray Photos

Pre Treatment

Post Treatment

Pre-treatment

Post-treatment

Japanese Tweed Orthodontic Association

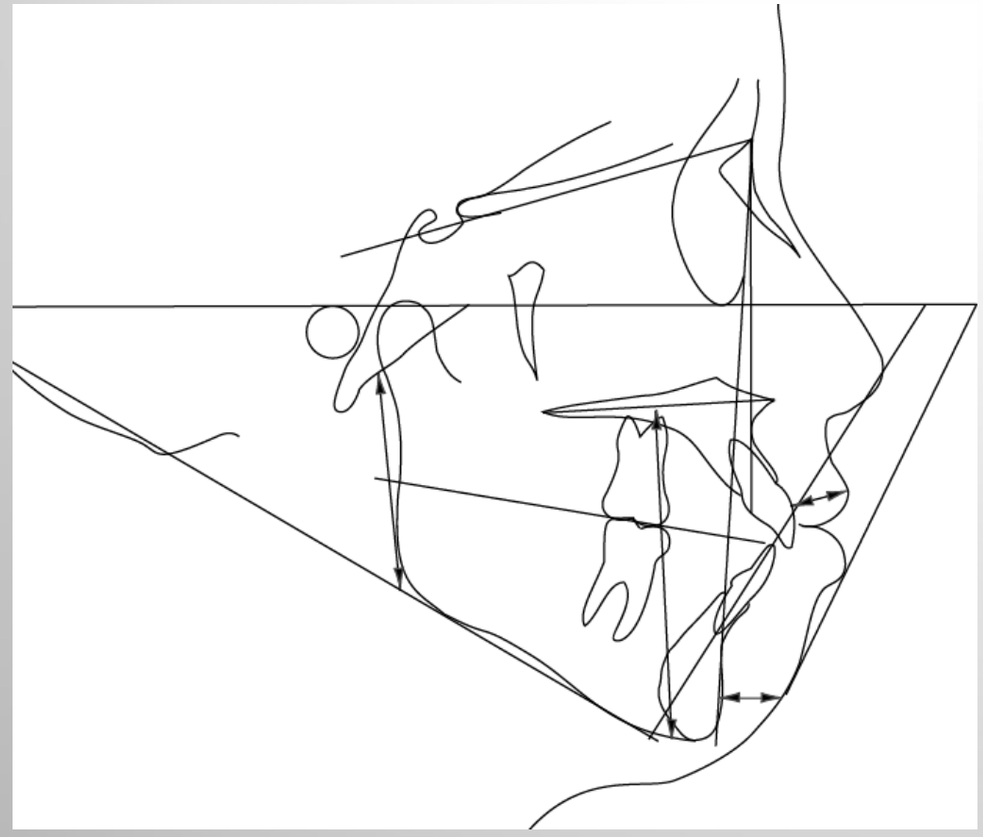

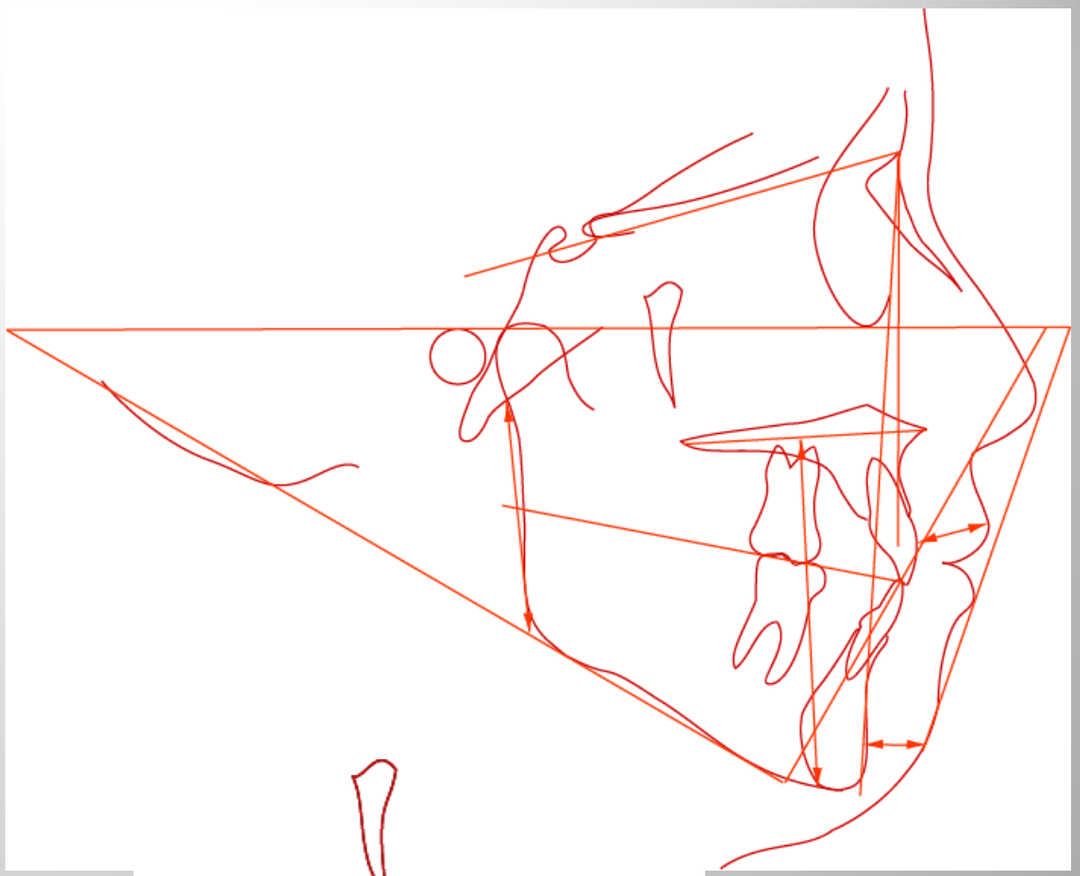

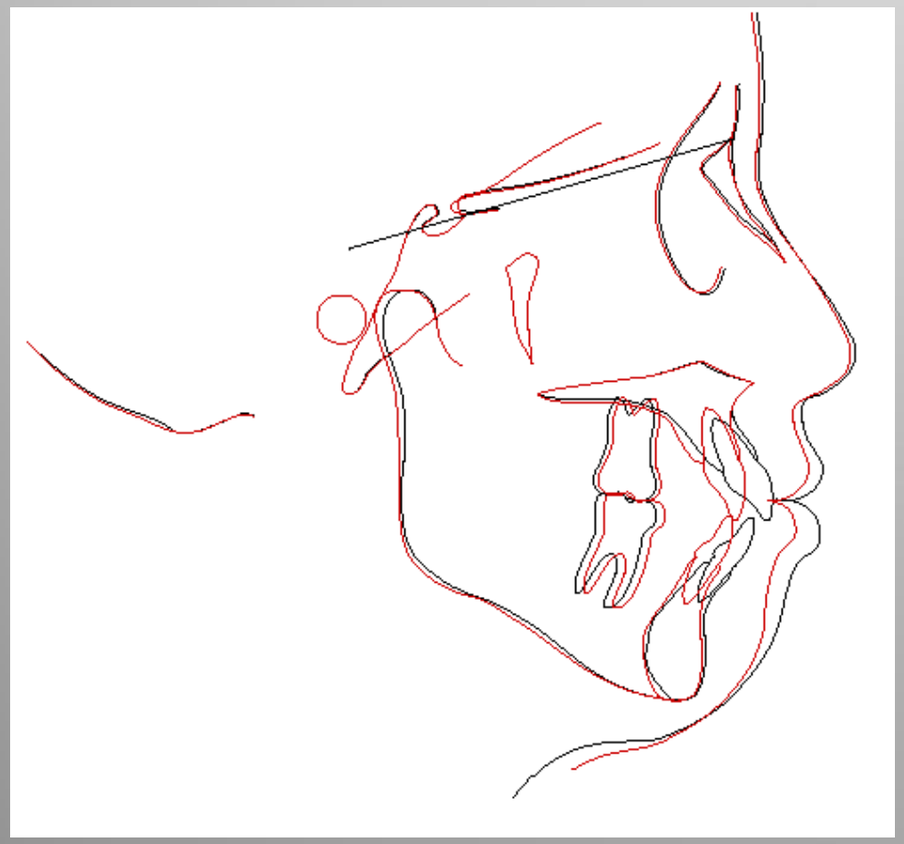

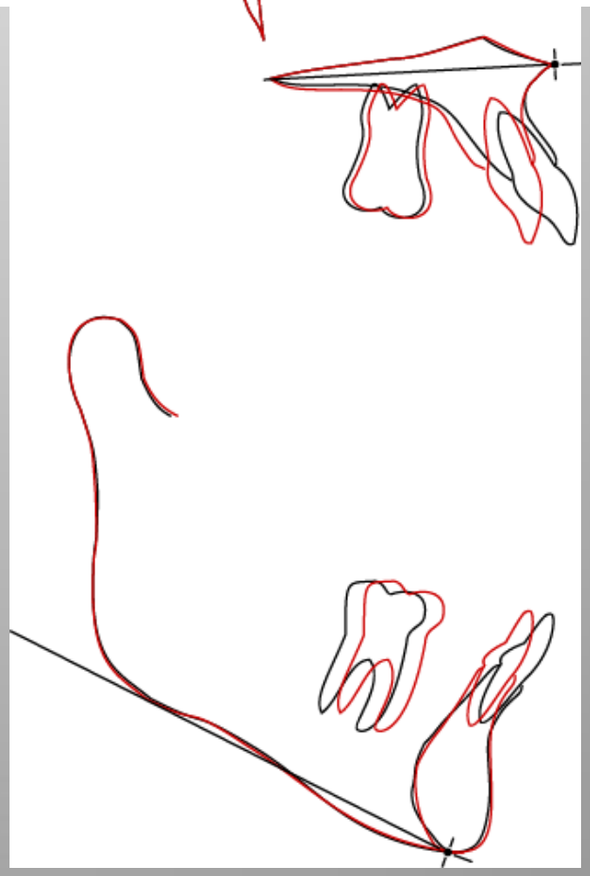

Pre-treatment

Post-treatment