

Differential Diagnosis & Clinical Analysis

Angle Class II Bimaxillary Protrusion

ORTHODONTIST'S NAME _____

CODE : I

I = TWEED COURSE INSTRUCTOR, M = TWEED MEMBER, A = APPLICANT FOR MEMMBERSHIP

DIFFERENTIAL DIAGNOSIS AND CLINICAL ANALYSIS

PATIENT'S FIRST NAME : _____ INI _____ LAST NAME : _____

BEGIN TX. AGE 17 Y 10 M SEX F BIRTHDAY 1994 / 4 / 11 TREATMENT TIME : 35 MONTHS

DATE	NORMAL	PRE-TX	PROGRESS	FINAL	POST-TX
FMIA	67	49.0		62.0	
FMA	25	40.0		41.0	
IMPA	88	91.0	180.0	77.0	180.0
SNA	82	85.0		85.0	
SNB	80	80.0		80.0	
ANB	2	5.0	0.0	5.0	0.0
AO-BO	2mm	-2.5 mm	mm	-1.5 mm	mm
OCC PLANE	10	20.0		20.0	
Z ANGLE	75	47.0		68.0	
UPPER LIP		10.0 mm	mm	11.0 mm	mm
TOTAL CHIN		17.0 mm	mm	13.0 mm	mm
POST. FACIAL HT.	45mm	48.0 mm	mm	50.0 mm	mm
ANT. FACIAL HT.	65mm	68.0 mm	mm	70.0 mm	mm
FAC. HT. INDEX	0.69	0.71	#####	0.71	#####
FAC. HT. CHANGE	2:1	XXXX	/	/	/
MAND. CUSPID WIDTH		23.0 mm	mm	27.5 mm	mm
MAND. MOLAR WIDTH		51.0 mm	mm	47.5 mm	mm

READOUT	START
U	7 6 5 5 6 7
L	
	FINISH
U	
L	

DIAGNOSIS:
 A. Skeletal :
 ClassII
 B. Dental :
 ClassII subdivision
 Bimaxillary protrusion
 C. Perio :
 N.P.
 D. Facial : convex

CRANIAL FACIAL ANALYSIS

Normal Range	Ceph. Value	Difficulty Factor	Difficulty
FMA 22-28	40.0	5	60
ANB 1-5	5.0	15	0
Z-ANGLE 70-80	47.0	2	46
OCC. PLANE 8-12	20.0	3	24
SNB 78-82	80.0	5	0
PFH/AFH 0.65-0.75	0.71	3	0
C.F. Difficulty Total			130

E. Habits :

1. Thumb Sucker
2. Tongue Thrust
3. Bruxism

F. Joint Health :

TOTAL SPACE ANALYSIS

Anterior		Difficulty Factor	Difficulty
Tooth Arch Disc.	3.5	1.5	5.3
Headfilm Disc.	12.8	1	12.8
Total	16.3		
Mid Arch			
Tooth Arch Disc.	2.5	1.0	2.5
Curve of Spee	0.5	1.0	0.5
Total	3.0		
Horizontal Occlusal Disharmony (ClassII or ClassIII)		2.0	0.0
Posterior			
Tooth Arch Disc.	0.0		
(-)expected Inc.	0.0		
Total	0.0	0.5	0.0
Space Analysis Total	19.3	Space Analysis Difficulty Total	21.1
C.F. Difficulty Total	130.0		
Space Analysis Difficulty Total	21.1		
Total Difficulty	151.1		

TRERATMENT PLANNING, TIMING

EXTRACTIONS:

MAXILLARY

RIGHT 4 LEFT 4

MANDIBULAR

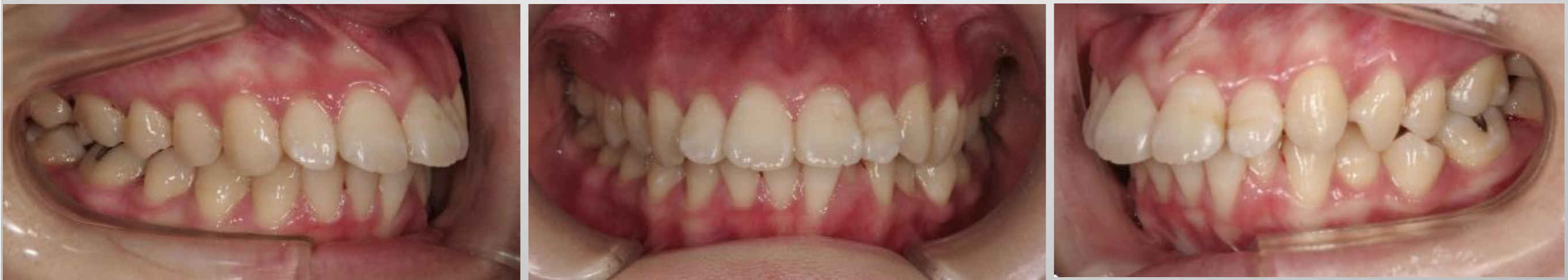RIGHT 4 LEFT 4

(Please Indicate Missing Teeth)

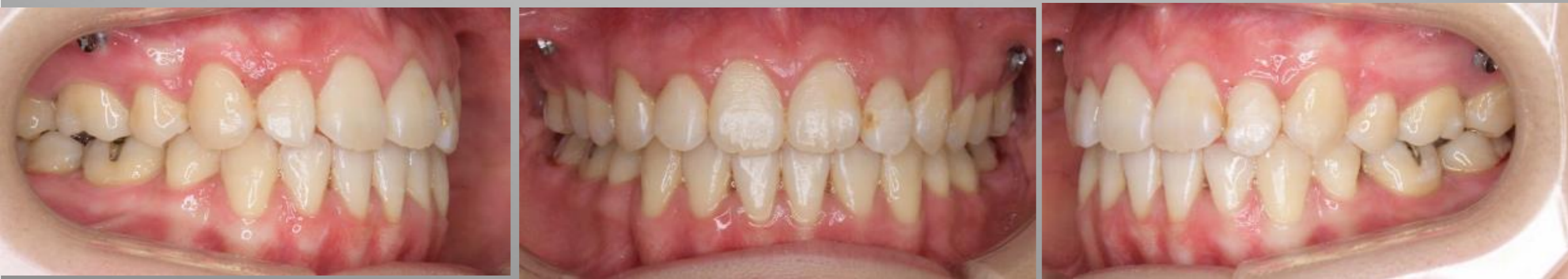DIFFICULTY INDEX :

Mild 0 - 60
 Moderate 60 - 120
 Severe over 120

Oral Photos

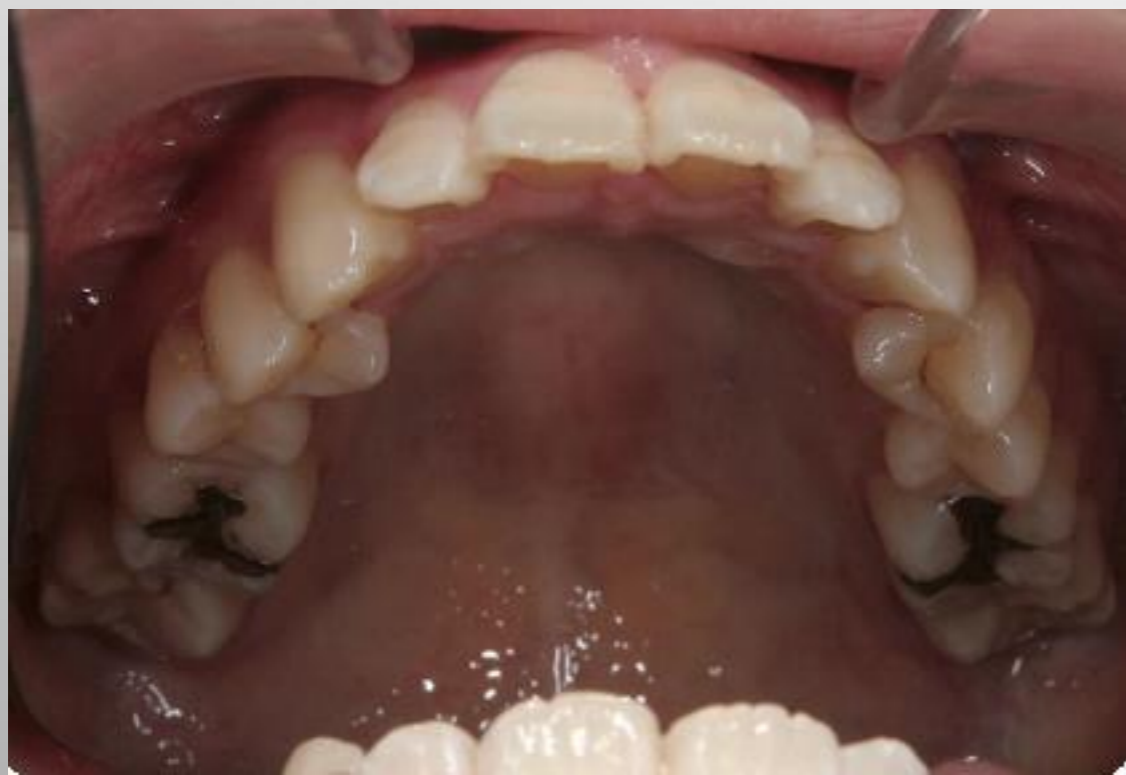

Pre Treatment

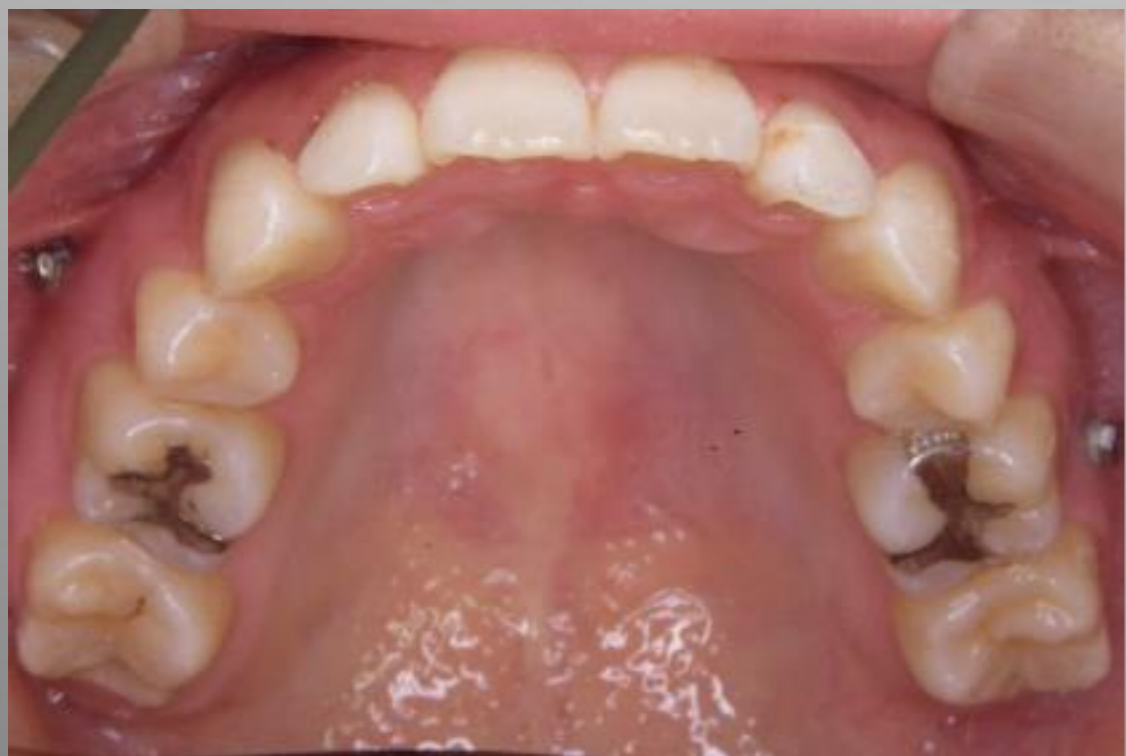
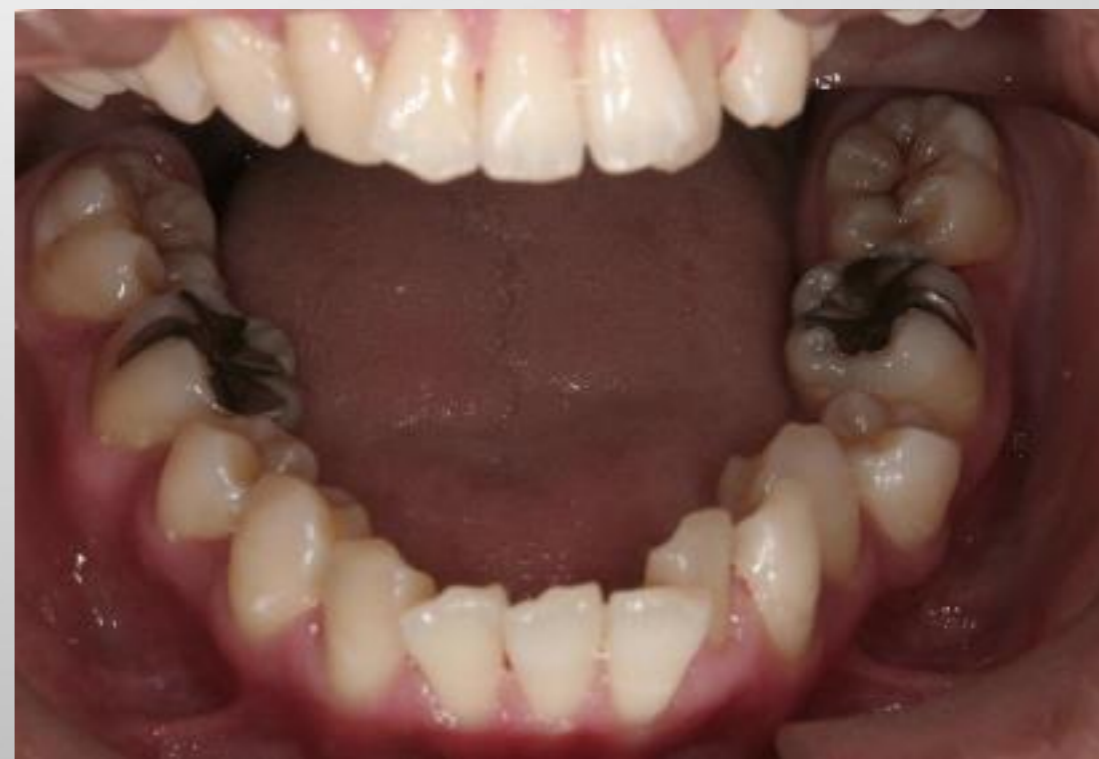
Post Treatment

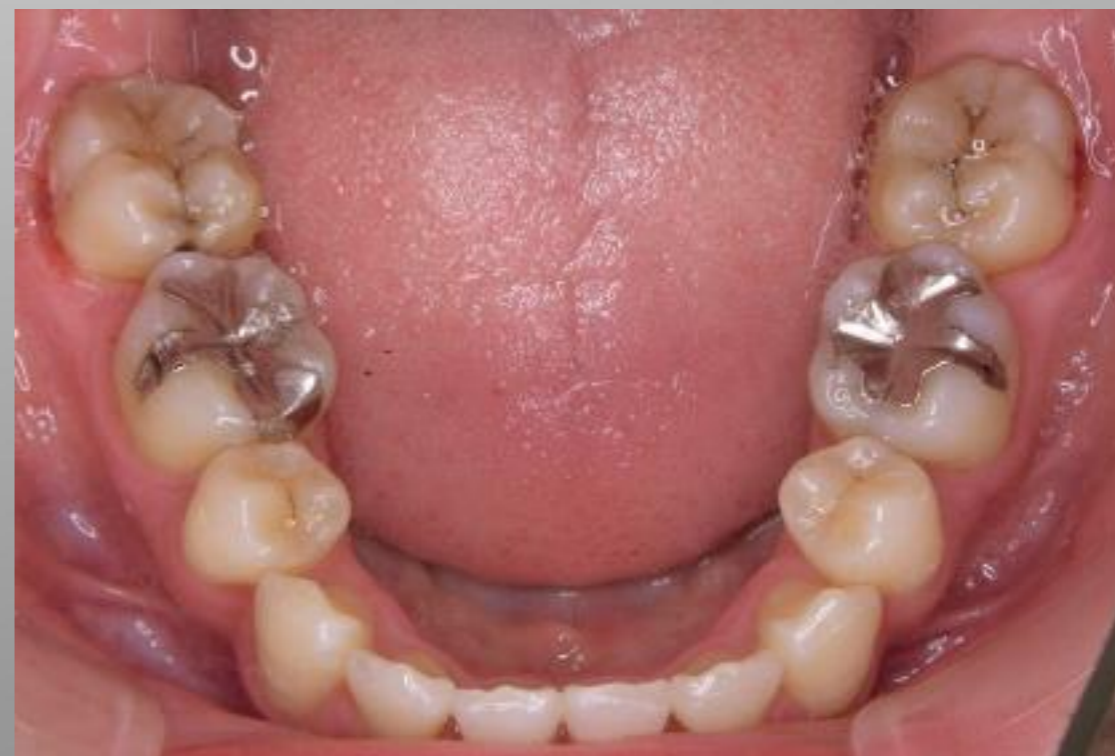Oral Photos



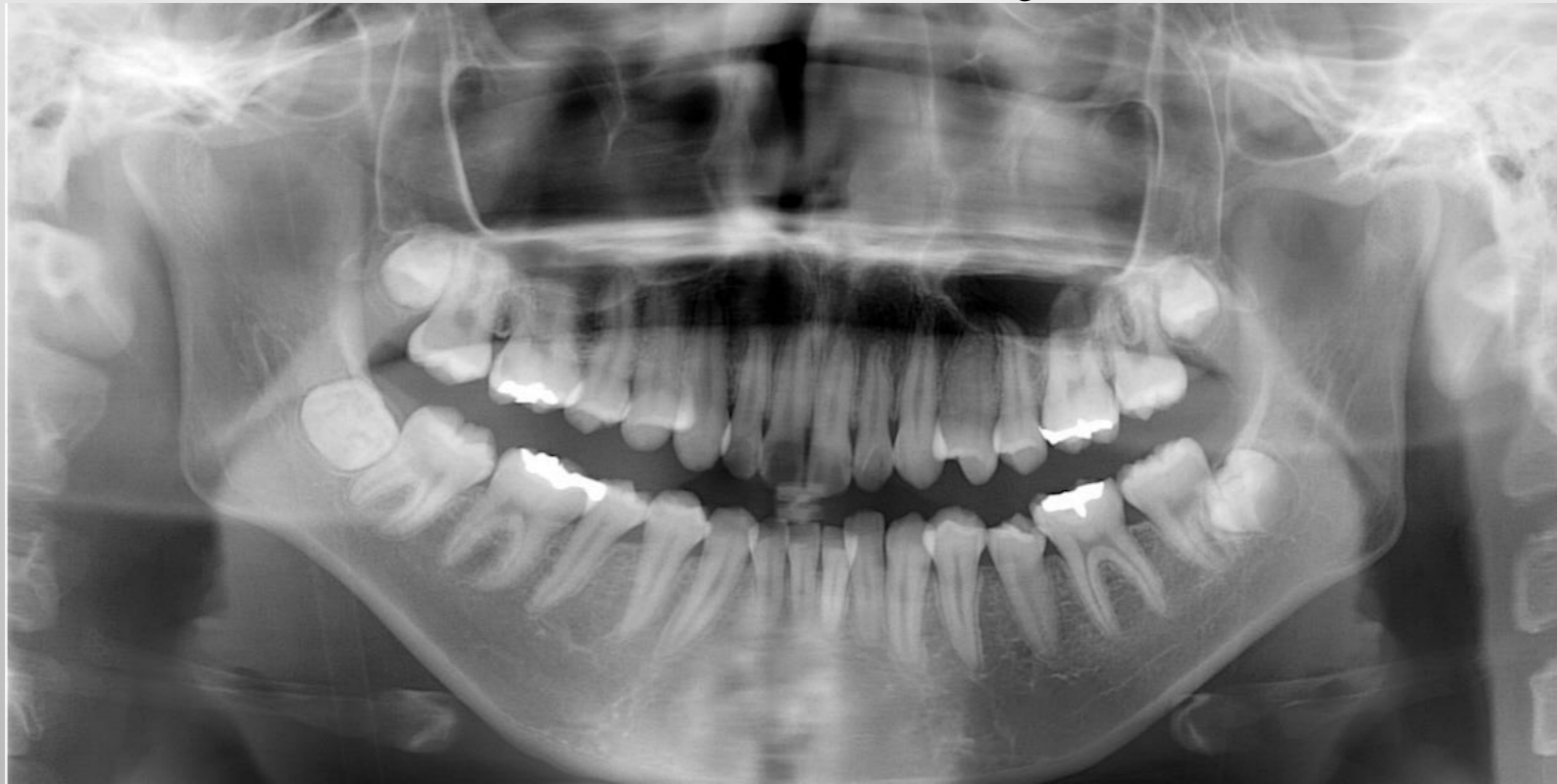Treatment



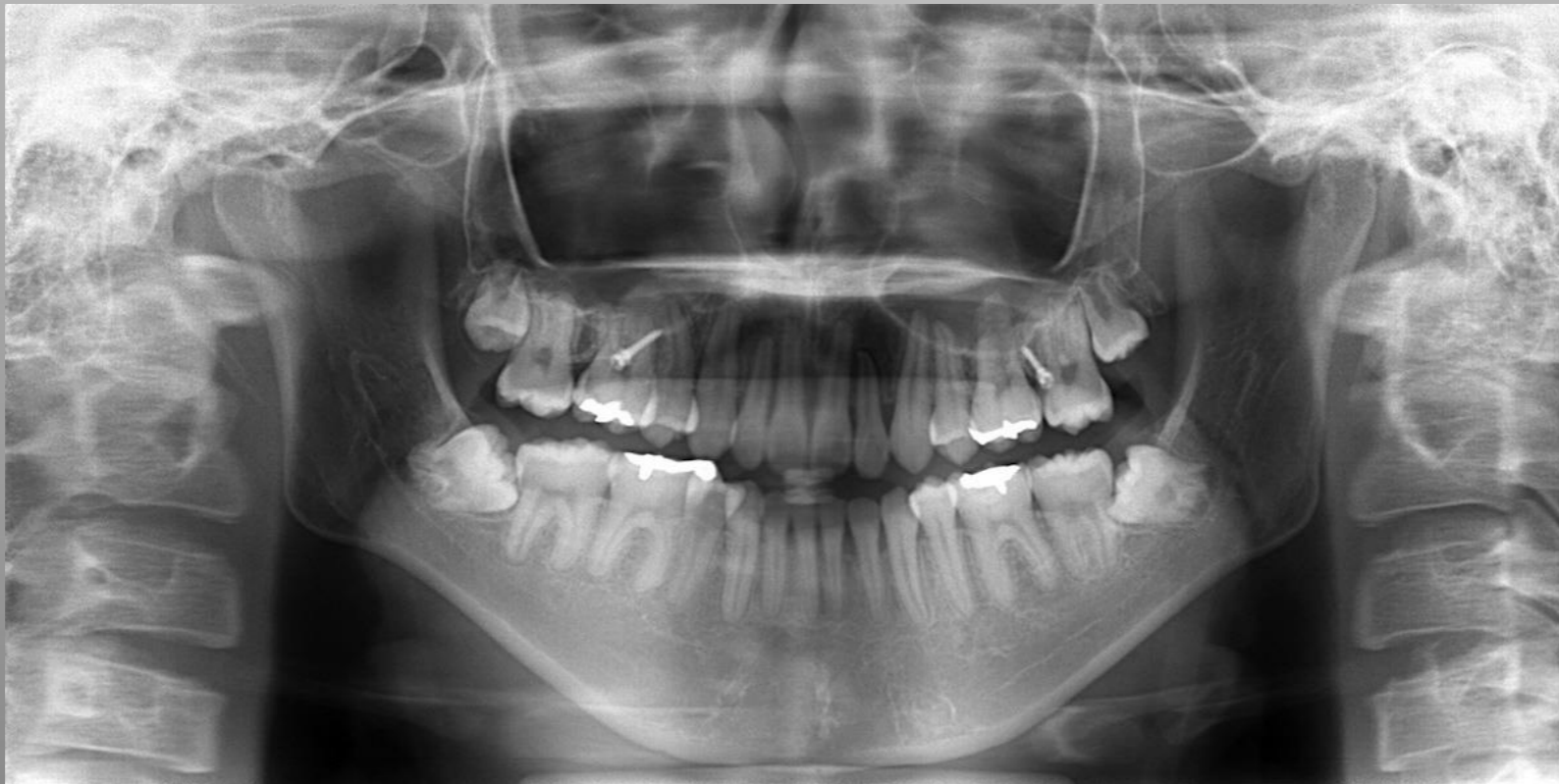Post Treatment



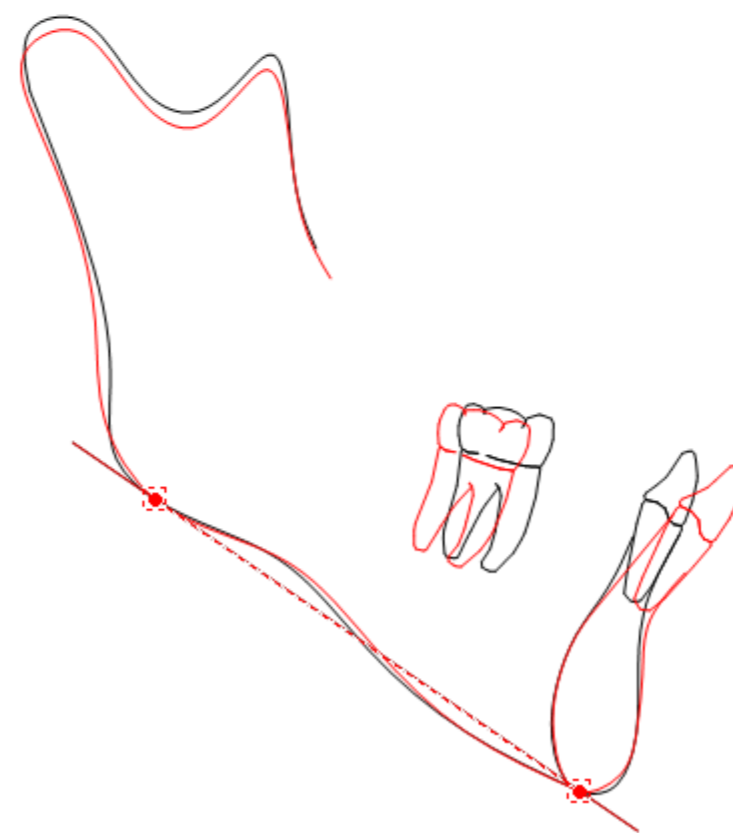
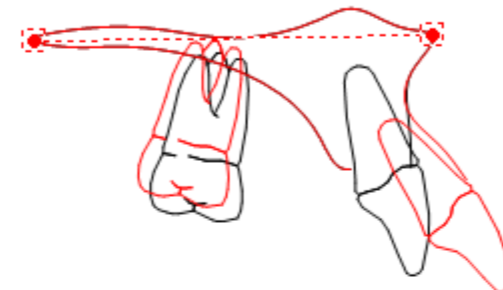
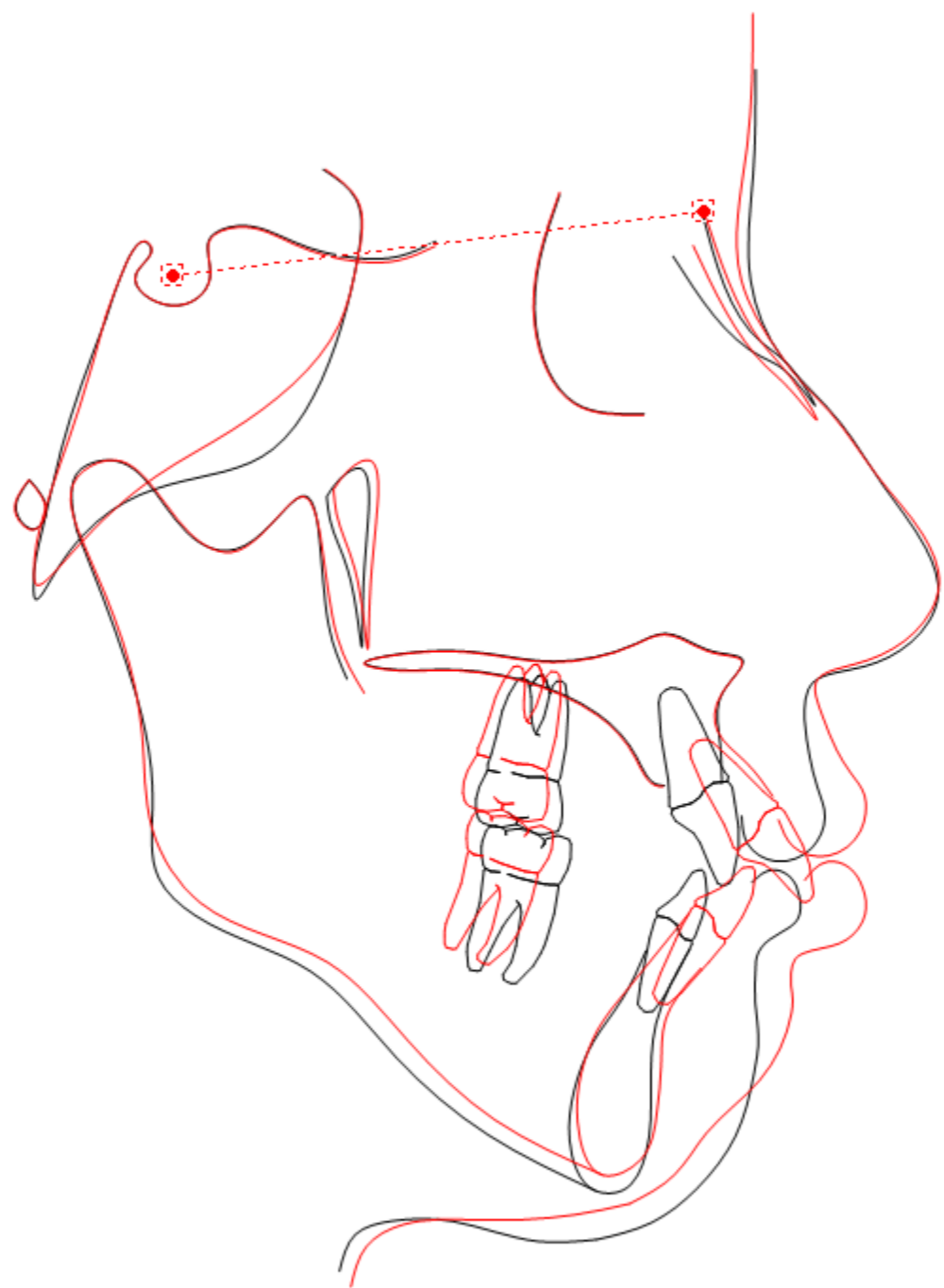
Panorama X ray Photos



Pre Treatment



Post Treatment



Pre-treatment ———
Post-treatment ———