

Differential Diagnosis & Clinical Analysis

ORTHODONTIST'S NAME _____

CODE : M

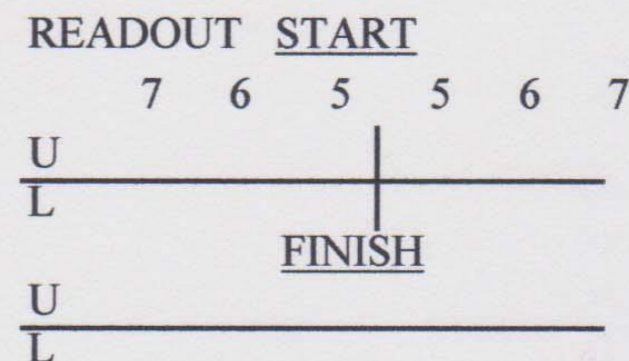
I = TWEED COURSE INSTRUCTOR, M = TWEED MEMBER, A = APPLICANT FOR MEMMBERSHIP

DIFFERENTIAL DIAGNOSIS AND CLINICAL ANALYSIS

PATIENT'S FIRST NAME : _____ INI _____ LAST NAME _____

BEGIN TX. AGE 24 Y 9 M SEX F BIRTHDAY 01 / 05 / 1990 TREATMENT TIME : 19 MONTHS

DATE	2015/05/020		2016/12/023		
	NORMAL	PRE-TX	PROGRESS	FINAL	POST-TX
FMIA	67	48.0		64.0	
FMA	25	28.0		28.0	
IMPA	88	104	180.0	88.0	####
SNA	82	84.0		82.0	
SNB	80	76.0		78.0	
ANB	2	8.0	0.0	4	0.0
AO-BO	2mm	8.0 mm	mm	3.0 mm	mm
OCC PLANE	10	12.0		7.0	
Z ANGLE	75	54.0		68.0	
UPPER LIP		11.0 mm	mm	11.0 mm	mm
TOTAL CHIN		13.0 mm	mm	12.0 mm	mm
POST. FACIAL HT	45mm	47.0 mm	mm	48.0 mm	mm
ANT. FACIAL HT.	65mm	66.0 mm	mm	69.0 mm	mm
FAC. HT. INDEX	0.69	0.71	####	0.7	####
FAC. HT. CHANGI	2:1	XXXX	/	/	/
MAND. CUSPID WIDTH		26.0 mm	mm	27.0 mm	mm
MAND. MOLAR WIDTH		49.0 mm	mm	47.0 mm	mm



DIAGNOSIS:

A. Skeletal :
Class 1

B. Dental :
Angle Class 1
crowding

C. Perio :
Juvenile chronic gingivitis

D. Facial : Uper lip protrusion

CRANIAL FACIAL ANALYSIS

Normal Range	Ceph. Value	Difficulty Factor	Difficulty
FMA 22-28	28.0	5	0
ANB 1-5	8.0	15	45
Z-ANGLE 70-80	54.0	2	32
OCC. PLANE 8-12	12.0	3	0
SNB 78-82	76.0	5	10
PFH/AFH 0.65-0.75	0.71	3	0
C.F. Difficulty Total			87

E. Habits :

1. Thumb Suck n.p
2. Tongue Thrus n.p
3. Bruxism n.p.

F. Joint Health : n.p.

TOTAL SPACE ANALYSIS

		Difficulty Factor	Difficulty
Anterior			
Tooth Arch Disc.	1.0	1.5	1.5
Headfilm Disc.	15.0	1	15.0
Total	16.0		
Mid Arch			
Tooth Arch Disc.	2.0	1.0	2.0
Curve of Spee	2.0	1.0	2.0
Total	4.0		
Horizontal Occlusal Disharmony (Class II or Class III)			
	0.0	2.0	0.0
Posterior			
Tooth Arch Disc.	0.0		
(-)-expected Inc.			
Total	0.0	0.5	0.0
Space Analysis Total	20.0	Space Analysis Difficulty Total	20.5

TRERATMENT PLANNING, TIMING
EXTRACTIONS:

MAXILLARY

RIGHT 5 LEF' 4

MANDIBULAR

RIGHT 5 LEF' 5

(Please Indicate Missing Teeth)

* The Patient was refered to me after her 5_⊥、5_T were extracted by another Orthodontist

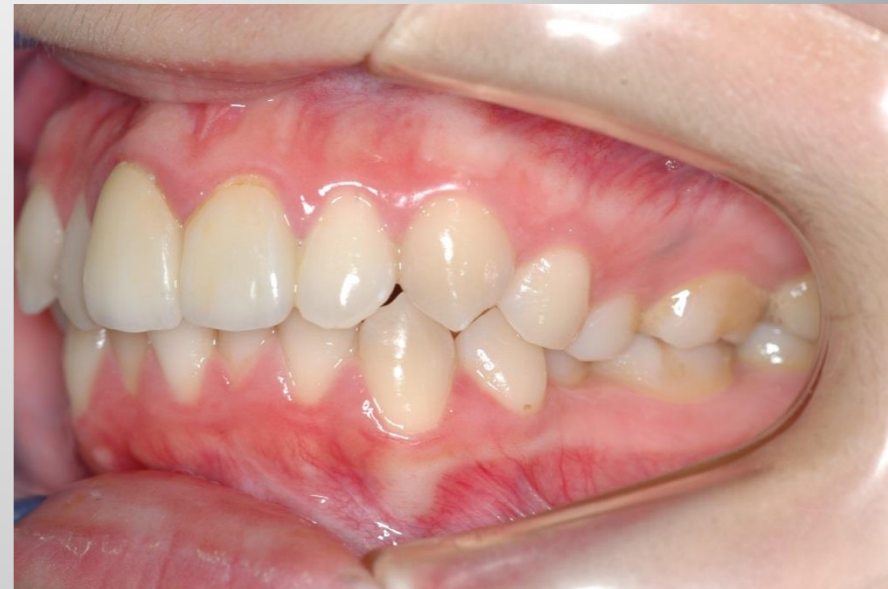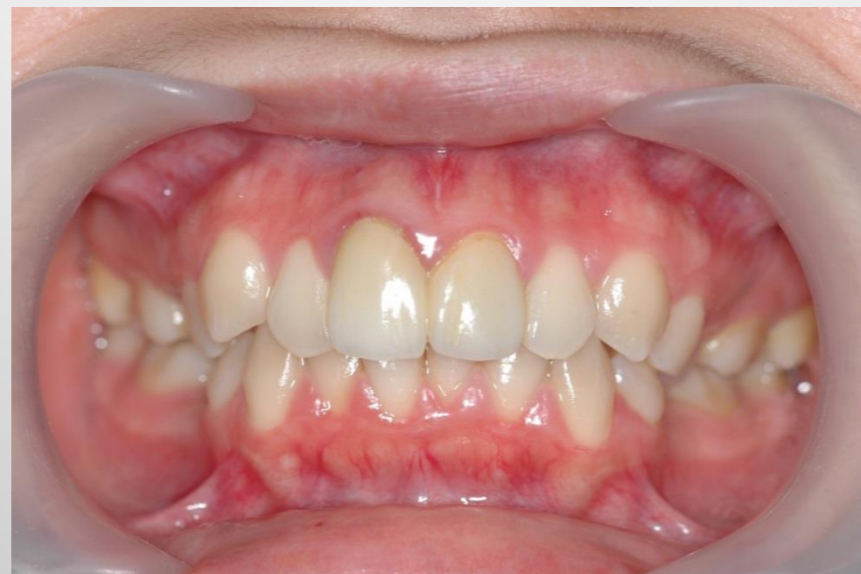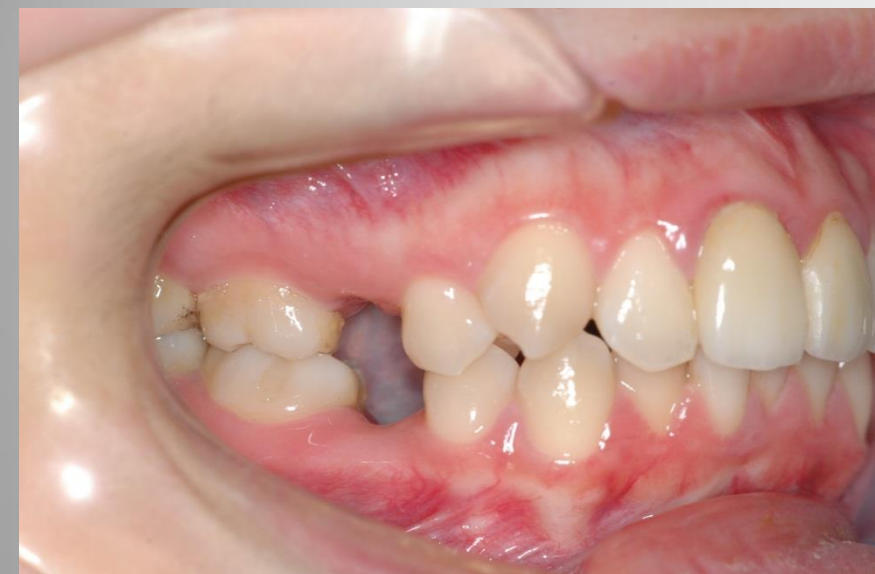*The Previous Orthodontist,a lightwire operator

DIFFICULTY INDEX :

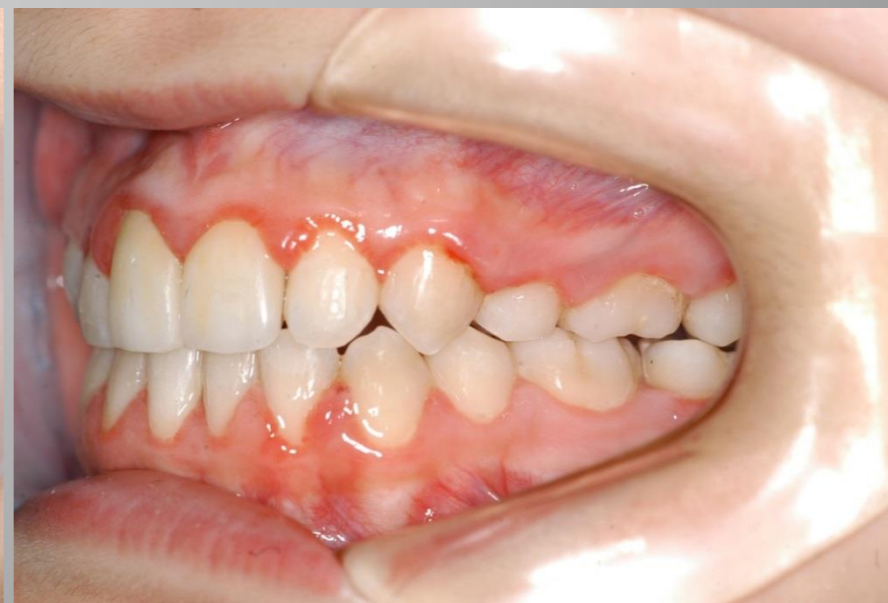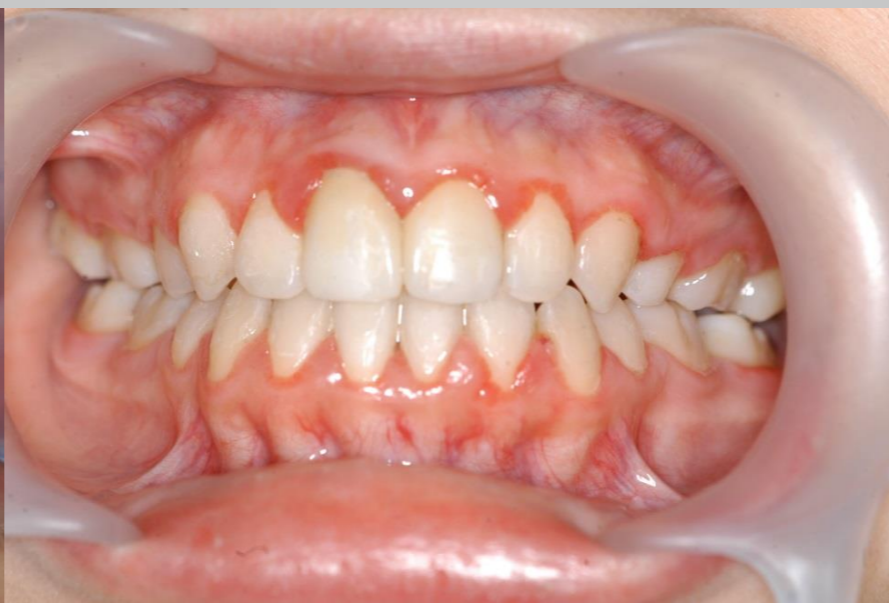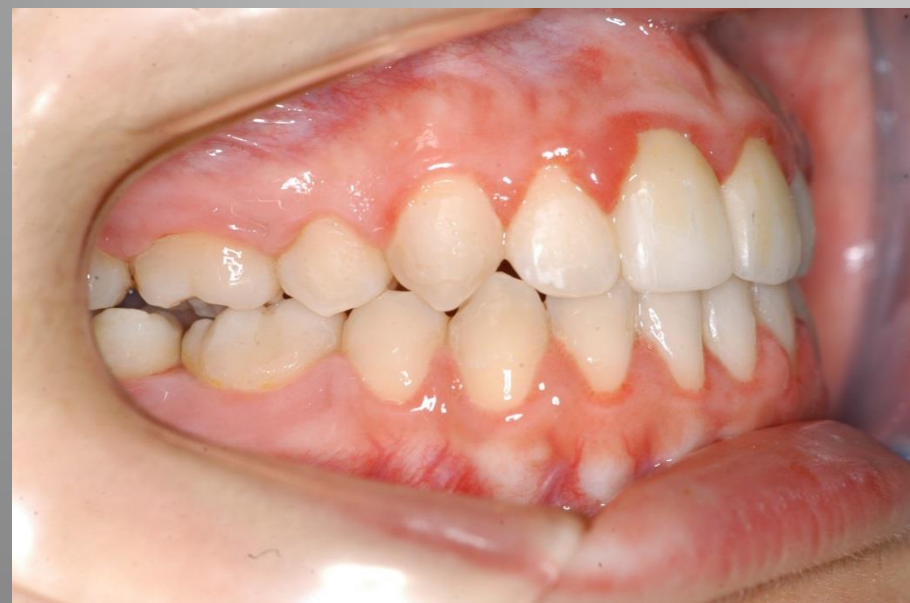Mild 0 - 60
Moderate 60 - 120
Severe over 120

C.F. Difficulty Total	87
Space Analysisi Difficulty Total	20.5
Total Difficulty	126

Oral Photos

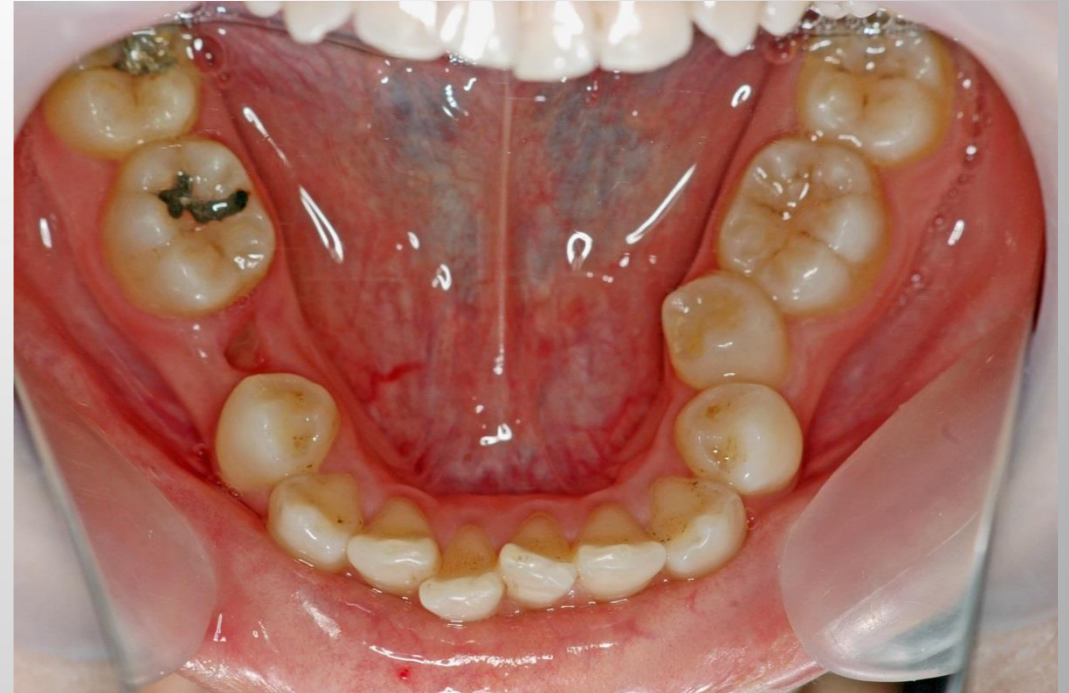
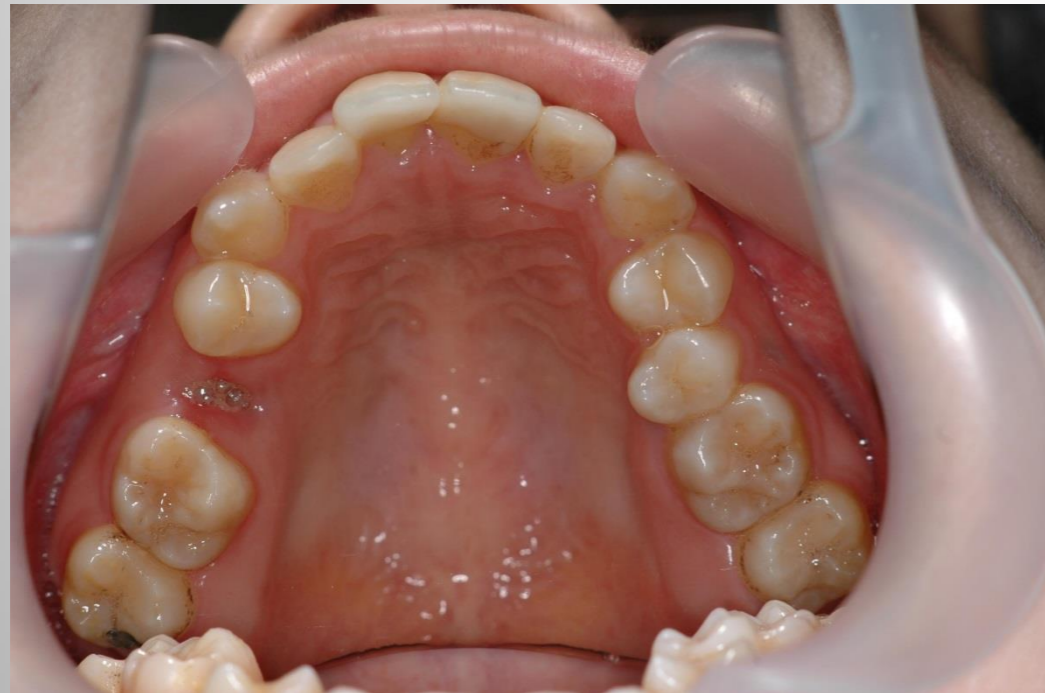


Pre Treatment

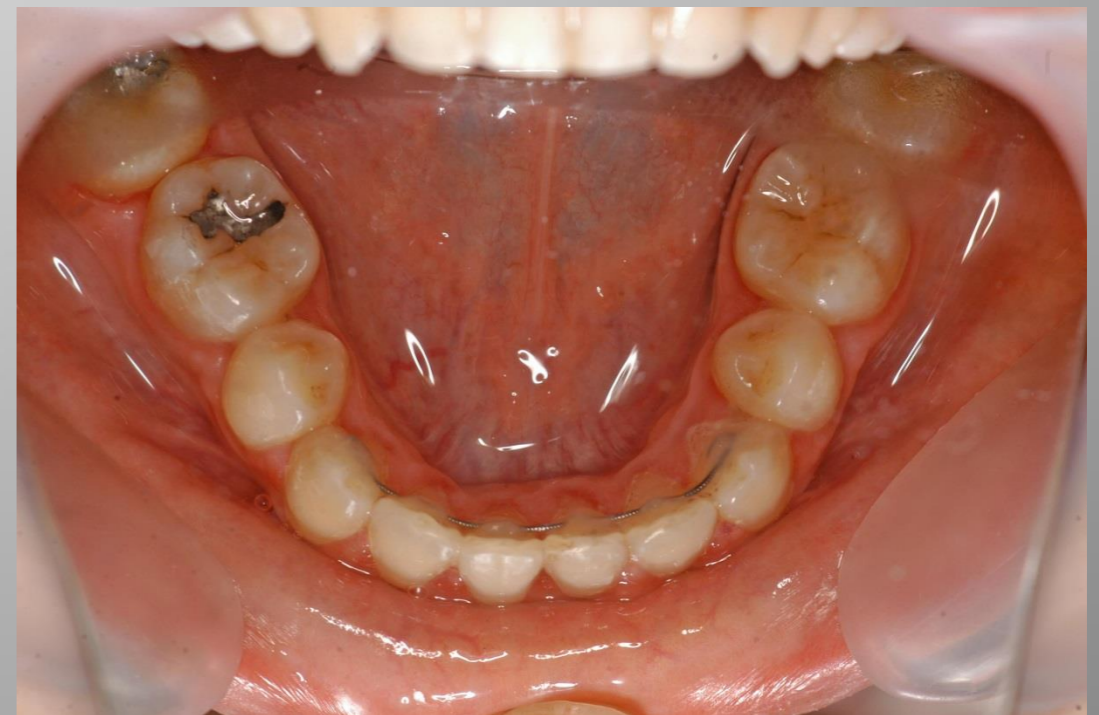
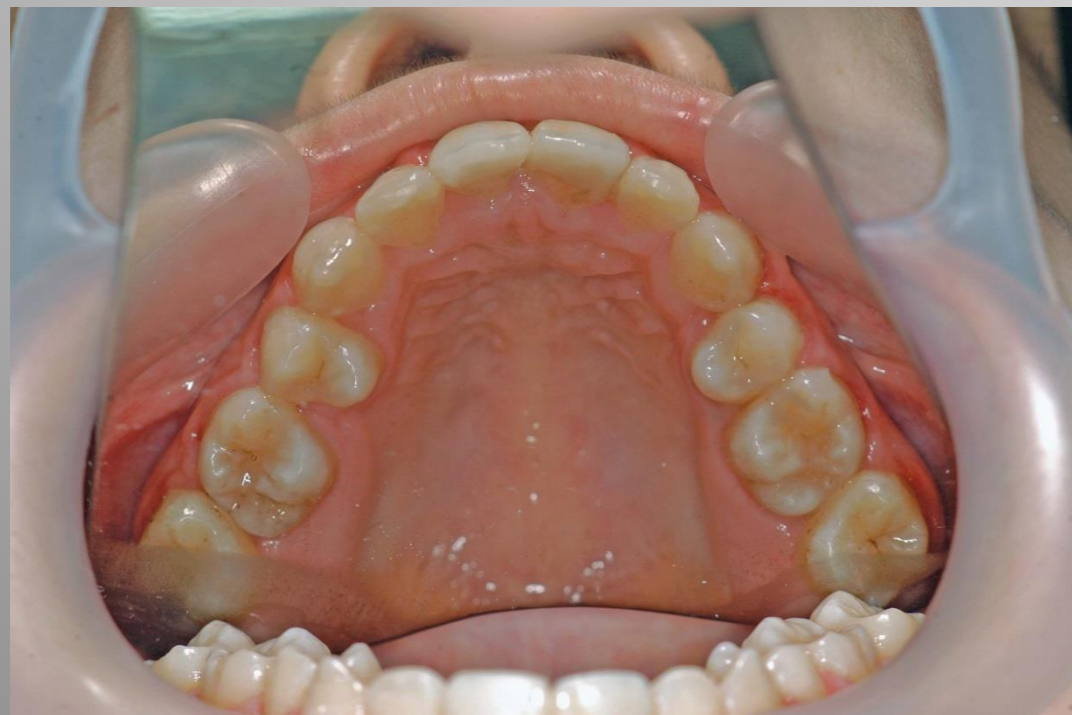
Post Treatment

Oral Photos

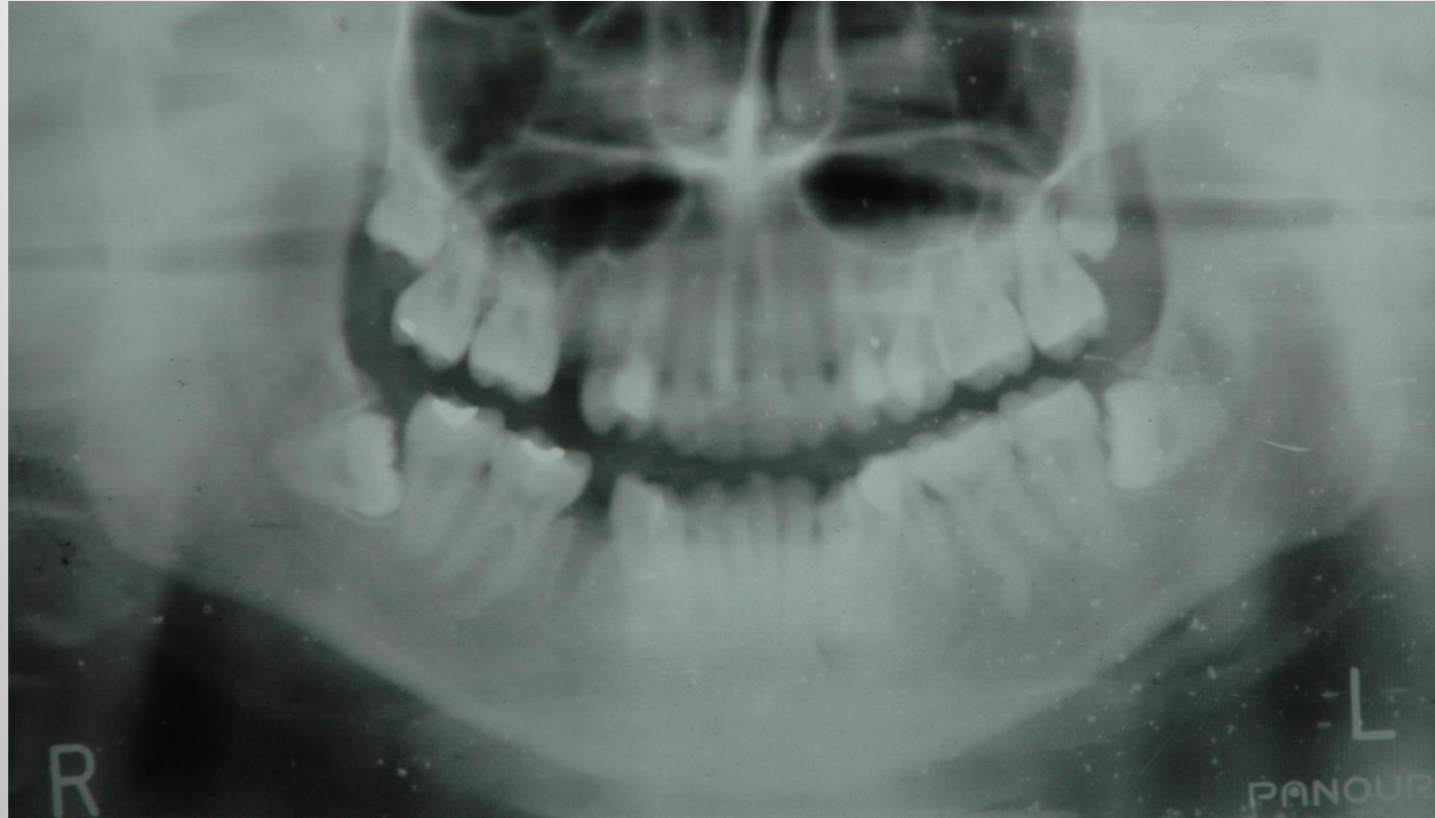


Pre Treatment

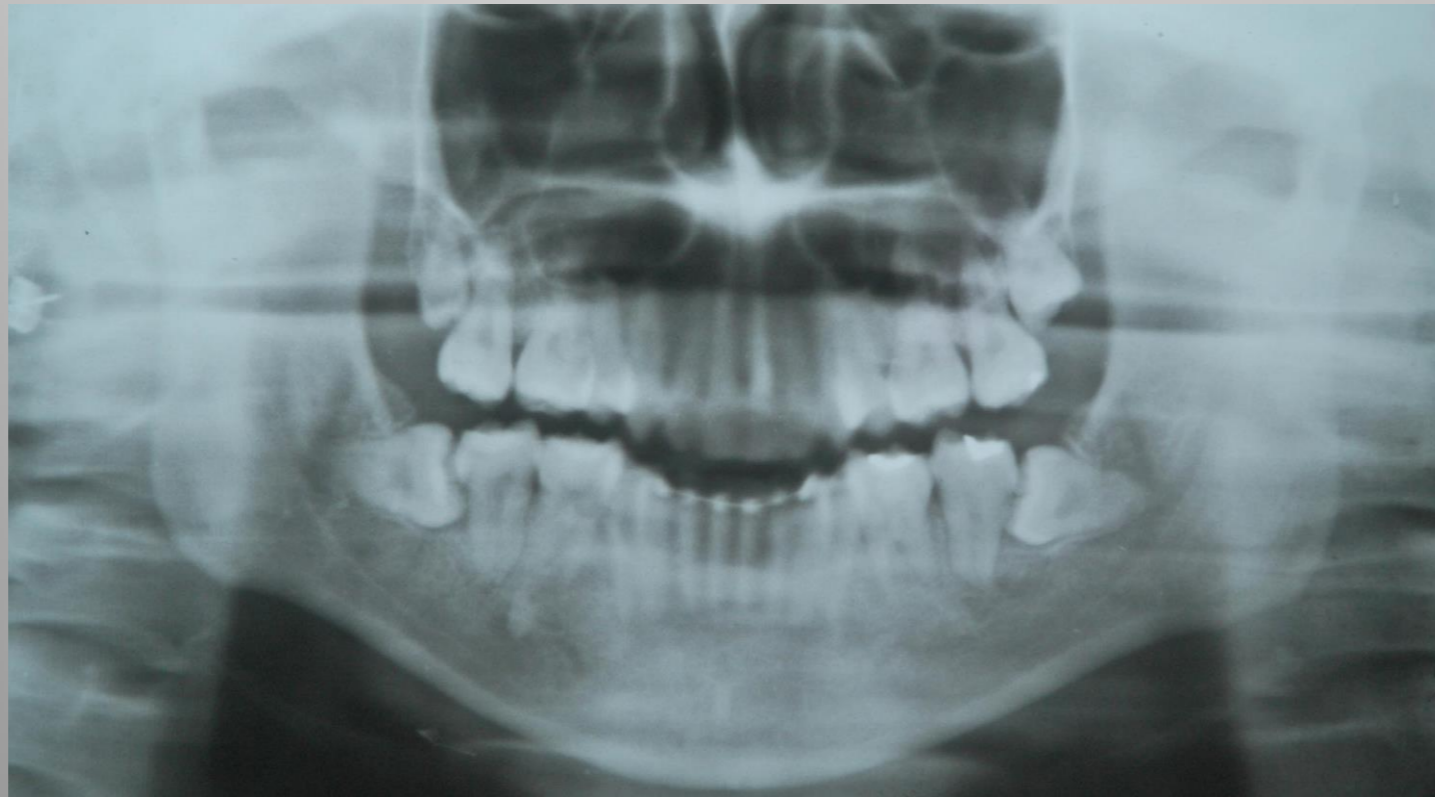


Post Treatment

Panorama X ray Photos

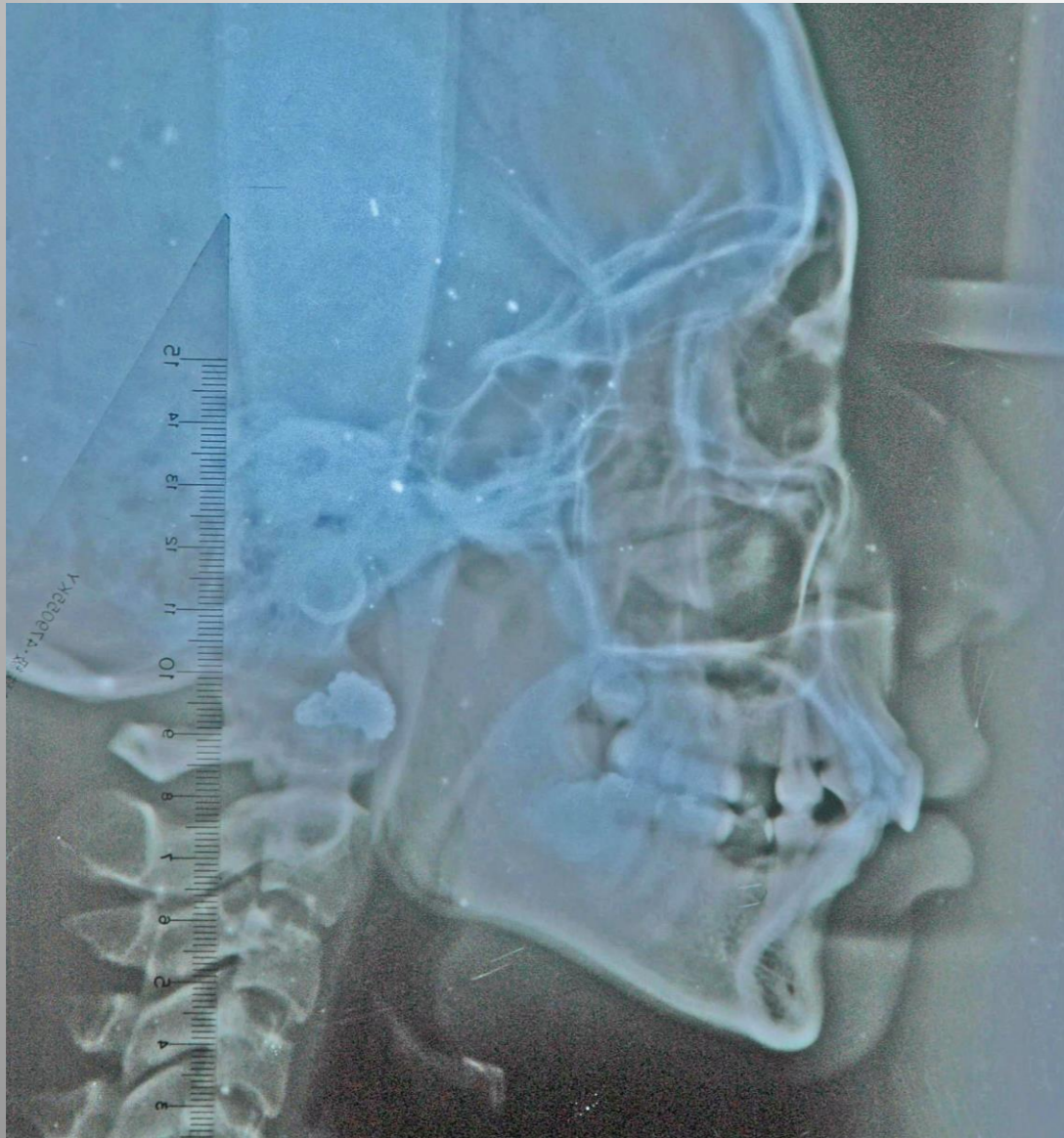


Pre Treatment

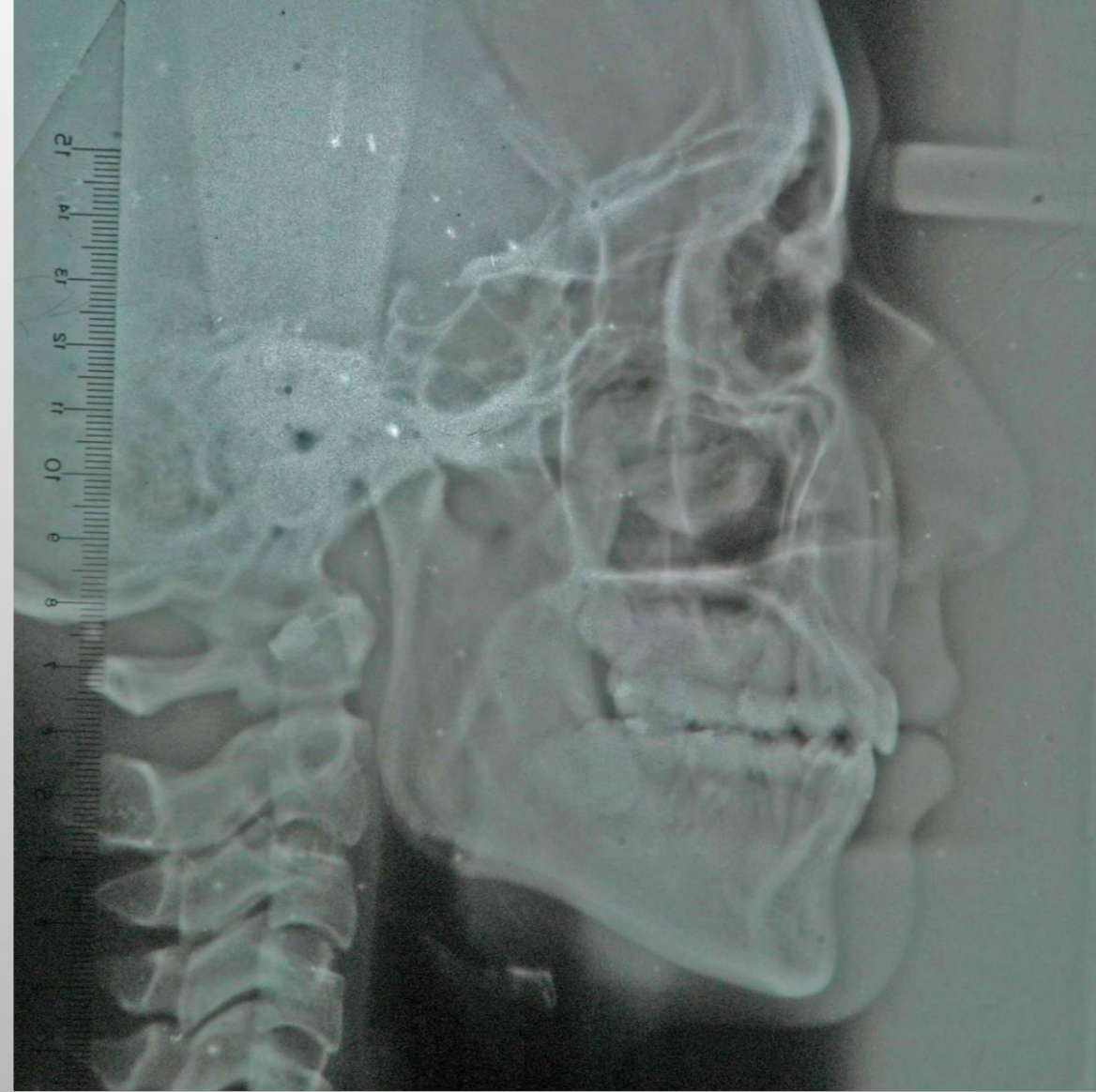

Post Treatment

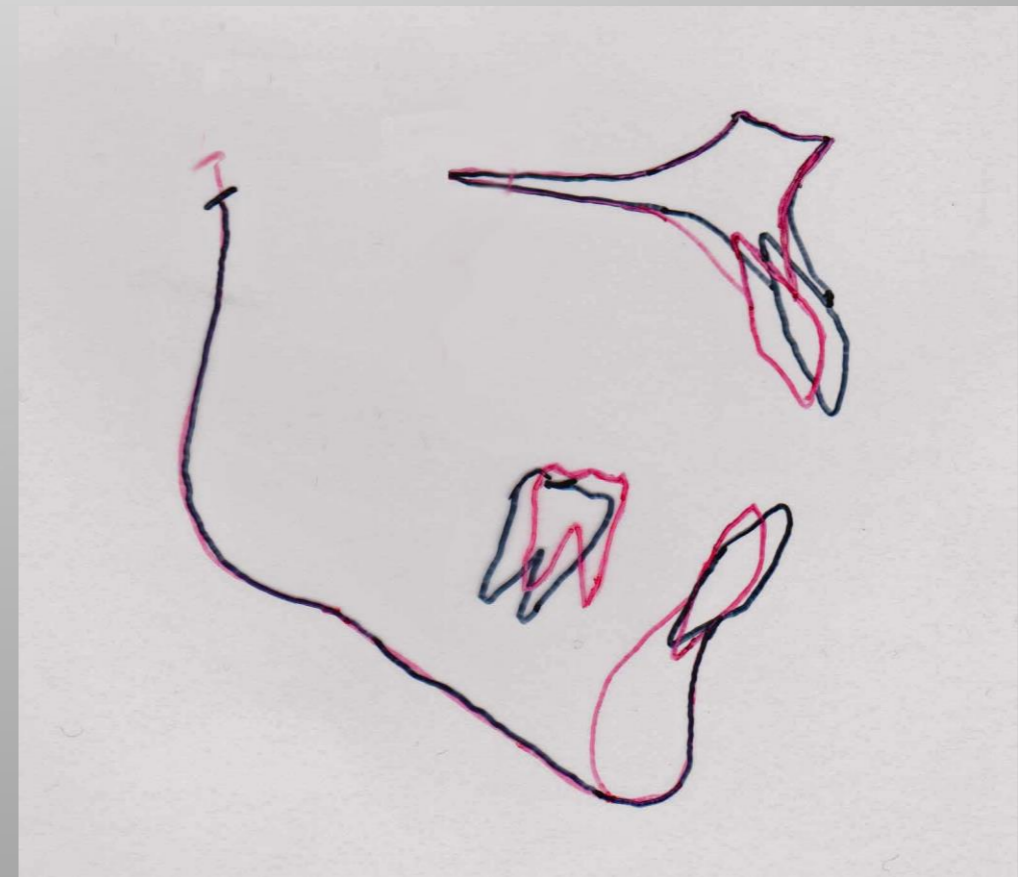
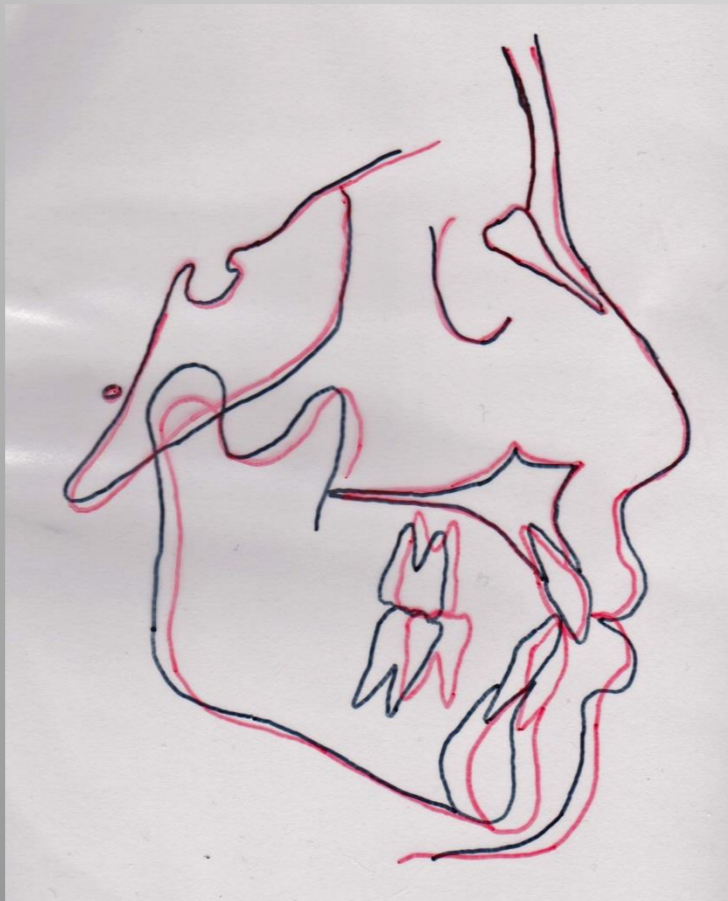
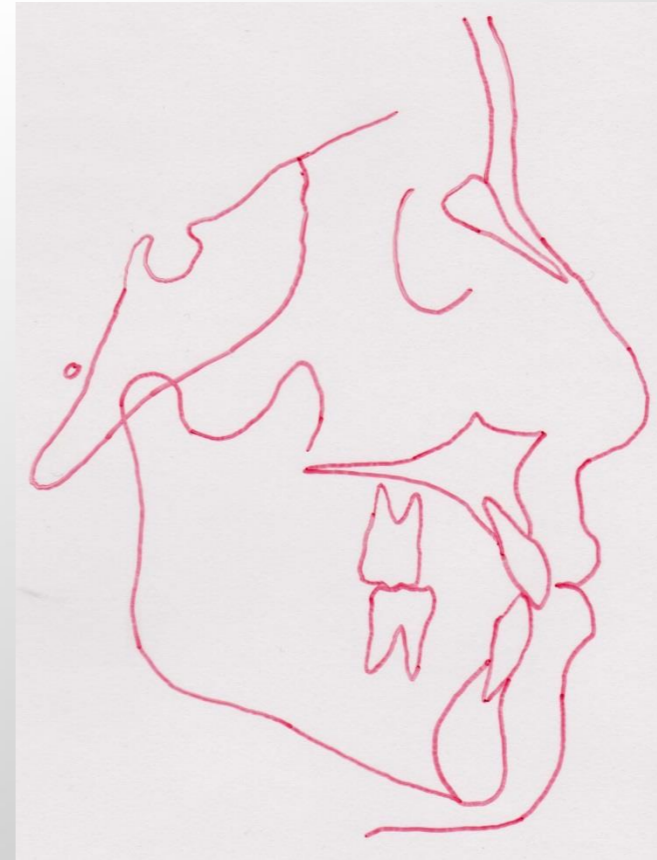
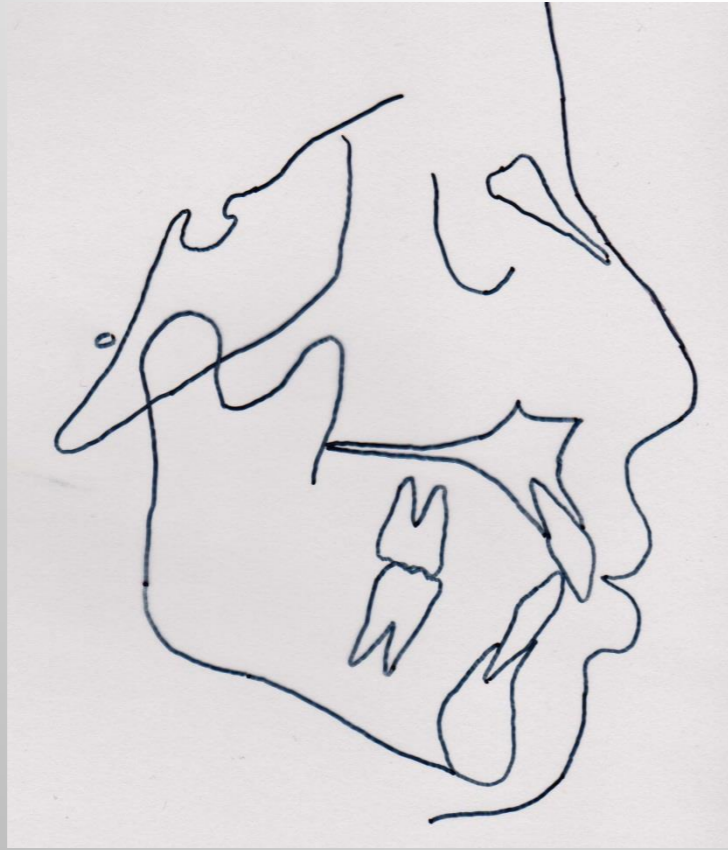Cephalo X ray Photos



Pre Treatment



Post Treatment



Pre-treatment ———
Post-treatment ———