

**Angle Class II high FMA with open bite  
suffered from arthrosis deformans of TMJ**

# Differential Diagnosis & Clinical Analysis

ORTHODONTIST'S NAME \_\_\_\_\_ CODE: I

I = TWEED COURSE INSTRUCTOR, M = TWEED MEMBER, A = APPLICANT FOR MEMMBERSHIP

## DIFFERENTIAL DIAGNOSIS AND CLINICAL ANALYSIS

PATIENT'S FIRST NAME: \_\_\_\_\_ INI \_\_\_\_\_ LAST NAME: \_\_\_\_\_

BEGIN TX. AGE 35 Y 7 M SEX F BIRTHDAY 9 / 11 / 1972 TREATMENT TIME: 66 MONTHS

DATE	30/8/2008	10/2/2014	READOUT <u>START</u>			
	NORMAL	PRE-TX	PROGRESS	FINAL	POST-TX	7 6 5 5 6 7
FMIA	67	46.0		51.0		U
FMA	25	48.0		49.0		L
IMPA	88	86.0	180.0	80.0	180.0	<u>FINISH</u>
SNA	82	80.0		78.0		U
SNB	80	68.5		67.0		L
ANB	2	11.5	0.0	11.0	0.0	
AO-BO	2mm	6.0 mm	mm	5.0 mm	mm	DIAGNOSIS:
OCC PLANE	10	19.5		22.0		A. Skeletal :
Z ANGLE	75	56.0		69.0		
UPPER LIP		10.0 mm	mm	12.0 mm	mm	
TOTAL CHIN		13.0 mm	mm	19.0 mm	mm	B. Dental :
POST. FACIAL HT.	45mm	40.0 mm	mm	40.0 mm	mm	
ANT. FACIAL HT.	65mm	75.0 mm	mm	77.0 mm	mm	
FAC. HT. INDEX	0.69	0.53	####	0.52	####	C. Perio :
FAC. HT. CHANGE	2:1	XXXX	/	/	/	
MAND. CUSPID WIDTH		24.5 mm	mm	25.5 mm	mm	
MAND. MOLAR WIDTH		56.0 mm	mm	52.0 mm	mm	D. Facial :

**CRANIAL FACIAL ANALYSIS**

	Ceph.	Difficulty			E. Habits :
<b>Normal Range</b>	Value	Factor		<b>Difficulty</b>	1. Thumb Sucker 2. Tongue Thrust 3. Bruxism
FMA 22-28	48.0	5		100	
ANB 1-5	11.5	15		98	
Z-ANGLE 70-80	56.0	2		28	
OCC. PLANE 8-12	19.5	3		23	F. Joint Health :
SNB 78-82	68.5	5		48	
PFH/AFH 0.65-0.75	0.53	3		36	
	<b>C.F. Difficulty Total</b>			<b>332</b>	

**TOTAL SPACE ANALYSIS**

		Difficulty			
<b>Anterior</b>		Factor		<b>Difficulty</b>	TRERATMENT PLANNING, TIMING EXTRACTIONS:
Tooth Arch Disc.	4.5	1.5		6.8	MAXILLARY
Headfilm Disc.	15.2	1		15.2	RIGHT 8 4 LEFT 4 6
Soft Tissue Mod.		0.5		0.0	MANDIBULAR
<b>Total</b>	<b>19.7</b>			<b>22.0</b>	RIGHT 8 5 LEFT 5 8

<b>Mid Arch</b>					( Please Indicate Missing Teeth )
Tooth Arch Disc.	3.4	1.0		3.4	
Curve of Spee	1.2	1.0		1.2	
<b>Total</b>	<b>4.6</b>	<b>1.0</b>		<b>4.6</b>	

Horizontal Occlusal Disharmony (Class II or Class III)	6.0	2.0		12.0	
---	-----	-----	--	------	--

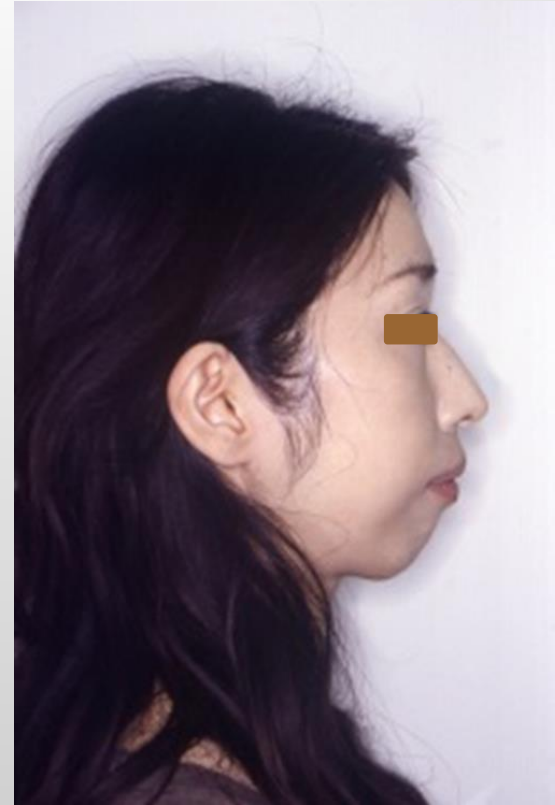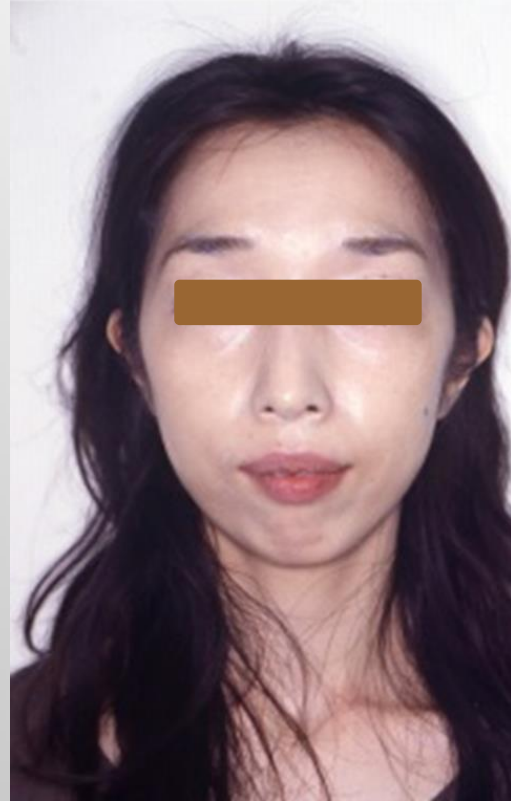
<b>Posterior</b>					
Tooth Arch Disc.	18.4				
(-)expected Inc.					
<b>Total</b>	<b>18.4</b>	<b>0.5</b>		<b>9.2</b>	

<b>Space Analysis Total</b>	<b>42.7</b>	<b>Space Analysis Difficulty Total</b>		<b>69.7</b>	
-----------------------------	-------------	--	--	-------------	--

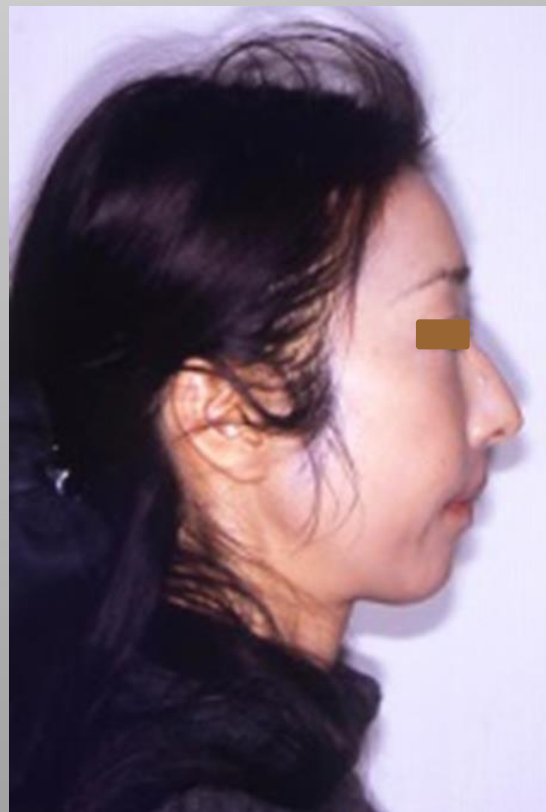
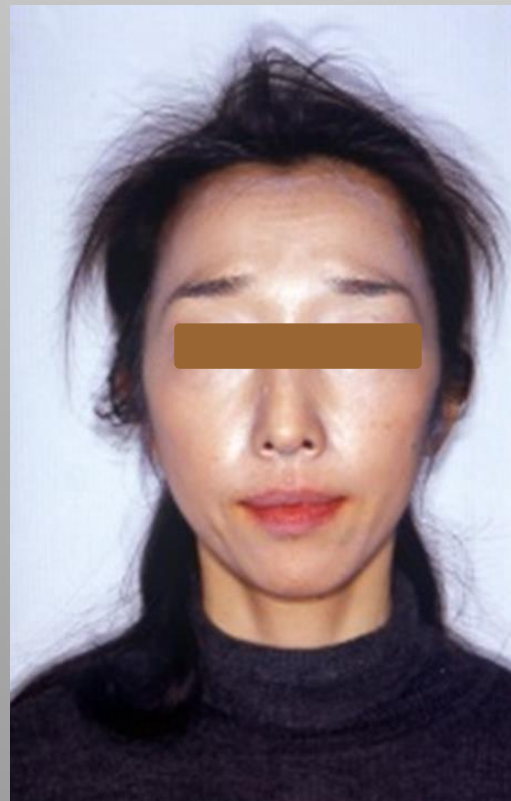
				<b>DIFFICULTY INDEX :</b>	
<b>C.F. Difficulty Total</b>	<b>331.5</b>			Mild	0 - 60
<b>Space Analysisi Difficulty Total</b>	<b>69.7</b>			Moderate	60 - 120
<b>Total Difficulty</b>	<b>401.2</b>			Severe	over 120

# Facial Proportions & Esthetics

PRE-TX

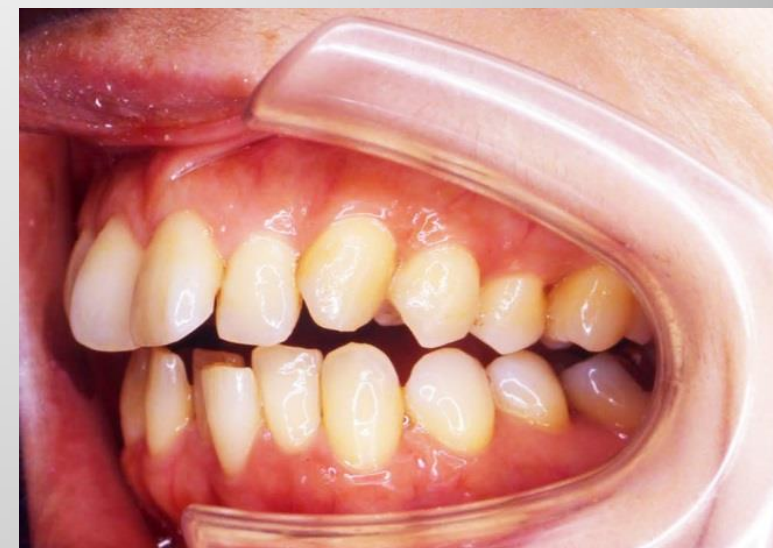
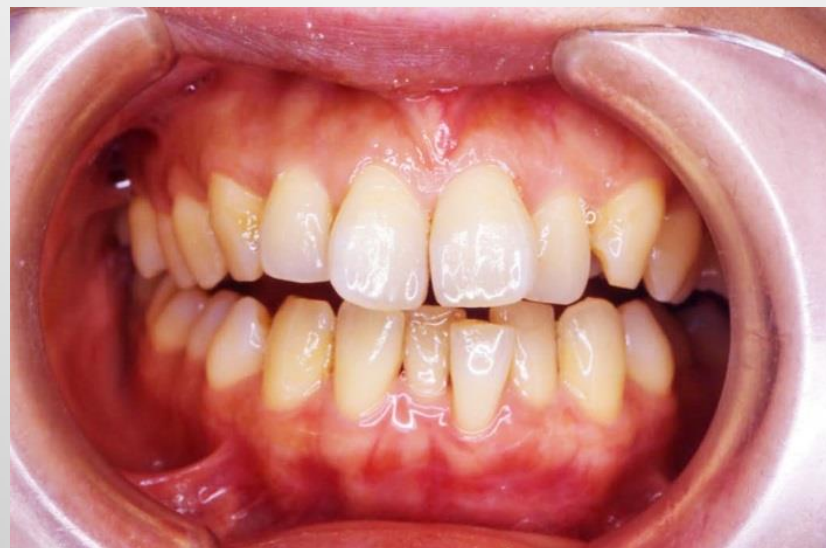
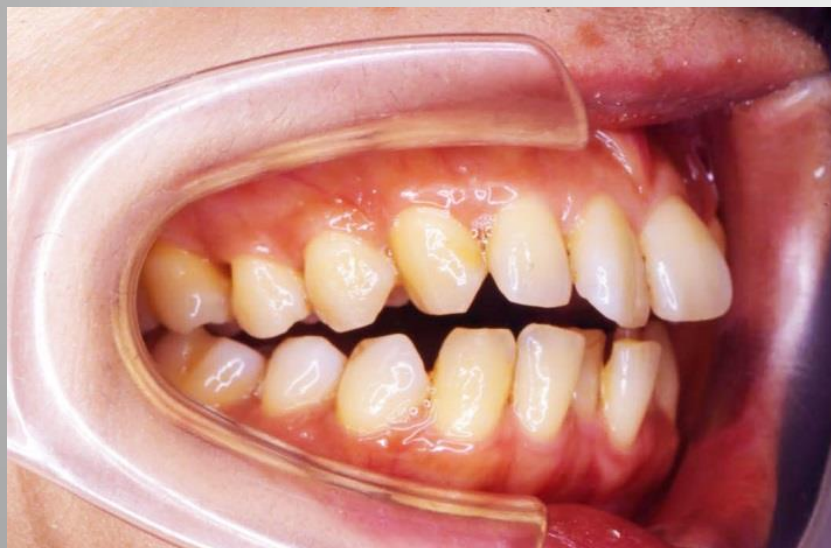FINAL

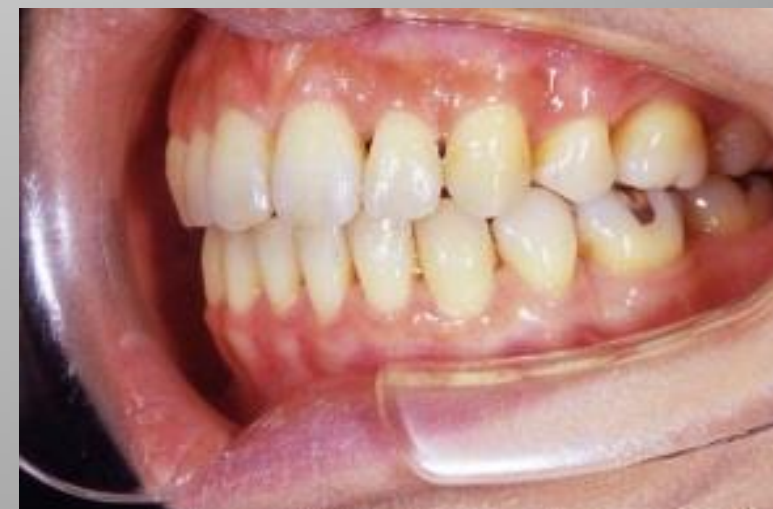
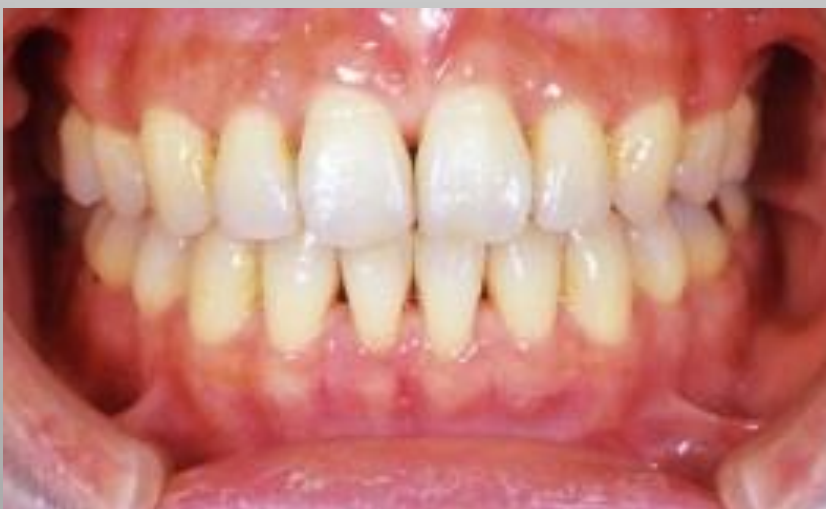
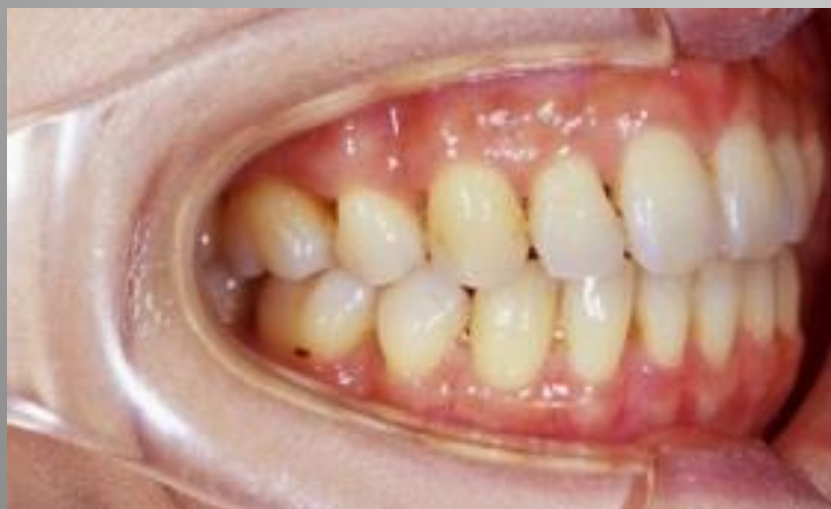

# Oral Photos



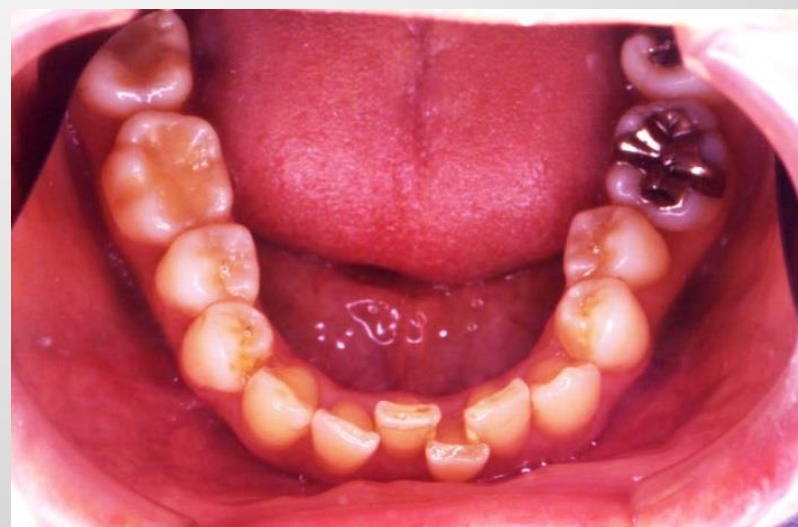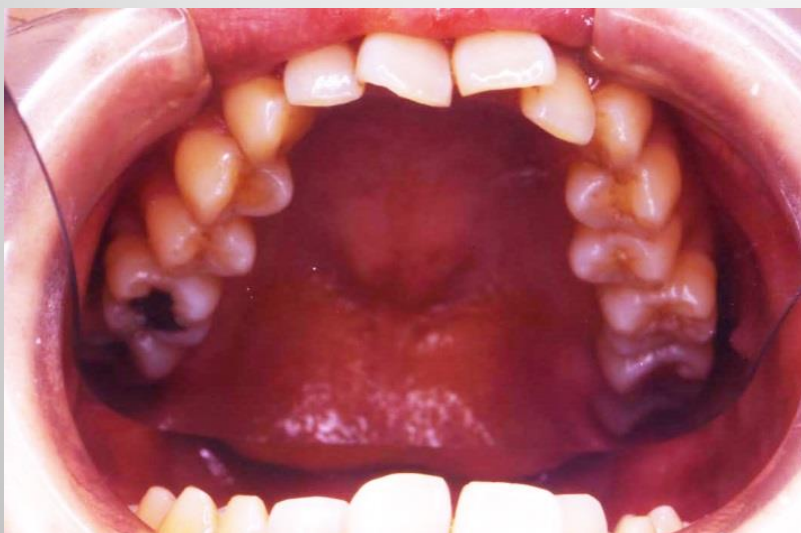
PRE-TX



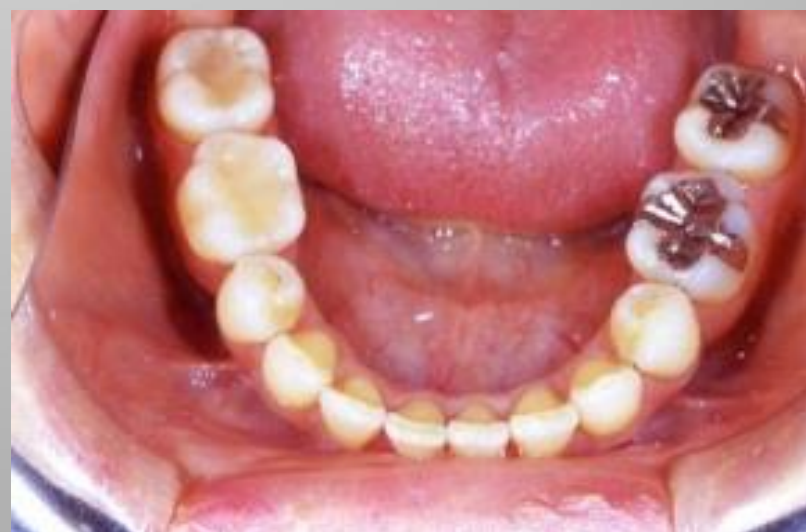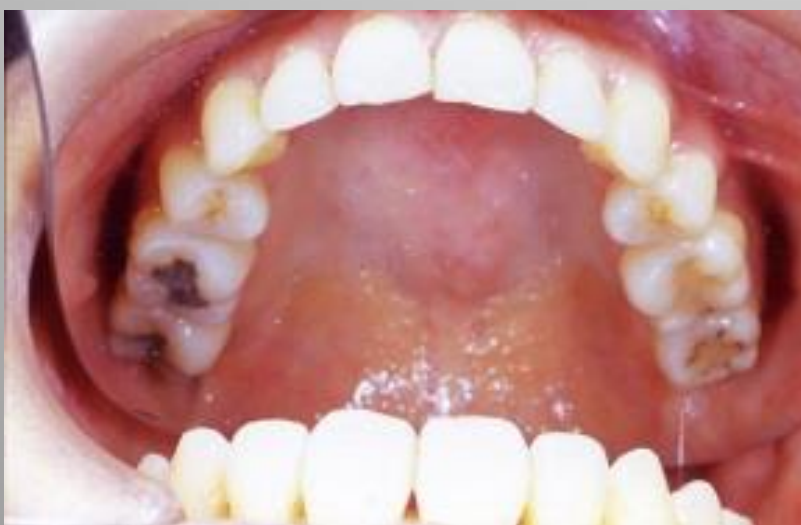FINAL



# Oral Photos



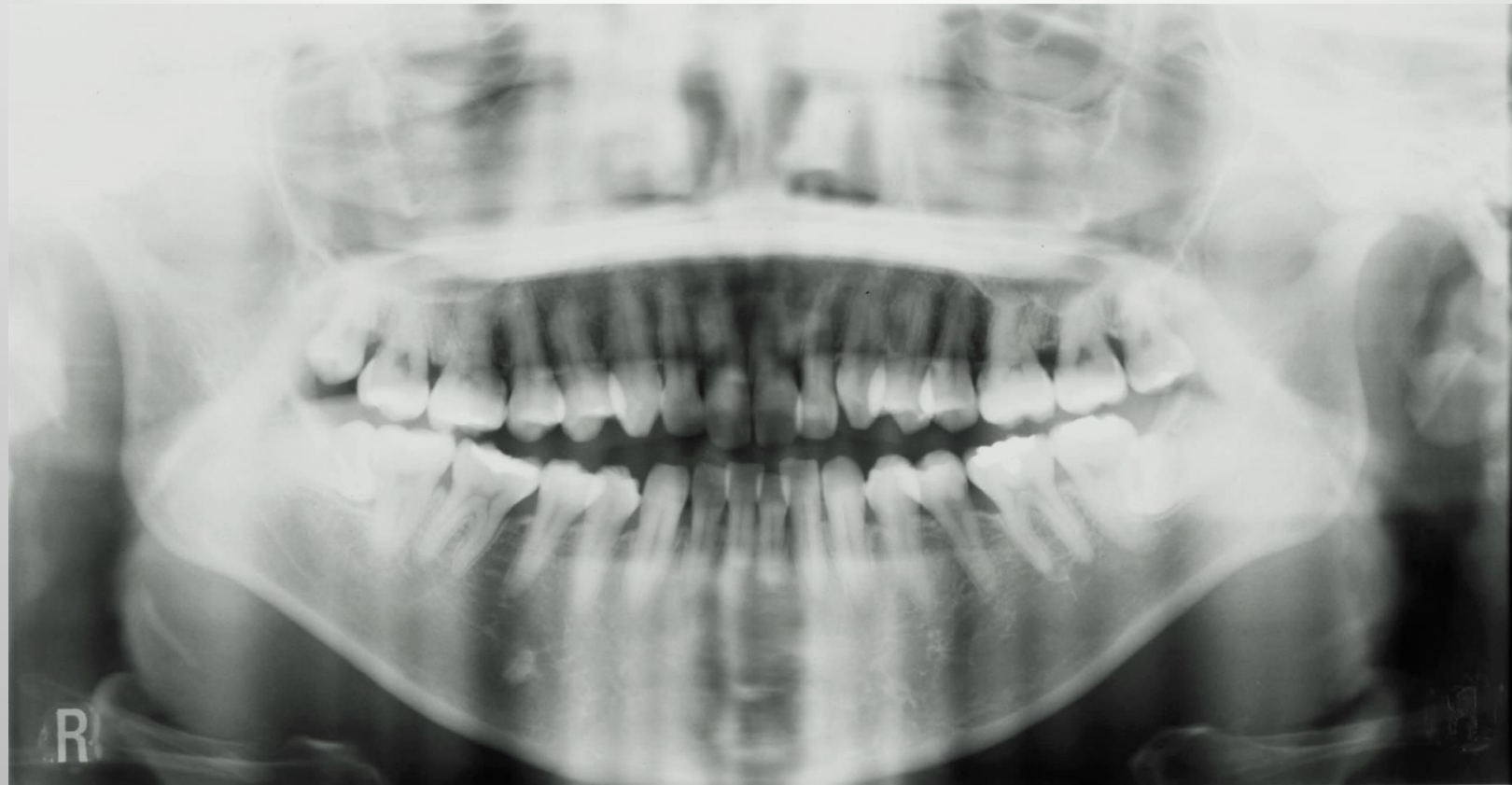PRE-TX



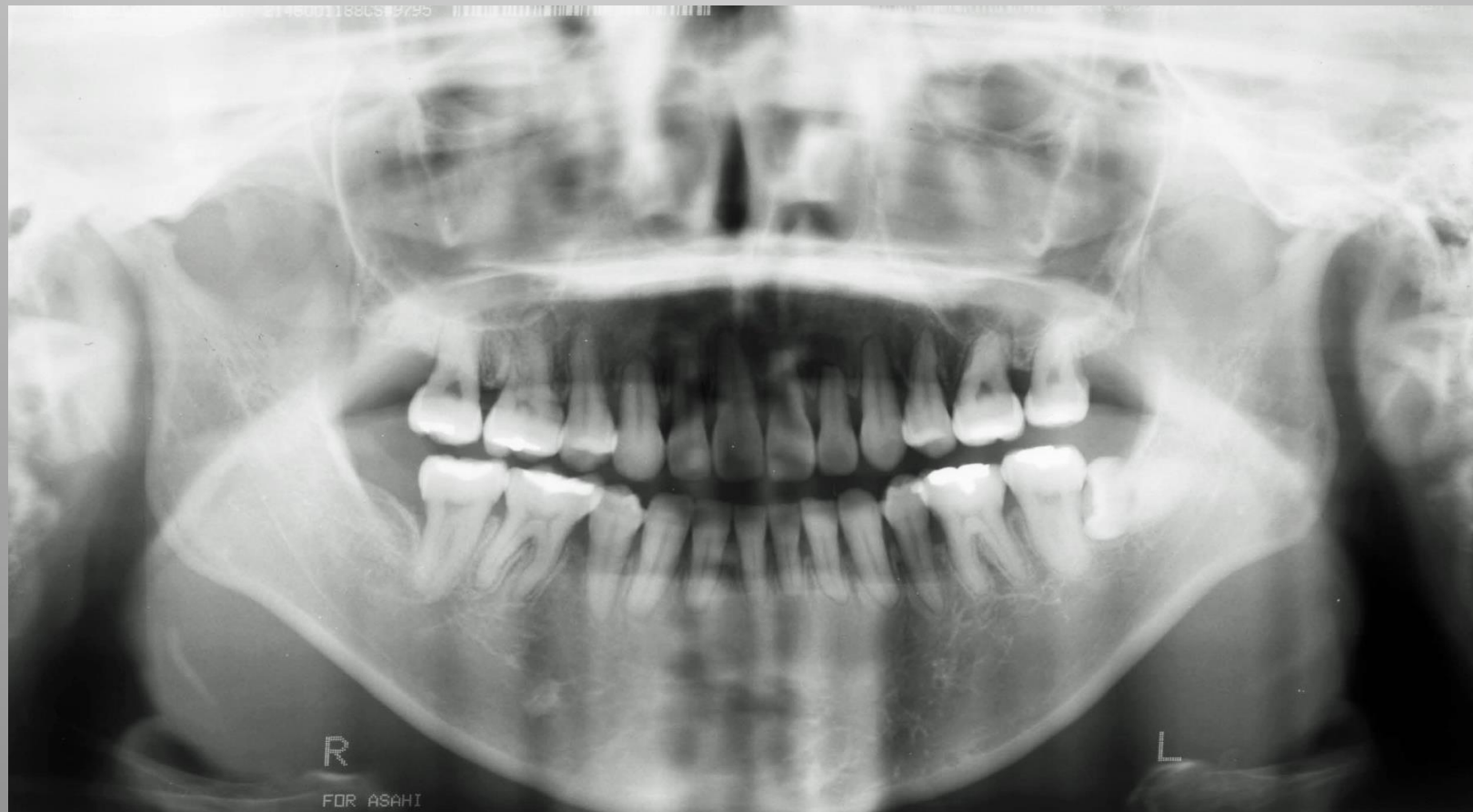FINAL

# Panorama X ray Photos

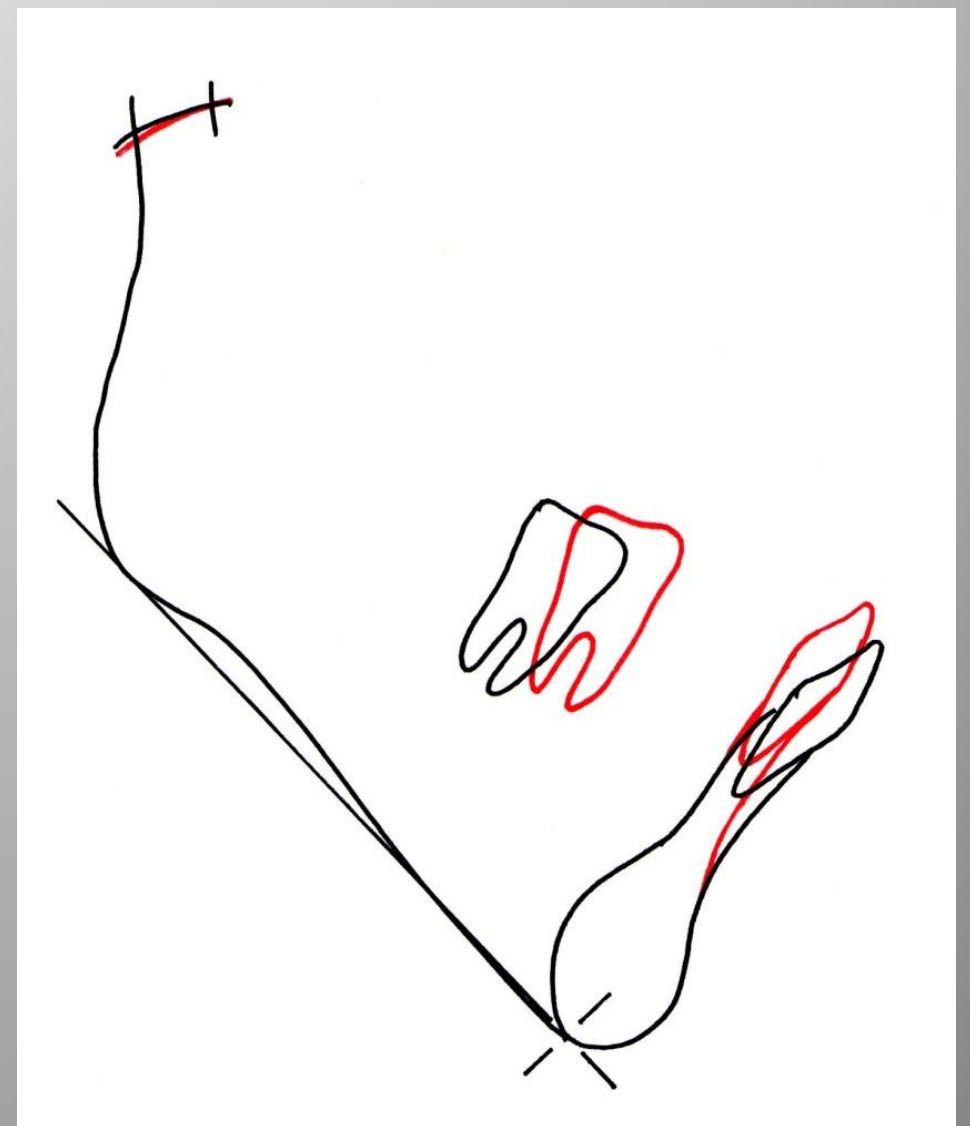
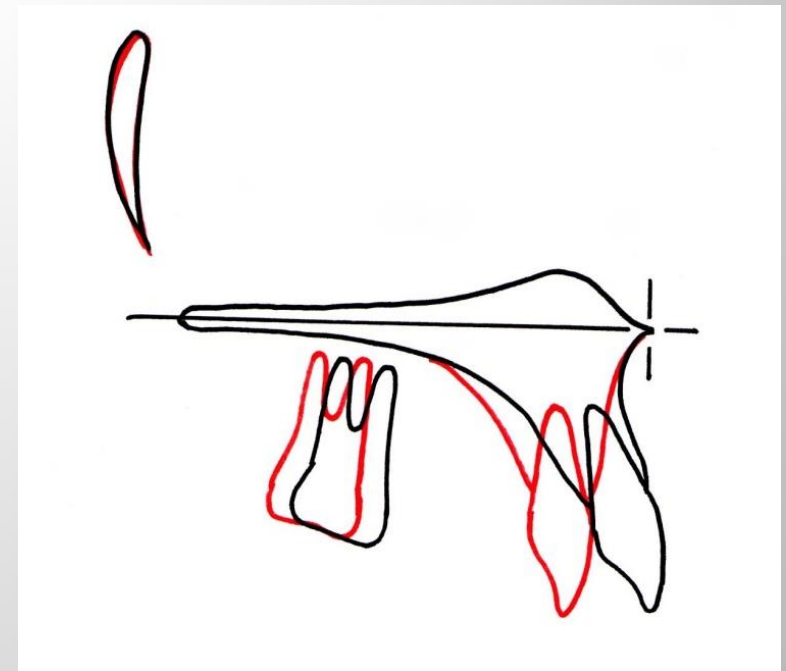
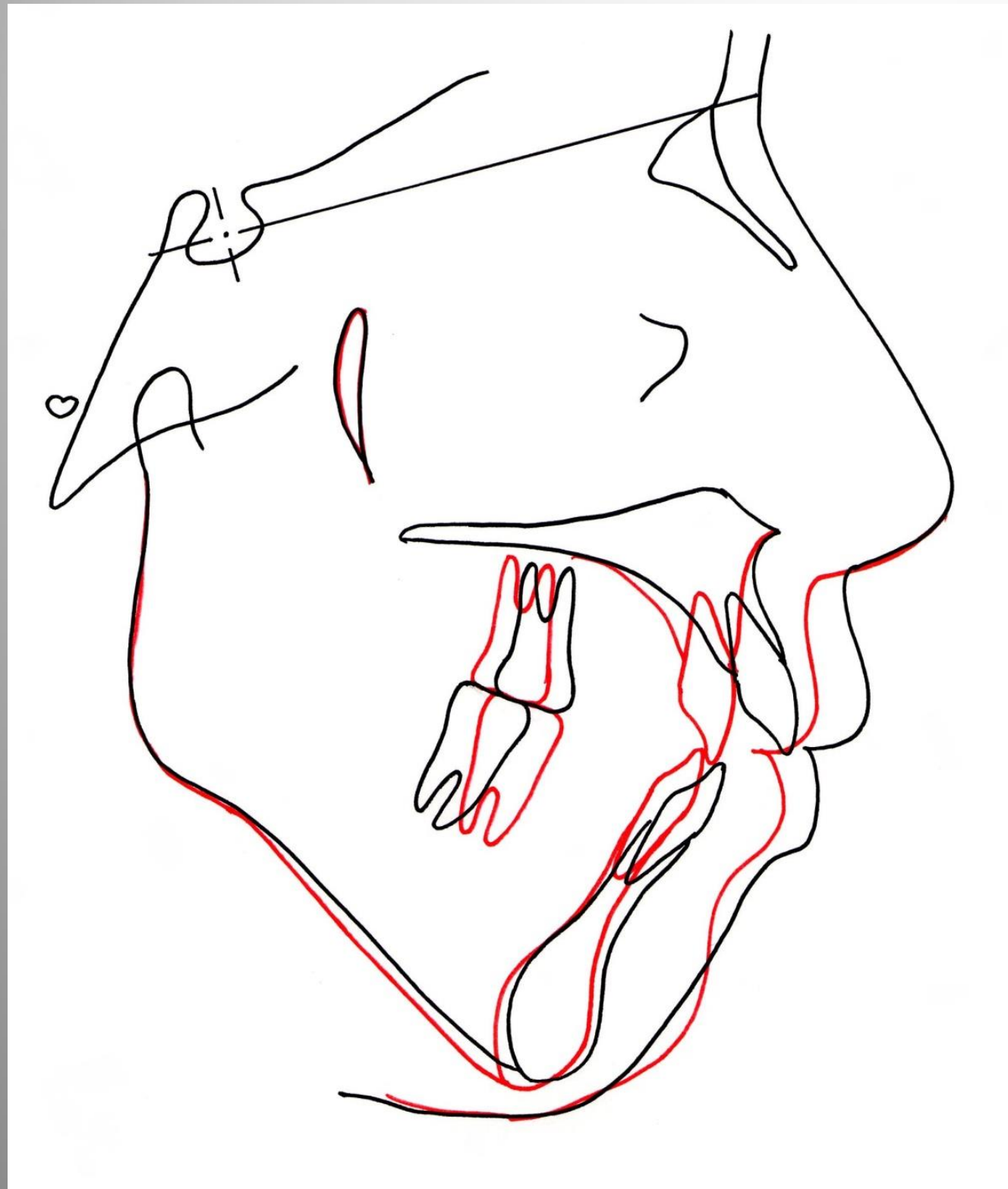
PRE-TX



FINAL







PRE-TX ———  
FINAL ———