

# Differential Diagnosis & Clinical Analysis

## Class I Bimaxillary Protrusion ( high angle)

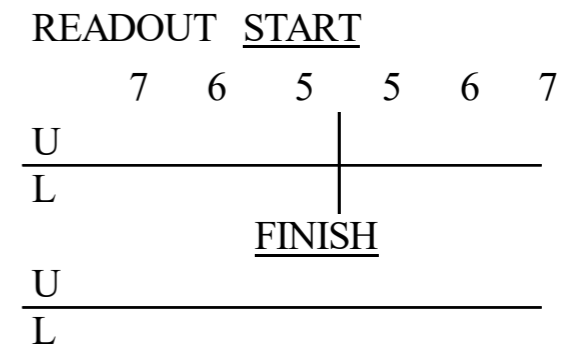
ORTHODONTISTS NAME \_\_\_\_\_ CODE :  M   
 I = TWEED COURSE INSTRUCTOR, M = TWEED MEMBER, A = APPLICANT FOR MEMMBERSHIP

### DIFFERENTIAL DIAGNOSIS AND CLINICAL ANALYSIS

PATIENT'S FIRST NAME :  M  INI  M  LAST NAME :  M

BEGIN TX. AGE  19 Y 4 M  SEX  F  BIRTHDAY  1999 / 10 / 20  TREATMENT TIME :  43 MONTHS

DATE	NORMAL	PRE-TX	PROGRESS	FINAL	POST-TX
FMIA	67	51.0		61.9	
FMA	25	31.0		31.0	
IMPA	88	98.0		87.1	
SNA	82	83.8		83.4	
SNB	80	79.2		79.0	
ANB	2	4.6		4.4	
AO-BO	2mm	0.5 mm	mm	1.0 mm	mm
OCC PLANE	10	12.6		9.4	
Z ANGLE	75	60.0		64.6	
UPPER LIP		10.0 mm	mm	13.0 mm	mm
TOTAL CHIN		8.0 mm	mm	12.0 mm	mm
POST. FACIAL HT.	45mm	45.0 mm	mm	45.5 mm	mm
ANT. FACIAL HT.	65mm	71.0 mm	mm	70.0 mm	mm
FAC. HT. INDEX	0.69	0.63		0.65	
FAC. HT. CHANGE	2:1	XXXX	/		
MAND. CUSPID WIDTH		25.5 mm	mm	28.5 mm	mm
MAND. MOLAR WIDTH		41.0 mm	mm	41.0 mm	mm



DIAGNOSIS:  
 A. Skeletal : High Angle  
                   Class           2  
 B. Dental    : Class I  
                   Bimaxillary Protrusion  
 C. Perio     : no problem  
 D. Facial    : Convex type

## CRANIAL FACIAL ANALYSIS

	Ceph. Value	Difficulty Factor	Difficulty
<b>Normal Range</b>			
FMA 22-28	<u>31.0</u>	5	<u>15</u>
ANB 1-5	<u>4.6</u>	15	<u>0</u>
Z-ANGLE 70-80	<u>60.0</u>	2	<u>20</u>
OCC. PLANE 8-12	<u>12.6</u>	3	<u>2</u>
SNB 78-82	<u>79.2</u>	5	<u>0</u>
PFH/AFH 0.65-0.75	<u>0.63</u>	3	<u>6</u>
<b>C.F. Difficulty Total</b>			<u><b>43</b></u>

E. Habits : 2  
 1. Thumb Sucker  
 2. Tongue Thrust  
 3. Bruxism

F. Joint Health : no problem

## TOTAL SPACE ANALYSIS

		Difficulty Factor	Difficulty
<b>Anterior</b>			
Tooth Arch Disc.	<u>4.3</u>	1.5	<u>6.5</u>
Headfilm Disc.	<u>12.8</u>	1	<u>12.8</u>
<b>Total</b>	<u><b>17.1</b></u>		
<b>Mid Arch</b>			
Tooth Arch Disc.	<u>3.1</u>	1.0	<u>3.1</u>
Curve of Spee	<u>2.5</u>	1.0	<u>2.5</u>
<b>Total</b>	<u><b>5.6</b></u>		
Horizontal Occlusal Disharmony (Class II or Class III)	<u>0.0</u>	2.0	<u>0.0</u>
<b>Posterior</b>			
Tooth Arch Disc.	<u>26.7</u>		
(-)expected Inc.	<u>0.0</u>		
<b>Total</b>	<u><b>26.7</b></u>	0.5	<u>13.4</u>
<b>Space Analysis Total</b>	<u><b>49.4</b></u>	<b>Space Analysis Difficulty Total</b>	<u><b>38.2</b></u>

TRERATMENT PLANNING, TIMING  
 EXTRACTIONS:

MAXILLARY

RIGHT 4 LEFT 4

MANDIBULAR

RIGHT 84 LEFT 48

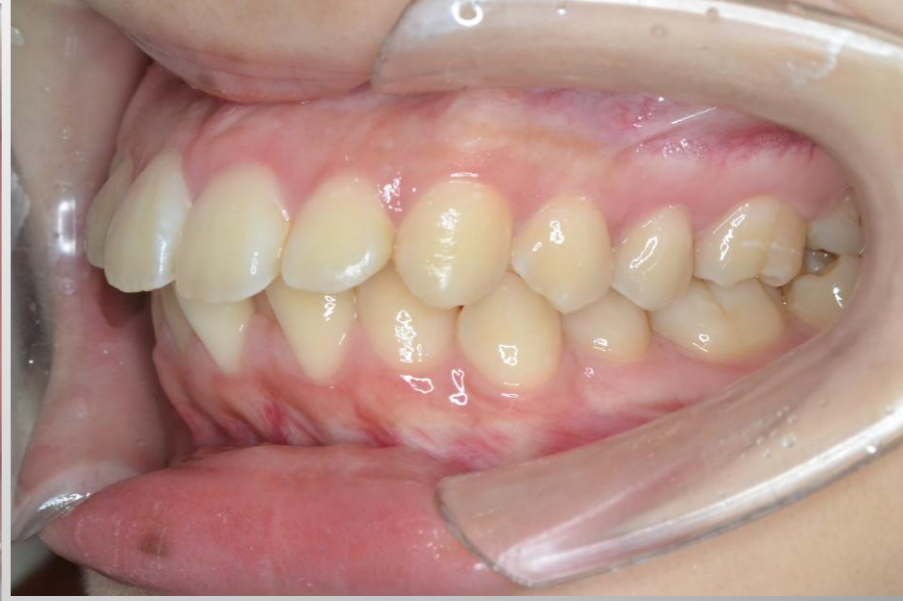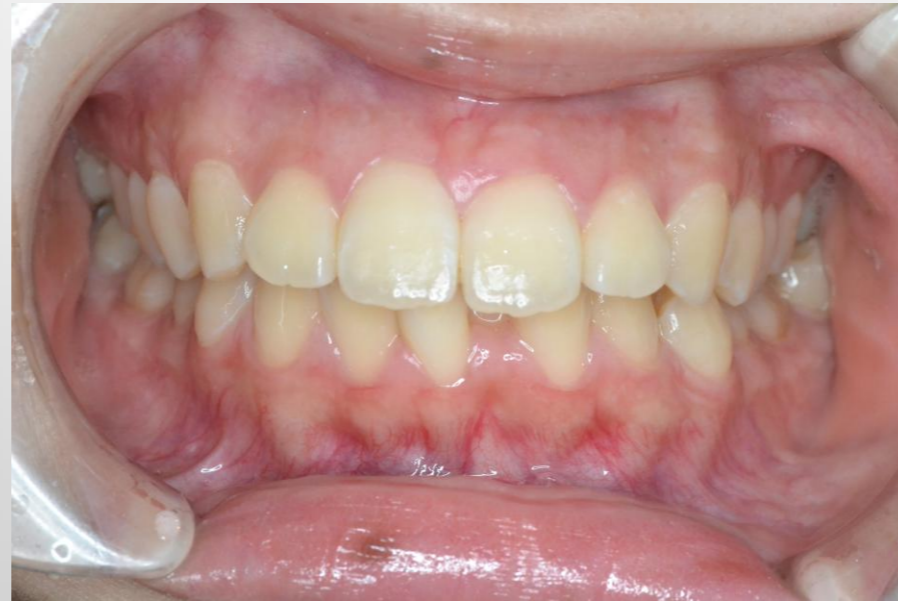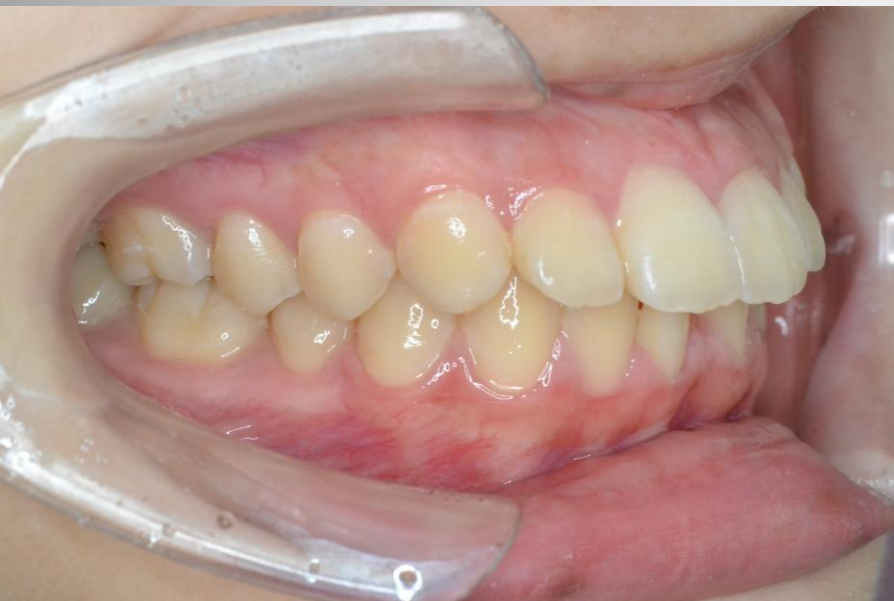( Please Indicate Missing Teeth )

### DIFFICULTY INDEX :

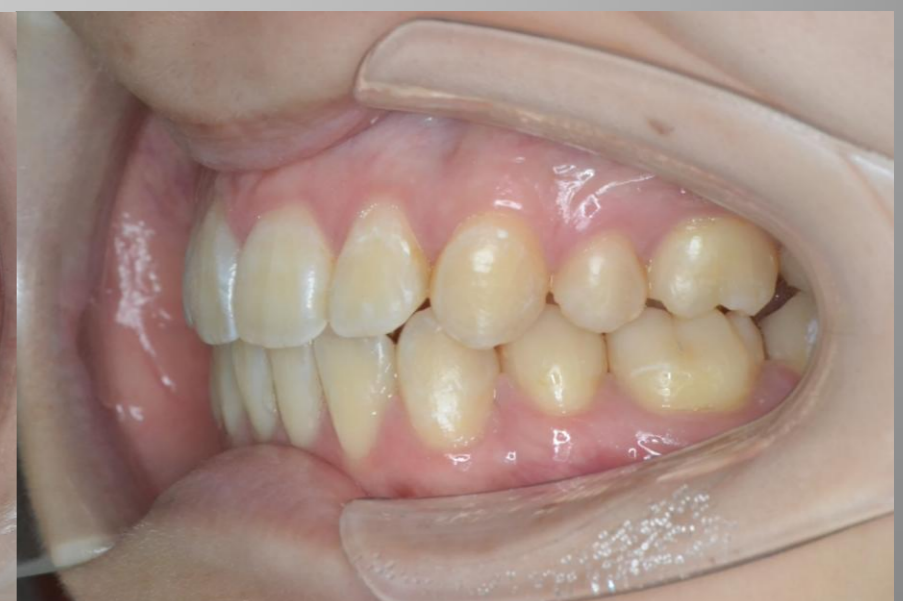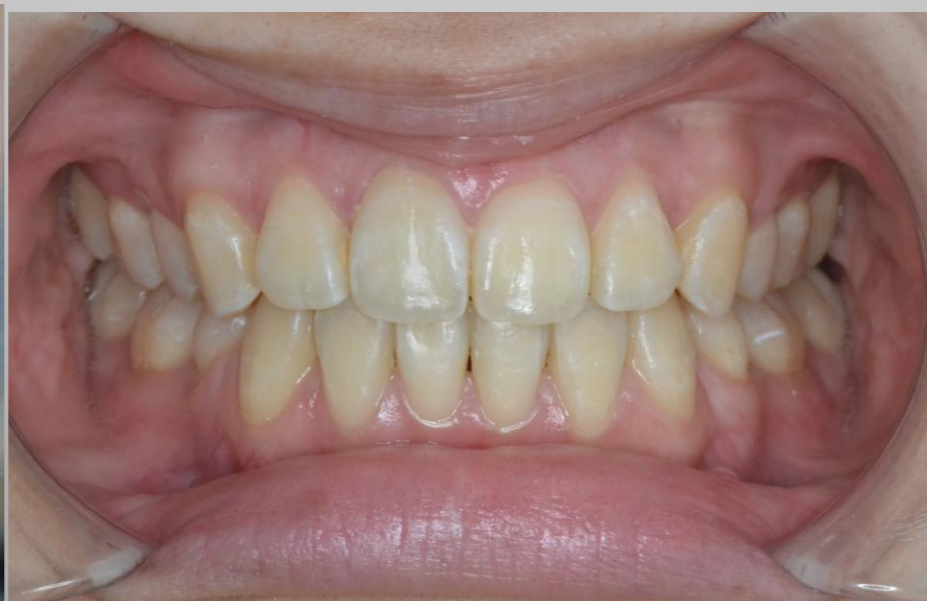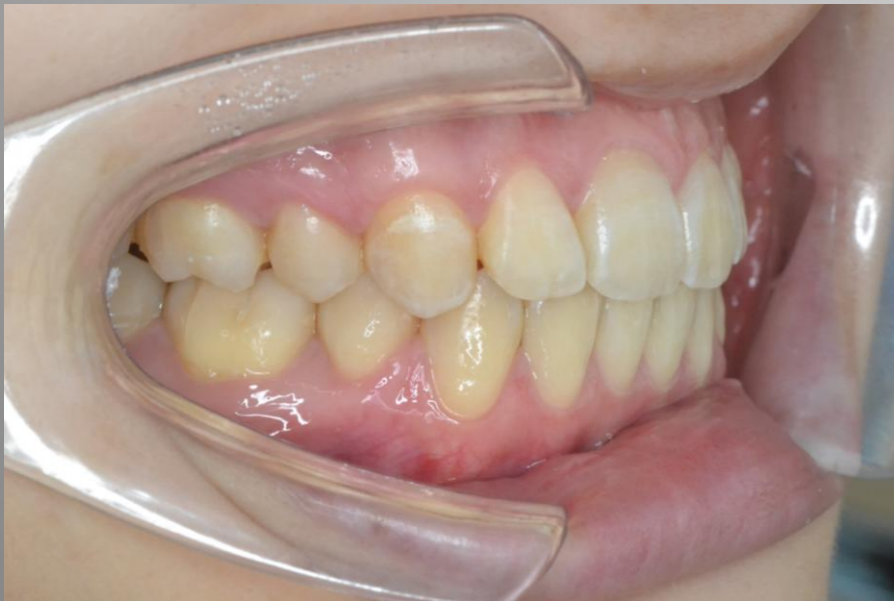Mild 0 - 60  
 Moderate 60 - 120  
 Severe over 120

**C.F. Difficulty Total** 43.0  
**Space Analysisi Difficulty Total** 38.2  
**Total Difficulty** 81.2

# Oral Photos

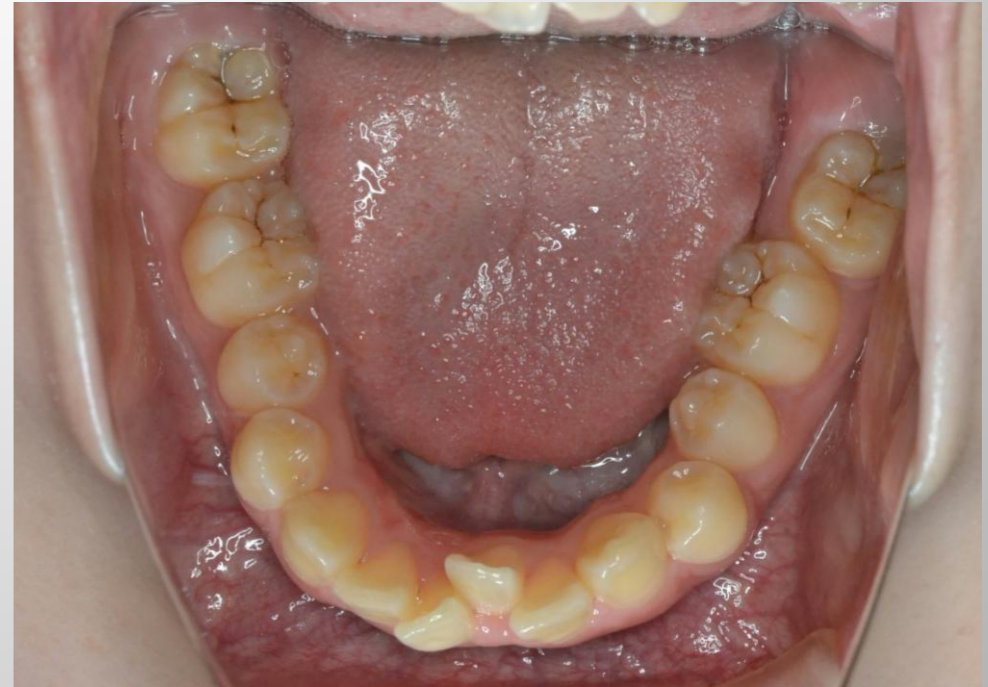
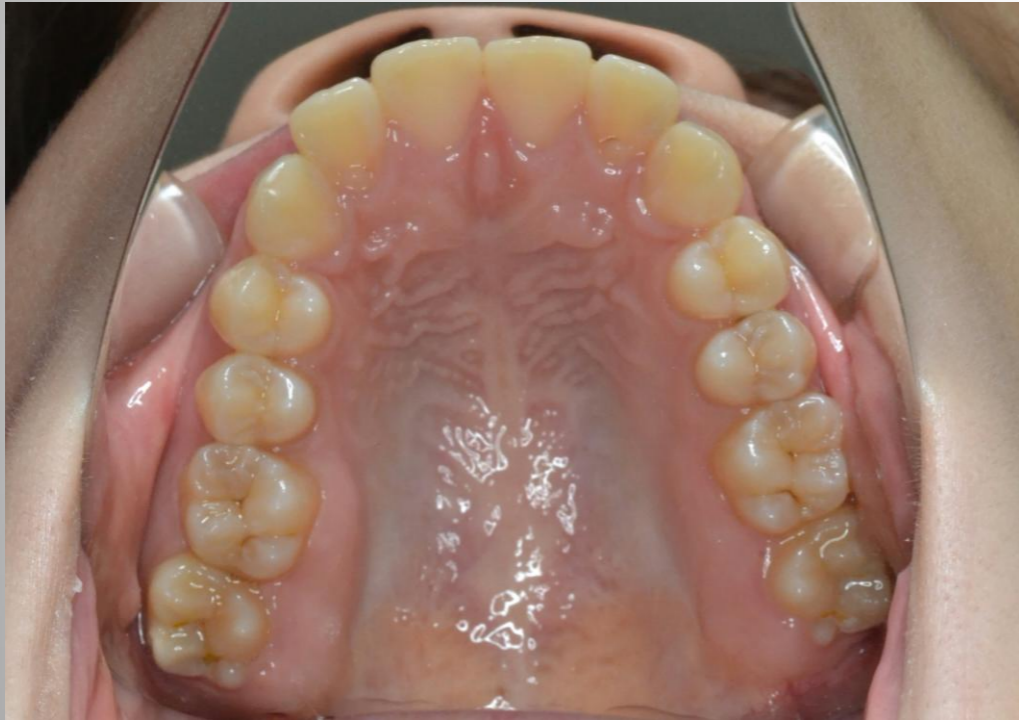
Pre Treatment

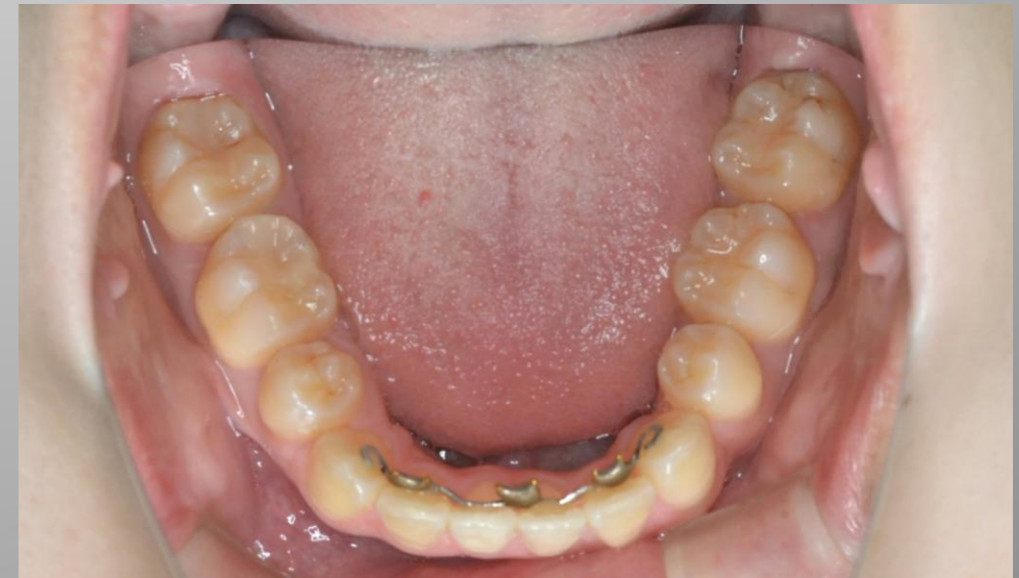
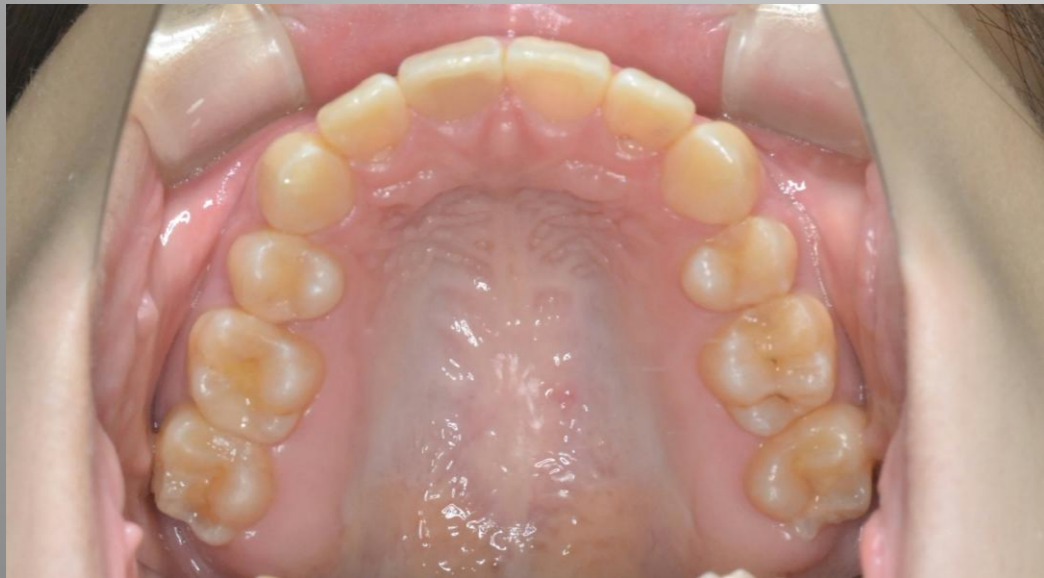
Post Treatment

# Oral Photos

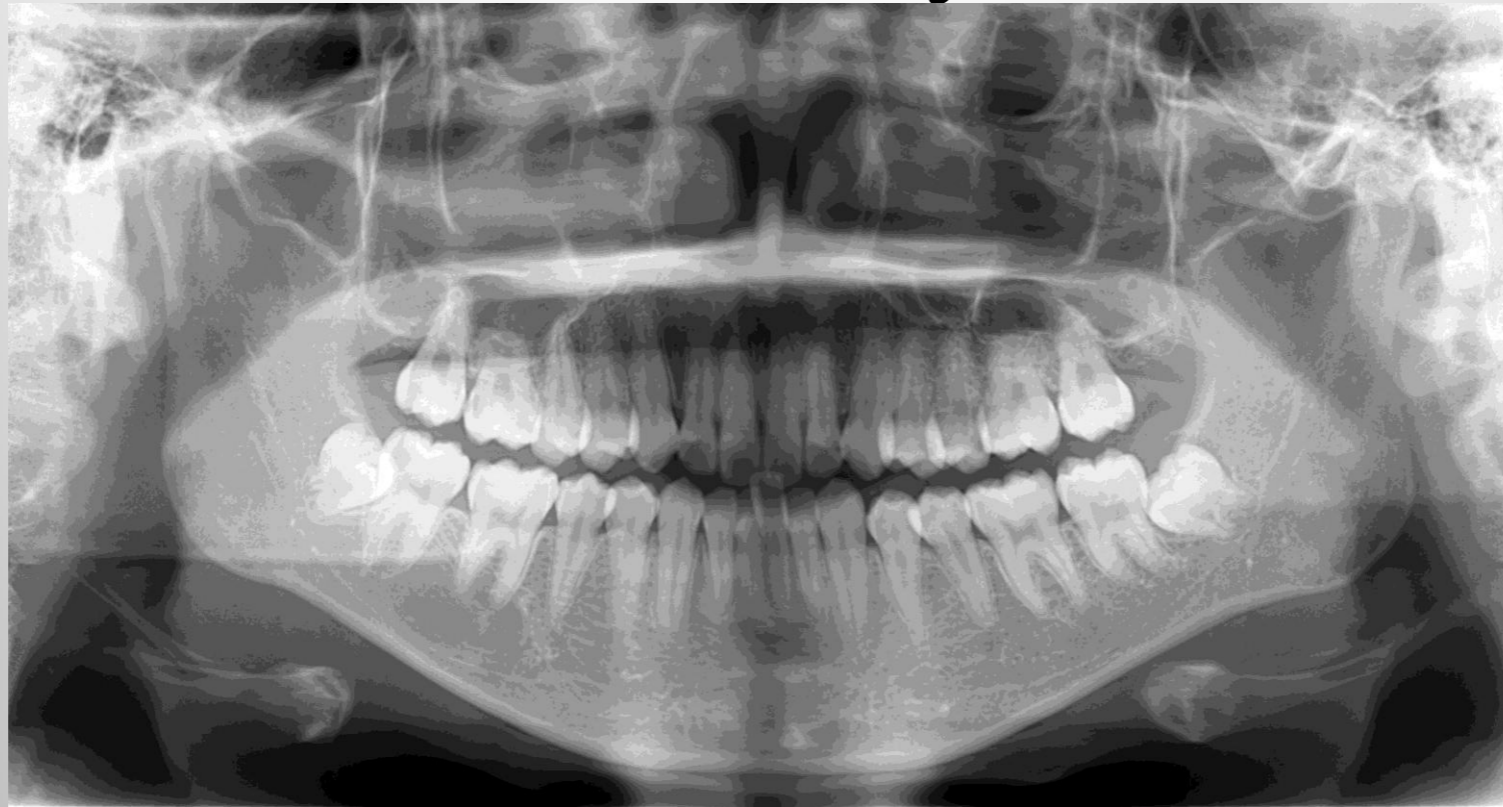

Pre Treatment

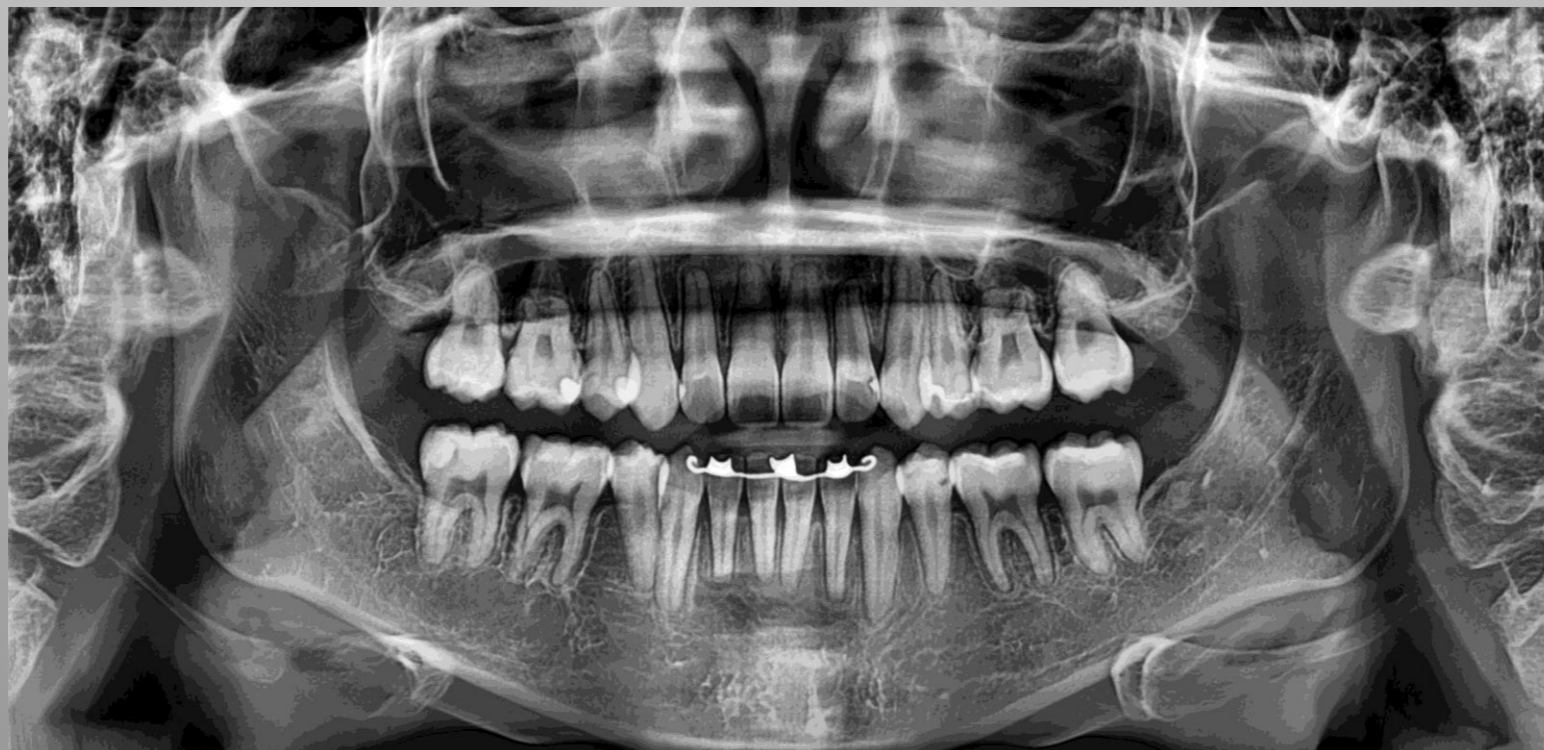

Post Treatment

# Panorama X ray Photos

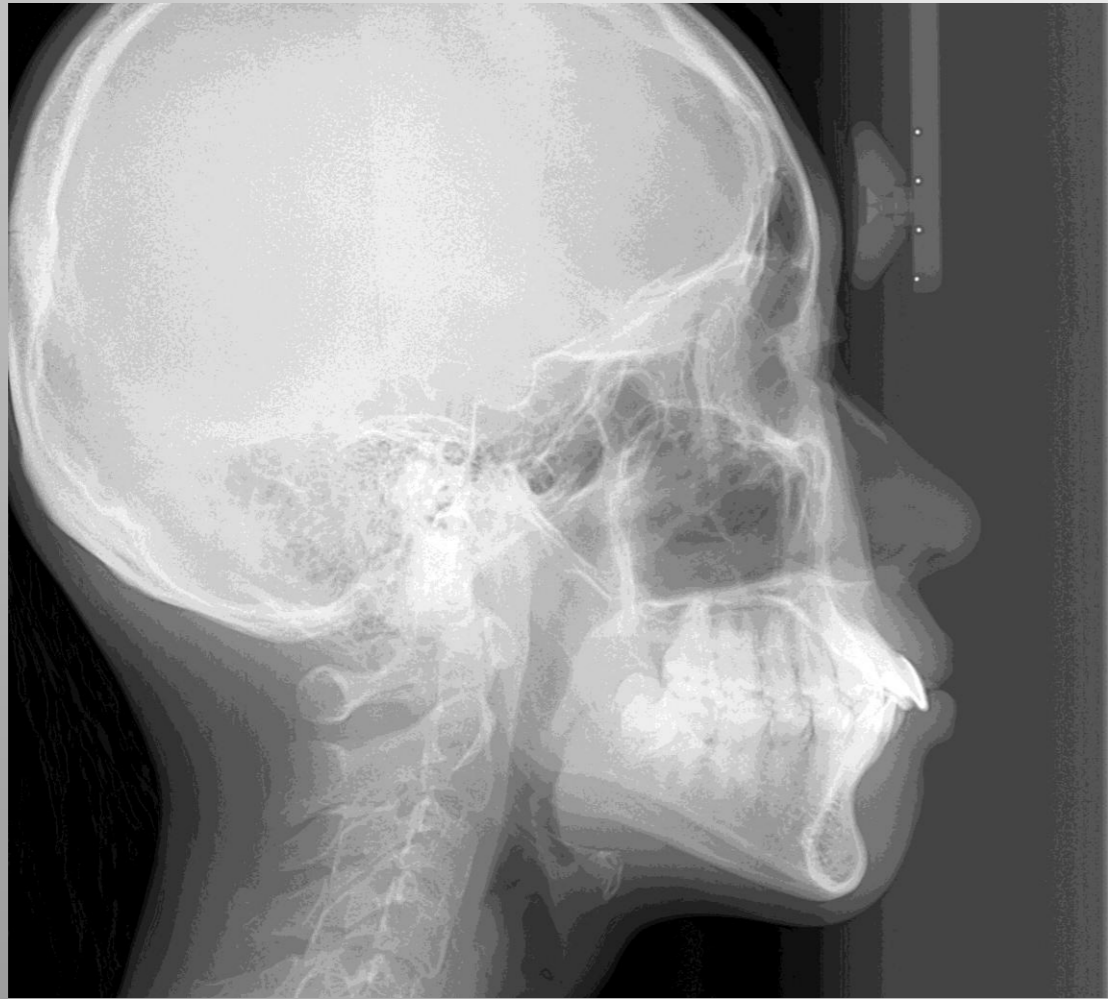

Pre Treatment

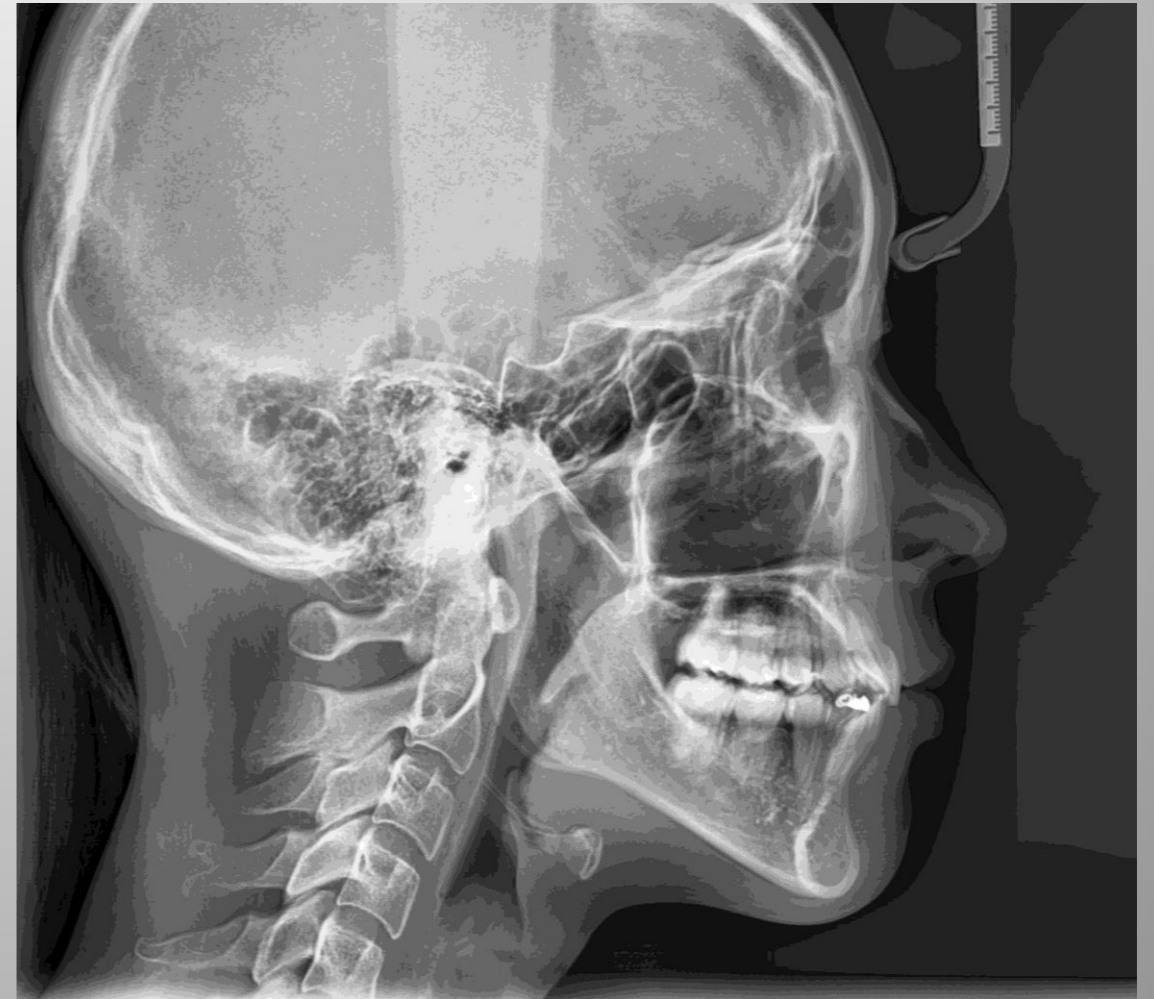

Post Treatment

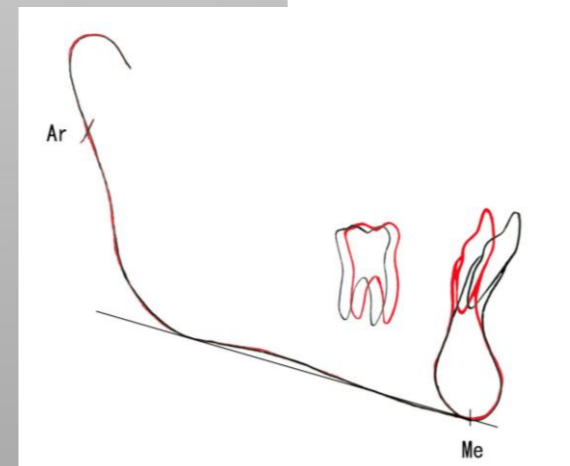
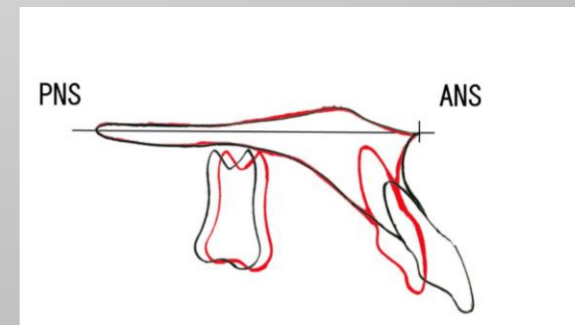
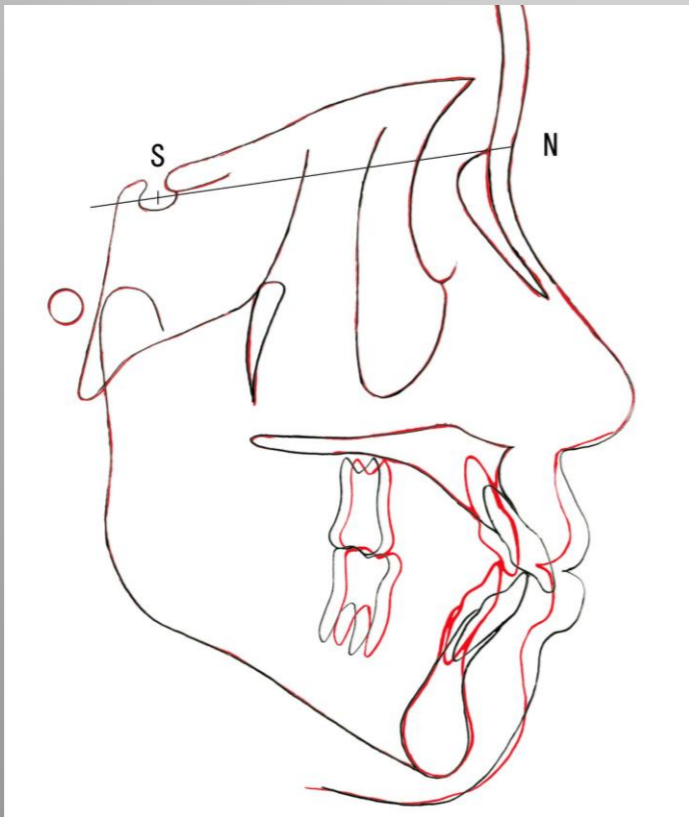
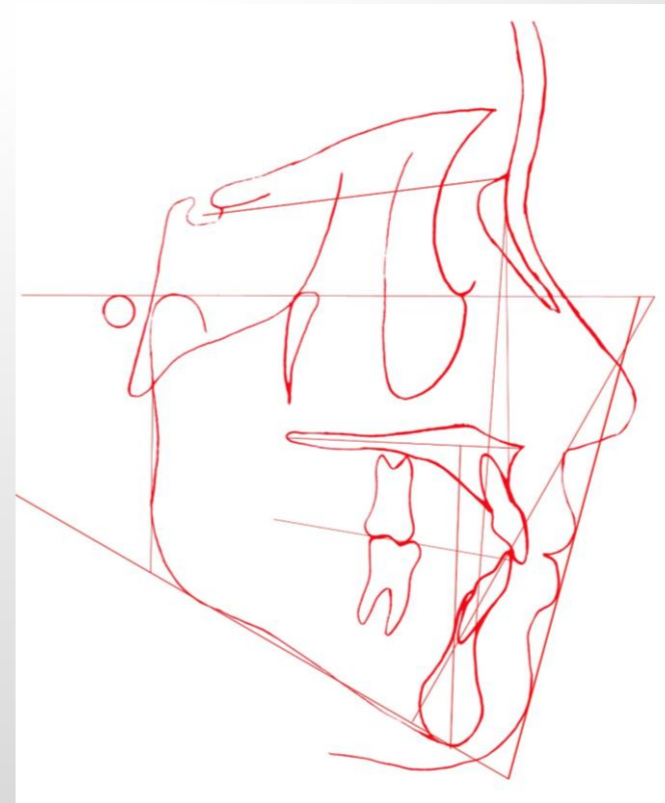
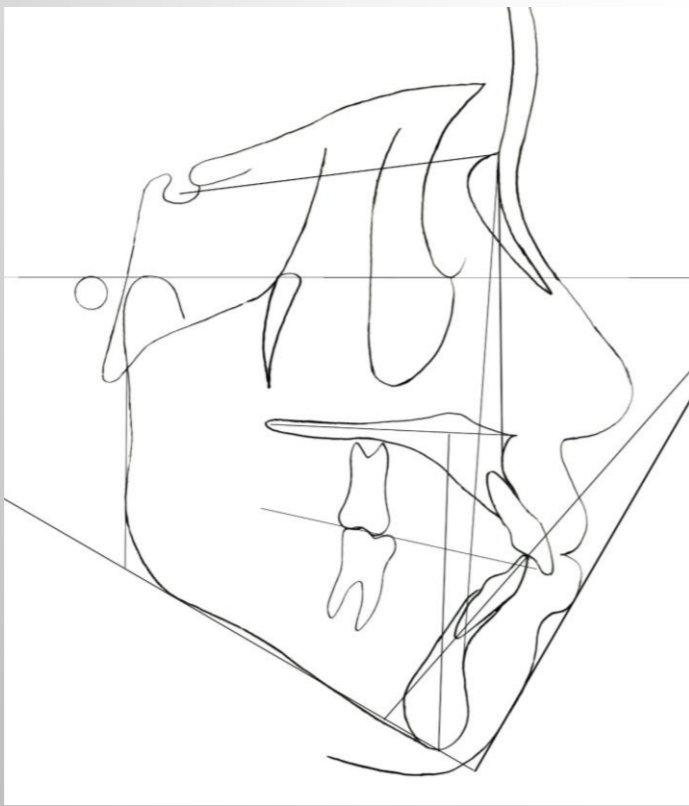
# Cephalo X ray Photos



Pre Treatment



Post Treatment



Pre-treatment ———  
Post-treatment ———