Differential Diagnosis & Clinical Analysis

Angle class II bimaxillary protrusion

ORTHODONTIST'S NAME _____ CODE : I

I = TWEED COURSE INSTRUCTOR, M = TWEED MEMBER, A = APPLICANT FOR MEMMBERSHIP

DIFFERENTIAL DIAGNOSIS AND CLINICAL ANALYSIS

PATIENT'S FIRST NAME : _____ INI ___ LAST NAME : _____

BEGIN TX. AGE 14 Y 5 M SEX F BIRTHDAY May 5, 1988 TREATMENT TIME : 22 MONTHS

DATE										
	NORMAL		PRE-TX		PROGRESS		FINAL		POST-TX	
FMIA	67		46.0				61.5		61.5	
FMA	25		33.0				32.0		31.5	
IMPA	88		101.0		180.0		86.5		87.0	
SNA	82		85.5				84.0		84.5	
SNB	80		78.0				79.0		79.5	
ANB	2		7.5		0.0		5.0		5.0	
AO-BO	2mm		1.5	mm		mm	-1.0	mm	-0.5	mm
OCC PLANE	10		12.0				11.0		11.5	
Z ANGLE	75		66.0				70.0		69.0	
UPPER LIP			12.5	mm		mm	15.0	mm	14.0	mm
TOTAL CHIN			13.5	mm		mm	15.0	mm	16.0	mm
POST. FACIAL HT.	45mm		48.0	mm		mm	47.0	mm	48.0	mm
ANT. FACIAL HT.	65mm		68.5	mm		mm	69.0	mm	70.0	mm
FAC. HT. INDEX	0.69		0.70		####		0.68		0.69	
FAC. HT. CHANGE	2:1		XXXX		/		/		/	
MAND. CUSPID WIDTH			26.0	mm		mm	27.0	mm	27.0	mm
MAND. MOLAR WIDTH			47.5	mm		mm	46.0	mm	46.0	mm

READOUT START

7 6 5 5 6 7

U

L

FINISH

U

L

DIAGNOSIS:

A. Skeletal : class II

B. Dental : Angle class I

C. Perio : Non problem

D. Facial : Bimax Protrution

Japanese Tweed Orthodontic Association

CRANIAL FACIAL ANALYSIS

Normal Range	Ceph. Value	Difficulty Factor	Difficulty
FMA 22-28	33.0	5	25
ANB 1-5	7.5	15	38
Z-ANGLE 70-80	66.0	2	8
OCC. PLANE 8-12	12.0	3	0
SNB 78-82	78.0	5	0
PFH/AFH **0.65-0.75**	0.70	3	0
	C.F. Difficulty Total		71

E. Habits :
1. Thumb Sucker
2. Tongue Thrust
3. Bruxism

F. Joint Health :

TOTAL SPACE ANALYSIS

		Difficulty Factor	Difficulty
Anterior			
Tooth Arch Disc.	1.5	1.5	2.3
Headfilm Disc.	15.2	1	15.2
Total	16.7		
Mid Arch			
Tooth Arch Disc.	0.0	1.0	0.0
Curve of Spee	2.5	1.0	2.5
Total	2.5		
Horizontal Occlusal Disharmony			
(Class Ⅱ or Class Ⅲ	0.0	2.0	0.0
Posterior			
Tooth Arch Disc.	21.0		
(-)expected Inc.	0.0		
Total	21.0	0.5	10.5
Space Analysis Total	40.2	**Space Analysis Difficulty Total**	30.5

TRERATMENT PLANNING, TIMING
EXTRACTIONS:
MAXILLARY
RIGHT 4 LEFT 4
MANDIBULAR
RIGHT 84 LEFT 48
(Please Indicate Missing Teeth)

C.F. Difficulty Total	70.5
Space Analysisi Difficulty Total	30.5
Total Difficulty	101.0

DIFFICULTY INDEX :

Mild	0 - 60
Moderate	60 - 120
Severe	over 120

Oral Photos

Pre Treatment

Post Treatment

Oral Photos

Pre Treatment

Post Treatment

Panorama X ray Photos

Pre Treatment

Post Treatment

Japanese Tweed Orthodontic Association

Cephalo X ray Photos

Pre Treatment

Post Treatment

Japanese Tweed Orthodontic Association

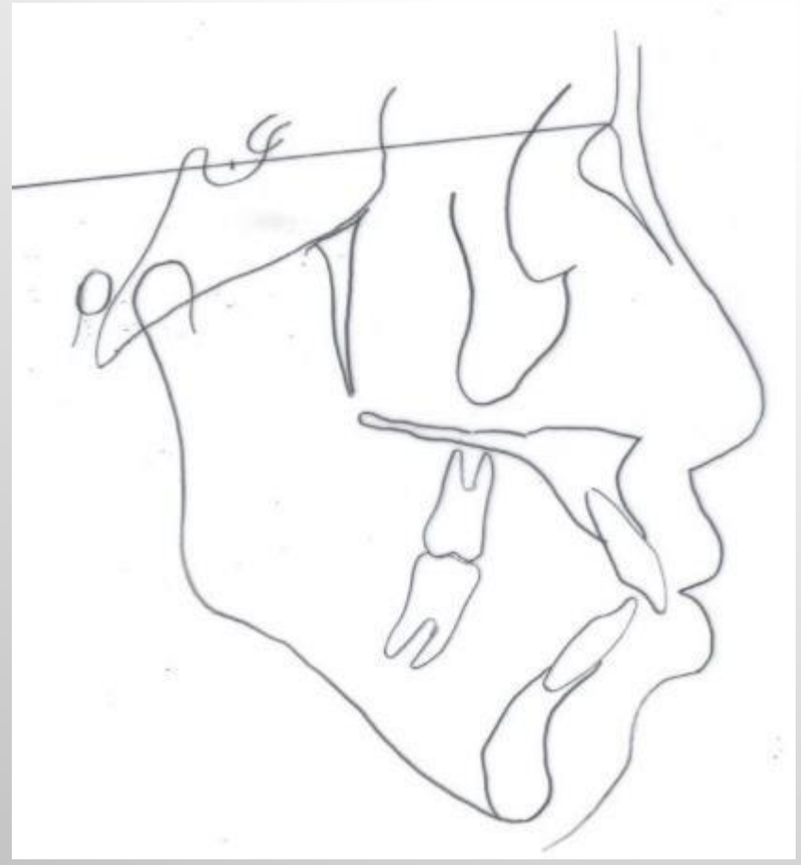

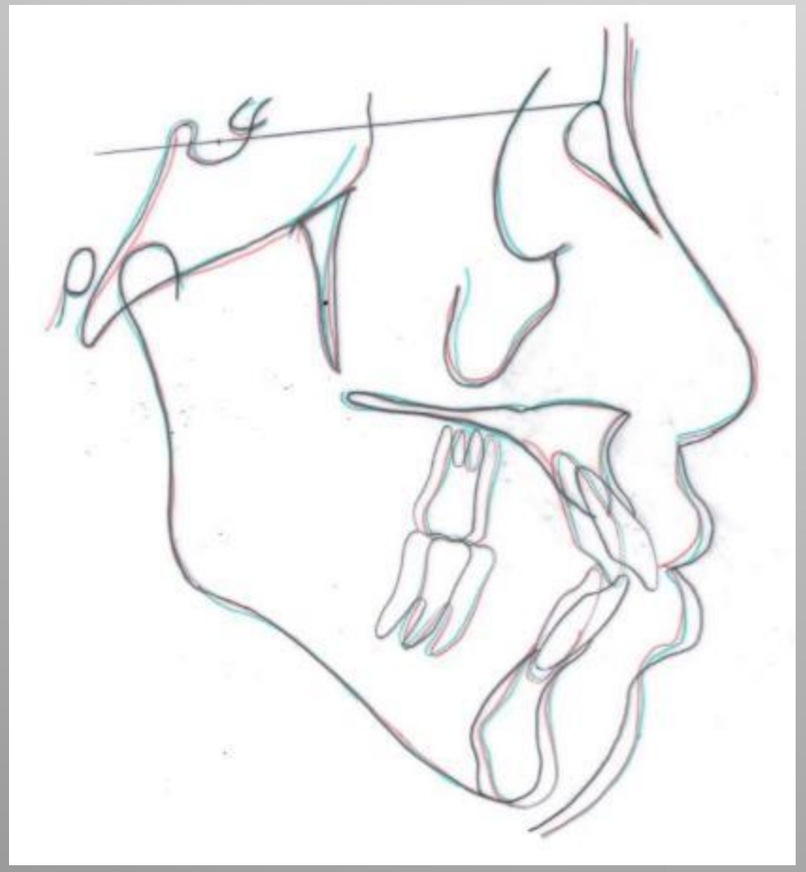

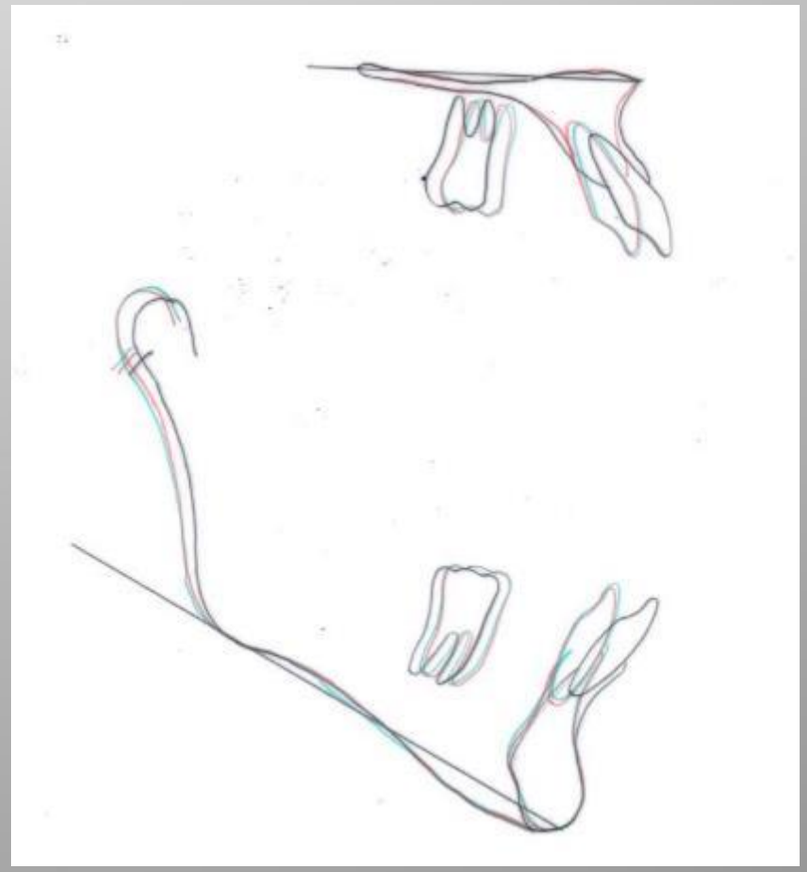

Pre-treatment

Post-treatment

Japanese Tweed Orthodontic Association